



## Original Research Article

## A study of morphometric analysis of distal end of femur and its clinical importance

VINAY G<sup>1</sup>, Vikram S<sup>2,\*</sup><sup>1</sup>Dept. of Anatomy, Mamata Medical College, Khammam, 507002, Telangana, India<sup>2</sup>Dept. of Anatomy, A.J. Institute of Medical Sciences, Mangalore, Karnataka, India

## ARTICLE INFO

## Article history:

Received 19-12-2019

Accepted 07-01-2020

Available online 24-01-2020

## Keywords:

Morphometry  
Distal end of Femur  
Knee prosthesis  
Intercondylar notch  
Bicondylar width

## ABSTRACT

**Introduction:** Femur is an important component of the lower kinetic series and functions as a weight-bearing bone. The distal end of femur's morphometry is vital in the designing the implants for total joint arthroplasty. The design of prosthesis is based on morphometry of the distal end of the femur. To ensure the early mobility as well as fewer complications after total knee arthroplasty, the designing of prosthesis based on morphometric values of distal end of femur plays a key role.

**Objectives:** To study the morphometric data of the distal end of femur. To compare the morphometric data between right and left femur.

**Materials and Methods:** One hundred and eighty femurs of unidentified sex were measured for the width of Bicondylar, the maximum medial and lateral condyle anteroposterior length, the total transverse distance of the medial and lateral condyle, and the width of intercondylar notch.

**Results:** The average bicondylar width of entire femur sample was  $71.32 \pm 5.91$  mm, mean anteroposterior diameter of medial and lateral condyle were  $56.12 \pm 4.51$  mm and  $56.85 \pm 4.31$  mm respectively. The medial and lateral condyle mean transverse distance of was  $28.33 \pm 3.49$  mm and  $30.73 \pm 3.21$  mm respectively. It was found that the mean intercondylar notch width was  $21.62 \pm 2.92$  mm. In this study, there were no statistically significant parameters between right and left femur.

**Conclusion:** The data obtained from this study will help the biomedical engineers to design the knee replacement prosthesis of suitable size for Indian patients undergoing knee replacement operations.

© 2019 Published by Innovative Publication. This is an open access article under the CC BY-NC-ND license (<https://creativecommons.org/licenses/by/4.0/>)

## 1. Introduction

The femur is the thigh's only bone and the body's longest and strongest bone. Femur osteological characteristics include femoral head, neck, proximal trochanters, femoral shaft, and distal femoral condyles. Femur's distal end consisting of lateral and medial condyles. Projecting from each condyle is an epicondyle which gives attachment for the collateral ligaments of knee joint. The intercondylar notch separates the lateral and medial condyles.<sup>1</sup> The femur's sturdy form offers attachment to many hip and knee muscles that lead to walking and other propulsive movements.

Because of its location, structure and function, the femur is subjected to multiple traumatic, degenerative and neoplastic processes. The femur's distal end is broader and more extensive. It has a broad two condyles bearing partly articular surface for weight transmission to the tibia. The condyles are confluent anteriorly and continue with the shaft, subsequently posterior they are separated by a deep intercondylar fossa and extend beyond the plane of popliteal surface. The articular surface for the patella and the tibia is a wide area, like an inverted U.<sup>2</sup>

The knee joint is a complex synovial joint made up of tibiofemoral and patellofemoral articulations. The fairly incongruous design of the joint surfaces inevitably makes the knee joint unstable. One of the main structures responsible for human locomotion is the knee joint, and the most common joint to suffer from trauma & osteoarthritis.

\* Corresponding author.

E-mail address: [vk1karade@gmail.com](mailto:vk1karade@gmail.com) (Vikram S).

Knee joint replacement surgery is an upcoming treatment of choice for degenerative bone ailments requiring correct positioning of well-fitted distal femoral implants and sufficient soft tissue support.<sup>3</sup>

Because of the erect position, the plane of the femoral condyles is considered to be horizontal to the surface in normal locomotion.<sup>4</sup> The distal femur's computable anatomy is critical for the development of complete joint replacement and internal fixation content.<sup>5</sup> Successful joint replacement surgery relies on correct implant positioning and proper alignment of the surrounding soft tissue. It is important to use the correct femoral component to preserve the knee's usual functional movement range.<sup>6,7</sup>

Total knee arthroplasty is an exceedingly complex and precise operation aimed at alleviating pain and improving function. To attain this, selecting a prosthesis that best fits the sizes of the resected surfaces of distal femur and proximal tibia is important. Any malfunction can lead to several difficulties, including soft tissue imbalance, impaired mobility, and implant loosening.<sup>8,9</sup>

The presently available prosthetic components was designed primarily based on the western population. Numerous studies have shown that Asian ethnicities have smaller knees succeeding their shorter physiques.<sup>10–12</sup> So there is a need to change the design of existing prostheses to meet local Indian population requirements. This research on distal end of femur anthropometry is therefore suitable with a growing trend in full knee arthroplasty as a treatment of choice for degenerative knee ailments. The purpose of this study was to analyse the morphometric parameters of the distal end of the femur that may aid in the design of femoral element prosthesis for total knee arthroplasty.

## 2. Materials and Methods

An observational, descriptive study collecting cross-sectional data on 180 dry adult femora belonging to the skeletal collection of private medical colleges in Telangana. Of the 180 femur, 81 belongs to the right side and 99 belongs to the left side.

### 2.1. Inclusion criteria

Dried, intact and non-pathological femurs were included.

### 2.2. Exclusion criteria

Femur with any fracture, un-ossified or pathological abnormalities like tumours, deformities were excluded from this study.

After obtaining Institutional Ethics committee clearance, following parameters were taken with the help of Vernier calliper.

**Bicondylar width (BCW):** Total length in transverse plane between medial and lateral epicondyles. (Figure 1)



Fig. 1: Measurement of Bicondylar width using Vernier calliper

**Maximum anteroposterior length of medial femoral condyle (MC AP):** Maximum distance between anterior and posterior surface of medial condyle.

**Maximum anteroposterior distance of lateral femoral condyle (LCAP):** Maximum distance in lateral condyle between anterior and posterior surface. Distance between point A & B in Figure 2.

**Maximum transverse distance of medial femoral condyle (MCT):** Maximum distance between medial and lateral surface of medial condyle.

**Total transverse distance of lateral femoral condyle (LCT):** Total distance between medial and lateral surface of lateral condyle.

**Intercondylar notch width (ICNW):** Maximum distance between medial and lateral surface of intercondylar notch posteriorly. Distance between point C & D in Figure 2.

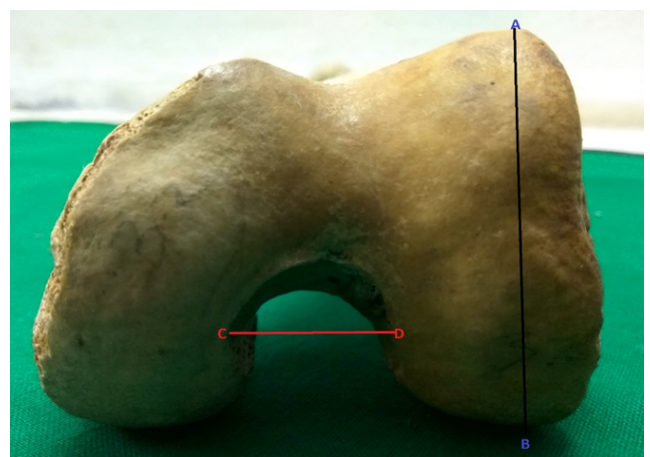


Fig. 2: AB = Maximum AP distance of lateral condyle; CD = Intercondylar notch width

All the measurements for right and left femur were recorded separately. The data was recorded in MS

Excel sheet and analysed using SPSS software v 20 for mean  $\pm$ SD. Independent t-test was used to calculate the differences in the parameters of right and left femur. The p-value  $<0.05$  was considered statistically significant.

### 3. Results

Out of 180 bones, 81 femur belongs to right side and 99 femur to the left side. Average bicondylar width was  $71.8 \pm 5.91$  mm on right side and  $70.8 \pm 5.95$  mm on left side. Mean anteroposterior distance for medial condyle was  $56.3 \pm 4.73$  mm on the right side and  $55.7 \pm 4.38$  mm on the left side. Mean transverse distance for medial condyle was  $28.6 \pm 3.83$  mm on the right side and  $28.1 \pm 3.07$  mm on the left side. Mean intercondylar notch width was  $21.5 \pm 3.01$  mm on the right side and  $21.7 \pm 2.85$  mm on the left side. The remaining details of the morphometric data from distal end of femur are presented in Table 1. Morphometric parameters of right and left femurs did not show any statically significant difference between each other.

### 4. Discussion

The stability of knee joint is determined by the morphology of femoral condyles and intercondylar notch. In the treatment of knee joint degenerative diseases, knee joint arthroplasty has become popular. The proper use of morphometrical matched prosthesis is the key to success for knee arthroplasty.<sup>3</sup> It is therefore very important to have knowledge of reliable morphometric data for designing and selection of implant size. Morphometric data were calculated using Vernier calliper by direct observation. In this study, the mean values for the right and the left femora were found to be similar. Although the right femora showed somewhat larger values than the left femora, but they were not significantly significant.

In our study the average bicondylar width of total specimens found to be  $71.32 \pm 5.91$  mm, where as it was  $71.8 \pm 5.91$  mm on right side and  $70.8 \pm 5.95$  mm on left side. Similar results were obtained in Bengali population studied by Biswas et al.,<sup>13</sup> where average bicondylar width was  $71.71 \pm 4.5$  on right side and on left side it was  $70.7 \pm 5.25$ . The values in the study conducted by Mistri et al.,<sup>3</sup> Ravichandran et al.,<sup>14</sup> and Shweta et al.,<sup>15</sup> found to be slightly higher than our study. Similarly studies done in abroad like Terzidis et al.<sup>5</sup> and Taner et al.<sup>16</sup> found to be having higher values than our study. In this study similar to other studies there was no statistically significant difference between right and left sides for bicondylar width.

In our study the mean anteroposterior distance of medial condyle was found to be  $56.3 \pm 4.73$  mm on the right side and  $55.7 \pm 4.38$  mm on left side which was slightly higher than studies by Biswas et al.<sup>13</sup> and Hiren et al.<sup>17</sup> Studies conducted by Terzidis et al.<sup>5</sup> in Greek populations showed

higher values than our study.

In this study the average anteroposterior distance of lateral condyle was  $56.6 \pm 4.4$  mm on right side and  $56.9 \pm 4.26$  on left side, almost same results were found by Biswas et al.,<sup>13</sup> and Hiren et al.,<sup>17</sup> but slightly lesser than studies conducted by Terzidis et al.<sup>5</sup> on Greek population. In our study there was no statistically significant difference was seen between right and left sides for anteroposterior distance of medial and lateral condyle.

The mean transverse distance of medial condyle on right side was  $28.6 \pm 3.83$  mm and  $28.1 \pm 3.07$  mm on left side, similar values obtained by Biswas et al.<sup>13</sup> and Hiren et al.<sup>17</sup> Average lateral condyle transverse diameter was  $31.1 \pm 3.02$  on right side and  $30.5 \pm 3.21$  on left side, which was slightly higher than Biswas et al.<sup>13</sup> The mean values of transverse diameter of medial and lateral condyle didn't show any statistical significant difference.

Narrowing of the intercondylar notch is called as "intercondylar notch stenosis". Few authors noted an association between narrowing intercondylar notch with increased risk of anterior cruciate ligament tear.<sup>18</sup> The mean intercondylar notch width on right side was  $21.5 \pm 3.01$  mm and on left side was  $21.7 \pm 2.85$  mm which was slightly higher than Mistri et al.,<sup>3</sup> Ravichandran et al.,<sup>14</sup> and Hiren et al.<sup>17</sup> The mean intercondylar notch width on both sides didn't show any significant statistical difference. Different ethnicities have different measurements due to change in environmental factors, lifestyle, hereditary factors etc., which may affect the built, stature and composition of human body.

### 5. Conclusion

The distal end of femur anthropometric data collected by direct measuring system. The values obtained indicate that there are ethnic variances between different populations. This morphometric data of the lower end of the femur can therefore aid in the design of implants suitable for the Indian population, especially for the Telangana region. The morphometry data of this study could provide of importance to the orthopedicians in the prevention and management of knee injuries. Selection of appropriate implant according to different ethnic specifications will minimize mismatch and will increase clinical outcome. Knowledge from this study may help the surgeons in inserting the intramedullary nails, plates, screws and pins by avoiding injury to ligaments, blood vessels, nerves and joints.

### 6. Source of Funding

None.

### 7. Conflict of Interest

None.

**Table 1:** Showing the range mean and standard deviation for different parameters on right and left femurs.

Parameter	Right			Left			P value
	Range	Mean	S.D	Range	Mean	S.D	
BCW	58.6 – 84.8	71.8	5.91	54.4 – 83.8	70.8	5.95	0.649
MC AP	47.2 – 68.1	56.3	4.73	45.2 – 65.8	55.7	4.38	0.721
LC AP	46.8 – 67.4	56.6	4.4	46.1 – 66.9	56.9	4.26	0.322
MC T	23.4 – 41.3	28.6	3.83	22.2 – 38.2	28.1	3.07	0.253
LC T	23.2 – 37.8	31.1	3.02	22.6 – 37.5	30.5	3.21	0.132
ICN W	11.8 – 29.1	21.5	3.01	10.9 – 28.6	21.7	2.85	0.293

## References

- Moore KL, Agur AM, Dalley AF. Clinically Oriented Anatomy. Wolters Kluwer: Lippincott Williams and Wilkins ; 2014., p. 516–520.
- Standing S, Borley NR, Healy JC, Collins P, Johnson D, et al. 40th ed. Elsevier Science Limited ; 2008,.
- Mistri S. A study of femoral condylar morphometry. *Indian J Basic Appl Med Res*;2015(4):500–510.
- Palastanga N, Field D, Soames R. Anatomy and Human Movement. vol. 234. Elsevier Science Limited ; 2002., p. 334–336. 4th Ed.
- Terzidis I, Totlis T, Papathanasiou E, Sideridis A, Vlasik K, et al. Gender and Side-to-Side Difference in Femoral Condyles Morphology: Osteometric Data from 360 Caucasian Dried Femora. *Anatomy Res Int*. 2012;p. 1–6.
- Mistri S, Majumdar S, Biswas S. Morphometric study of some lower femoral anatomy in Eastern Indian population. *Indian J Basic Appl Med Res*;2014(4):182–190.
- Hussain F, KadirMd RA, Zulkifly AH, Saat A, Aziz AA, Hossain GM. Anthropometric Measurements of the Human Distal Femur: A Study of the Adult Malay Population. *Biomed Res Int*. 2013;9(5).
- Insall J. Surgical techniques and instrumentation in total knee arthroplasty. 5th ed. New York: Churchill Livingstone ; 2012., 5th ed.
- Shahi AS, Masoudi A, Kazemianghh A, Hr, Hosseinzadeh H, Yeganeh M. Intech Open Access Publisher ; 2013,.
- Mahfouz M, Fatah EEA, Bowers LS, Scuderi G. Three-dimensional morphology of the knee reveals ethnic differences. *Clin Orthop Relat Res*. 2012;470(1):172–185.
- Vaidya SV, Ranawat CS, Aroojis A, Laud NS. Anthropometric measurements to design total knee prostheses for the Indian population. *J Arthroplasty*. 2000;15(1):79–85.
- Ho WP, Cheng CK, Liao JJ. Morphometrical measurements of resected surface of femurs in Chinese knees: correlation to the sizing of current femoral implants. *Knee*. 2006;13(1):12–16.
- Biswas A, Bhattacharya S. A morphometric and radiological study of the distal end of femur in West Bengal population. *IJAE*. 2017;122(1):39–48.
- Ravichandran D, Melanie R. Morphology of the intercondylar notch and its clinical significance. *IJAS*. 2010;1:26–30.
- Shweta J, Renu C. Morphometric analysis of condyles and intercondylar notch of femur in north Indian population and its clinical significance. *J Evolution Med Dent Sci*. 2017;6(32):2605–2608.
- Taner Z, Murshid KA. An analysis of Anatolian human femur anthropometry. *Turk. J Med Sci*. 2002;32:231–235.
- Chavda HS, Jethva KN, Gupta S. A Study of Morphometric Analysis of Condyles of Adult Dry Femur of Humans in Gujarat Region. *Int J Anatomy, Radiol Surg*. 2019;8(3):1–05.
- Souryal TO, A MH, Evans JP. Bilaterality in anterior cruciate ligament injuries: associated intercondylar notch stenosis. *Am J Sports Med*. 1988;16(5):449–454.

## Author biography

**VINAY G** Professor and HOD

**Vikram S** Associate Professor

**Cite this article:** VINAY G , Vikram S . A study of morphometric analysis of distal end of femur and its clinical importance. *Indian J Anat Surg Head Neck Brain* 2019;5(4):114-117.