



Case Report

Nasopharyngeal teratoma, A rare case

Krishna Medha¹, L N Garg^{1,*}, Habibulla Khan¹, B. Nitin¹, V S Nijhawan²

¹Dept. of ENT, Maharishi Markandeshwar Institute of Medical Sciences and Research, MMDU, Mullana, Haryana, India

²Dept. of Pathology, Maharishi Markandeshwar Institute of Medical Sciences and Research, MMDU, Mullana, Haryana, India



ARTICLE INFO

Article history:

Received 26-12-2019

Accepted 06-01-2020

Available online 24-01-2020

Keywords:

Nasopharyngeal teratoma.

ABSTRACT

Teratomas are tumours that arise from all the three germ layers (ectoderm, mesoderm and endoderm). They form due to error in migration of germ cells. They can be mature and immature types. Mature teratomas are benign slow growing masses commonly encountered in sacrococcygeal region. Nasopharyngeal teratomas are relatively rare conditions. In new-borns nasopharyngeal teratomas can present with respiratory obstruction at birth, therefore it's important to diagnose them perinatally. In adults they can present with varying degree of nasal obstruction, Eustachian tube blockage, dysphagia etc. based on their size and location. In this case report, presentation of nasopharyngeal teratoma, differential diagnosis and management in adults has been discussed.

© 2019 Published by Innovative Publication. This is an open access article under the CC BY-NC-ND license (<https://creativecommons.org/licenses/by/4.0/>)

1. Introduction

Teratomas are extra gonadal germ cell tumours, which can be mature and immature in nature. Mature teratomas are benign and slow growing. They can contain hair, nails, teeth, muscle, bone salivary glands, thyroid tissue, pancreas tissue etc. They are commonly seen in sacrococcygeal region and rarely seen in nasopharynx. Mature nasopharyngeal teratomas can press on surrounding structures without invading them. Diagnosis can be made perinatally using 3D USG, to aptly manage the respiratory obstruction caused by them. In adults CT and MRI should be done, to differentiate it from other masses and plan surgical excision.

2. Case Report

A 15 year old female patient came to ENT OPD with complaints of bilateral nasal obstruction since one month. On self-examination in mirror patient also noticed a mass in her throat one month back. There was no other significant positive history. On local examination, a solitary well

defined cystic mass with hair was seen on left side of oropharynx, of size approximately 2cm x 1cm (Figure 1).

On performing diagnostic nasal endoscopy using a zero degree rigid endoscope, mass was seen arising from posterior wall of nasopharynx, just below the septum and grade 2 adenoid hypertrophy was seen (Figure 2). X-ray nasopharynx lateral view showed soft tissue shadow in nasopharynx (Figure 3). Non contrast CT of paranasal sinuses showed a cystic mass arising from posterior-lateral wall of nasopharynx (Figures 4 and 5).

Excision of the mass was done via trans-oral route (Figures 6 and 7) under general anaesthesia and specimen was sent for histopathological study (Figure 8). Histopathology report showed a cyst lined by stratified squamous epithelium, consisting of mature hyaline cartilage, hair follicles, pilosebaceous units, salivary gland and lymphomononuclear cells, suggesting of mature benign cystic teratoma.

3. Discussion

Teratomas are tumours which are derived from the three embryonic germ layers- endoderm, mesoderm and ectoderm. They can be solid, semi-cystic and cystic in nature. Prevalence of teratoma is 1 in 4000 new-

* Corresponding author.

E-mail address: dr.lngarg@gmail.com (L. N. Garg).

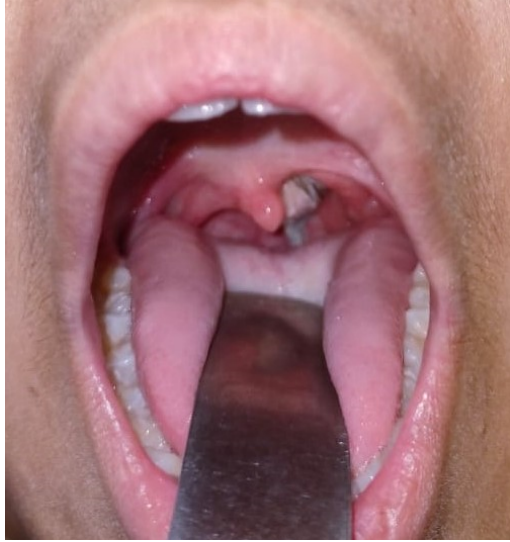

Fig. 1:

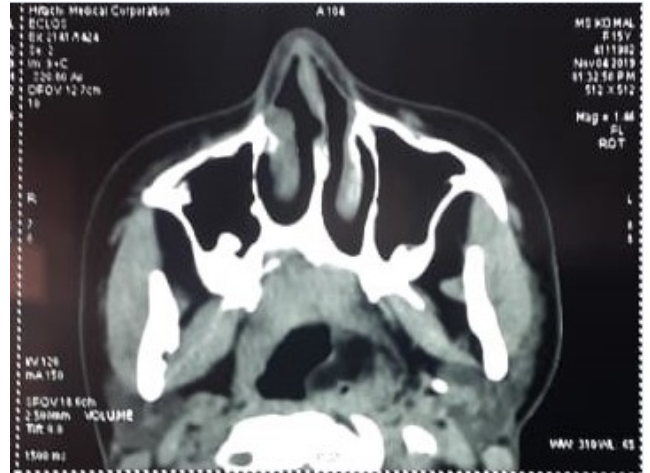

Fig. 4:

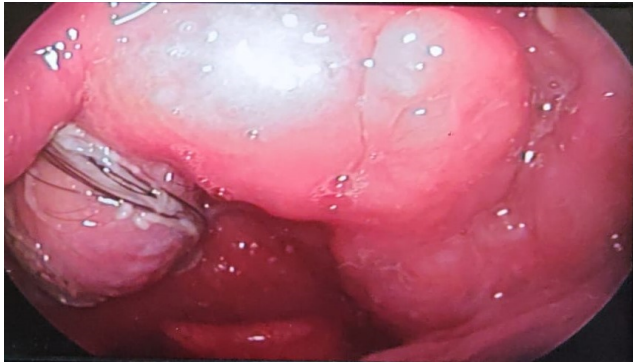


Fig. 2:

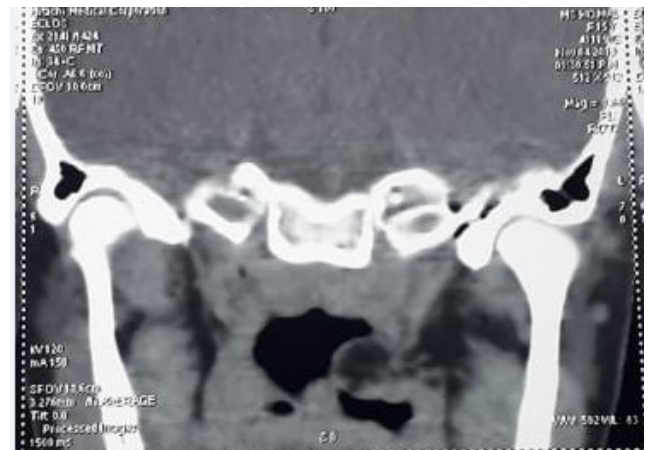

Fig. 5:

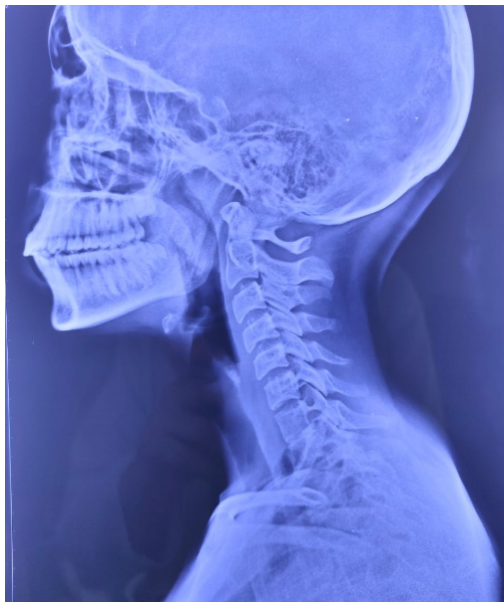

Fig. 3:

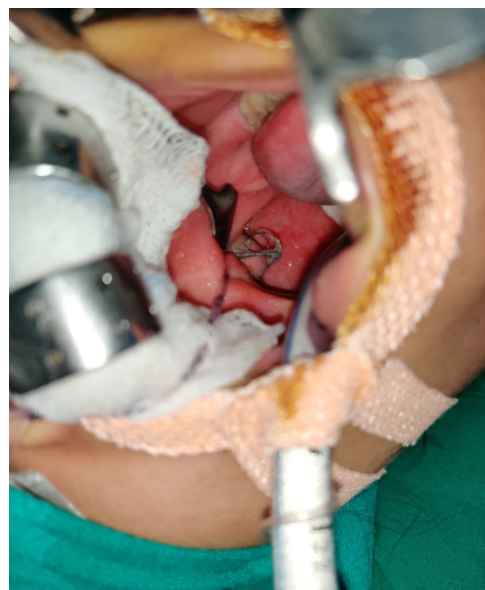

Fig. 6:

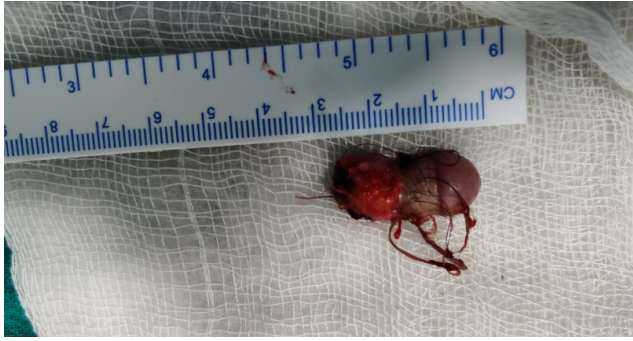


Fig. 7:

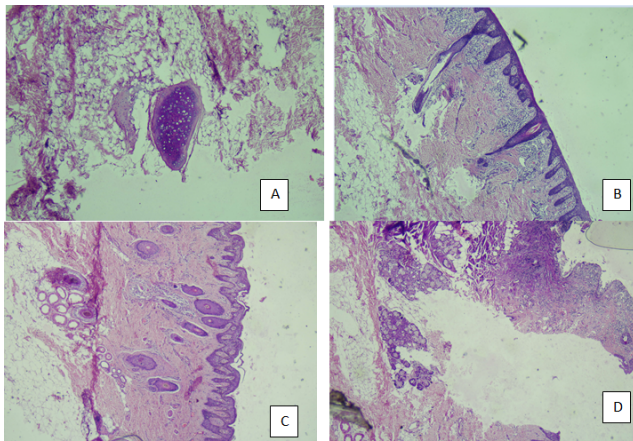


Fig. 8: A,B,C,D

borns.¹ They are most commonly seen in sacrococcygeal region. Head and neck teratomas constitute 6-10% of all teratomas.^{2,3} Sacrococcygeal teratomas usually present in first two months of life.⁴ Nasopharyngeal teratoma can lead to difficulty in breathing at birth or can rarely present later in life with nasal obstruction, depending on size of the mass.⁵ Teratomas can be mature or immature. Mature teratomas contain well-formed tissues derived from the three germ layers. Can contain hair, teeth, nails, muscle, cartilage, bone, salivary gland, thyroid, liver pancreas etc. teratomas occur due to error in embryonic migration.^{6,7} They are also believed to form due to activation of genetic codes in normal cells.⁷ Three dimensional ultrasonography is the investigation of choice for congenital teratomas. It is important to rule out this condition perinatally to anticipate and plan for the possibility of respiratory distress in newborns.^{2,8,9} In adults they can present with nasal obstruction, obstruction of pharyngeal opening of Eustachian tube, dysphagia etc., bases on the size and site of the tumour. CT and MRI should be done in adults, to differentiate it from other nasopharyngeal masses, to see intracranial extension and to plan for surgery.^{10,11} Other possible masses in nasopharynx can be Thornwaldt cyst, Hairy polyp, Papilloma, A denomatous polyp, Schwannoma, Dermoid, Pleomorphic adenoma, rhabdomyosarcoma. As

for treatment, they should be excised completely, without leaving any remnants to avoid recurrence and patient should be kept in follow up.¹

4. Source of Funding

None.

5. Conflict of Interest

None.

References

1. Coppit GL, Perkins JA, Manning SC. Nasopharyngeal teratomas and dermoids: a review of the literature and case series. *Int J Pediatr Otorhinolaryngol.* 2000;52(3):219-227.
2. Wong BY, Ng RW, Yuen AP, Chan PH, Ho WK, Wei WI. Early re-section and reconstruction of head and neck masses in infants with upper airway obstruction. *Int J Pediatr Otorhinolaryngol.* 2010;74:287-291.
3. Tonni G, Felice CD, Centini G, Ginanneschi C. Cervical and oral teratoma in the fetus: a systematic review of etiology, pathology, diagnosis, treatment and prognosis. *Arch Gynecol Obstet.* 2010;282:355-356.
4. Hossein A, Mohammad A. Huge teratoma of the nasopharynx. *Am J Otolaryngol.* 2007;28:177-179.
5. Chaudhry AP, Lor JM, Fisher JE, Gambino AG. So-called hairy polyps or teratoid tumors of the nasopharynx. *Arch Otolaryngol.* 1978;104:517-525.
6. Smirniotopoulos JG, Chiechi MV. Teratomas, dermoids, and epidermoids of the head and neck. *Radiographics.* 1995;15:1437-1455.
7. Varras M, Akrivis C, Plis C, Tsoukalos G. Antenatal sonographic diagnosis of pharyngeal teratoma: our experience of a rare case with review of the literature. *Obstet Gynecol Int.* 2009;p. 180643-180643.
8. Izadi K, Smith M, Askari M, Hackam D, Hameed AA, et al. A patient with an epignathus: management of a large oropharyngeal teratoma in a newborn. *J Craniofac Surg.* 2003;14:468-472.
9. Demajumdar R, Bhat N. Epignathus: a germ-cell tumour presenting as neonatal respiratory distress. *Int J Pediatr Otorhinolaryngol.* 1999;47:87-90.
10. Sigal R, Ousehal A, Pharaboz C, Leridant A, Bosq J, et al. Nasopharyngeal teratoma: CT and MR findings. *Eur Radiol.* 1997;7(1):96-98.
11. Nicklaus PJ, Forte V, Thomer PS. Hairy polyp of the eustachian tube. *J Otolaryngol.* 1991;20(4):254-257.

Author biography

Krishna Medha Resident

L N Garg Professor

Habibulla Khan Resident

B. Nitin Resident

V S Nijhawan Professor and Head

Cite this article: Medha K, Garg LN, Khan H, B. Nitin, Nijhawan VS. Nasopharyngeal teratoma, A rare case. *Indian J Anat Surg Head Neck Brain* 2019;5(4):127-129.