

Content available at: <https://www.ipinnovative.com/open-access-journals>

IP Indian Journal of Anatomy and Surgery of Head, Neck and Brain

Journal homepage: <https://www.ijashnb.org/>

Case Report

Anatomical variation in arterial supply of liver – Case study

Dinesh Kumar^{1,*}, Mitesh R Dave¹

¹Dept. of Anatomy, Parul Institute of Medical Sciences and Research (Parul University), Vadodara, Gujarat, India



ARTICLE INFO

Article history:

Received 08-06-2021

Accepted 07-07-2021

Available online 09-08-2021

Keywords:

Anatomical variation

Transplantation

Cholecystectomy

Gastrectomy

ABSTRACT

The variations of blood supply of liver is of great importance for general surgery, particularly hepatic surgery. Blood supply of liver is significant for liver transplantations, radiological procedures, and laparoscopic method of operation and for the healing of penetrating injuries, including the space close to the hepatic area.

The pattern of the normal vascular system of the liver comes from the common hepatic artery (CHA), originating from the celiac trunk. The gastroduodenal artery (GDA), right gastric artery (RGA) and proper hepatic artery (PHA) are the main branches of the CHA. After that, the division of the PHA composes the left and right hepatic branches.

Case Report: During a routine dissection with medical students from the Department of Anatomy, Parul institute of Medical sciences and research Vadodara, We found on one cadaver that the blood supply of the liver differed from a normal blood supply of liver.

In one cadaver we found that liver is supplied by a direct branch from celiac trunk and in same cadaver liver is also supplied by proper hepatic artery.

Conclusion: The knowledge about the variations in hepatic arterial anatomy is very important for surgical gastroenterologists and interventional radiologists for preoperative planning and intraoperative imaging during procedures like liver transplantation, cholecystectomy, gastrectomy, hiatal hernia repair, trans-arterial chemotherapy and hepatic arteriography.

This is an Open Access (OA) journal, and articles are distributed under the terms of the [Creative Commons Attribution-NonCommercial-ShareAlike 4.0 License](https://creativecommons.org/licenses/by-nc-sa/4.0/), which allows others to remix, tweak, and build upon the work non-commercially, as long as appropriate credit is given and the new creations are licensed under the identical terms.

For reprints contact: reprint@ipinnovative.com

1. Introduction

Normally Liver is supplied by the common hepatic artery (CHA), originating from the celiac trunk. The gastroduodenal artery (GDA), right gastric artery (RGA) and proper hepatic artery (PHA) are the main branches of the CHA. After that, the division of the PHA composes the left and right hepatic branches. The main variant is the origin of the right hepatic artery or replacement of this artery with accessory hepatic arteries. The lobes of the liver may receive nutrition from the superior mesenteric artery (SMA), left gastric artery (LGA), directly from the aorta or from the

renal artery. The size of the accessory artery is often smaller but their function and specific distribution are interesting for each case. The main purpose of this case report is to describe one different pattern of the hepatic artery branching from the classically explained. This case may also open the way in the future for thinking about the origin of such hepatic variants.

The variations of blood supply of Liver are of great importance for general surgery, particularly hepatic surgery. Vascular variations are significant for liver transplantations, radiological procedures, and laparoscopic method of operation and for the healing of penetrating injuries, including the space close to the hepatic area. The anatomical knowledge of liver vascular variants is essential for reducing

* Corresponding author.

E-mail address: choudharyyadinesh@gmail.com (D. Kumar).

operative and postoperative morbidity and mortality in donors and recipients. Recently, due to the increase in the number of liver transplants, the importance of the hepatic artery anatomy has become obvious. The lack of normal blood supply to the liver is usually asymptomatic, until it is also interrupted to the visceral organs. We can find these variants of blood supply during diagnostic angiography. Vascular variants are very common in the abdominal region, and their description and study will be useful.

2. Case Report

During a routine dissection with 1st year MBBS students in the Department of Anatomy, Parul institute of Medical sciences and research Vadodara, We found on one cadaver that the blood supply of the liver differed from a normal blood supply of liver.

In one cadaver we found that liver is supplied by a direct branch from celiac trunk and in same cadaver liver is also supplied by proper hepatic artery. This artery which is also called as accessory hepatic artery is directly derived from celiac trunk and enter with in porta hepatis and Right gastric artery also arises from accessory hepatic artery.

In same cadaver liver is also supplied by proper hepatic artery which is divided into right and left hepatic artery.

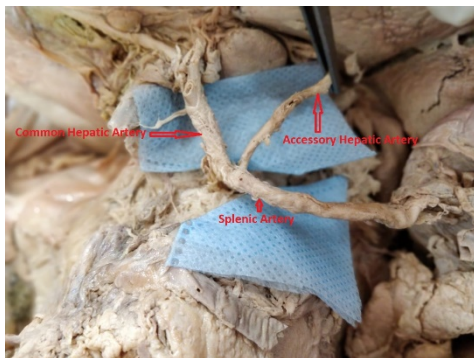


Fig. 1:

3. Discussion

According to Michels, the incidence of replaced right hepatic artery was 18% and accessory left hepatic artery was 11.5%. He also reported that the source of origin of replaced right hepatic artery was from superior mesenteric artery in 12.5%, from celiac trunk 3%, from aorta 2% and from left gastric artery in 0.5% of cases. Moreover, the source of origin of accessory left hepatic artery was from left gastric artery in 11.5% of cases.¹ Molmenti et al. reported that the presence of replaced right hepatic artery in 15-20% and accessory left hepatic artery in 35% of cases.²

Jones and Hardy reported on the origin of middle hepatic artery from gastroduodenal artery in 8.7%.³

Galen was the first anatomist who researched the arterial system from the celiac trunk and observed the arteries leading to the liver, stomach and spleen. Later on Andreas Vesalius gave anatomical descriptions of the Galen's discoveries in the sixteenth century, commenting the CHA and splenic artery.

Hepatic artery variation described by Michels et al. in the 1966⁴ was based on dissection of 200 cadavers.⁵ These authors explain 10 basic anatomical variations which were reduced to 6 types by Hiatt et al. in 1994⁶ after the observations of 1000 donors at the time of transplantation between 1983 to 1993. According to the observations, 60% represent classical variations of blood supply and 40% show different anatomical variations.

The variants of the hepatic artery have their origins in the embryo development. At the time of angiogenesis of the celiac trunk (CT), the most important vessels include the ventral splanchnic arteries which start directly from the embryonic aorta. The splanchnic arteries sprout 4 individual branches and many longitudinal anastomoses at different levels. The first main branches, the primitive celiac axis, originate the normal branches of CT such as spleen, left gastric and common hepatic arteries. The next 2 branches are obliterated and the last one become SMA. The variation of hepatic artery when the RHA is absent and is totally replaced by an accessory right hepatic artery from the SMA is a rarer variant.³ This is because the embryology does not explain the origin of this anomaly and this variant, as is our case study, which is a riddle for science.

4. Conclusion

The knowledge about the variations in hepatic arterial anatomy is very important for surgical gastroenterologists and interventional radiologists for preoperative planning and intraoperative imaging during procedures like liver transplantation, cholecystectomy, gastrectomy, hiatal hernia repair, trans-arterial chemotherapy and hepatic arteriography.

5. Source of Funding

None.

6. Conflict of Interest

The author declares no conflict of interest.

References

1. Michels NA. Blood supply and anatomy of the upper abdominal organs with a descriptive atlas. Philadelphia and Montreal, B Lippincott Company. 1955;p. 134–183.
2. Molmenti EP, Pinto PA, Klein J, Klein AS. Normal and variant arterial supply of the liver and gallbladder. *Pediatr Transplant.* 2003;7(1):80–2. doi:10.1034/j.1399-3046.2003.02046.x.
3. Jones RM, Hardy KJ. The hepatic artery: a reminder of surgical anatomy. *J R Coll Surg Edinb.* 2001;46:168–70.

4. Yang Y, Jiang N, Lu MQ, Xu C, Cai CJ, Li H. Anatomical variation of the donor hepatic arteries: analysis of 843 cases. *Nan Fang Yi Ke Da Xue Xue Bao*. 2007;27:1164–6.
5. Michels NA. Newer anatomy of the liver and its variant blood supply and collateral circulation. *Am J Surg*. 1966;112(3):337–47. doi:10.1016/0002-9610(66)90201-7.
6. Hiatt JR, Gabbay J, Busuttil RW. Surgical Anatomy of the Hepatic Arteries in 1000 Cases. *Ann Surg*. 1994;220(1):50–2. doi:10.1097/00000658-199407000-00008.

Author biography

Dinesh Kumar, Tutor

Mitesh R Dave, Professor and HOD

Cite this article: Kumar D, Dave MR. Anatomical variation in arterial supply of liver – Case study. *IP Indian J Anat Surg Head, Neck Brain* 2021;7(2):64-66.