

# Removal of an impacted button battery from upper oesophagus in an infant with tele-endoscope avoiding lateral pharyngotomy

Arunabha Chakraborti<sup>1</sup>, Sunil Garg<sup>2,\*</sup>

<sup>1</sup>Professor, Lady Hardinge Medical College, New Delhi, <sup>2</sup>Assistant Professor, ENT & Head, Neck, Surgery, Dr. BSA Medical College & Hospital, New Delhi

**Corresponding Author:**

**Sunil Garg**

<sup>2</sup>Assistant Professor, ENT & Head, Neck, Surgery, Dr. BSA Medical College & Hospital, New Delhi

E-mail: dr.sunilgarg09@gmail.com

---

## Abstract

*Button battery ingestion is associated with many complications. We are presenting a case of an infant presented in a state of respiratory difficulty and dysphagia having history of button battery ingestion. Removal at first attempt with conventional oesophagoscope was unsuccessful due to the sharp edges of the battery getting stuck in the surrounding mucosa. The tele-endoscope guided removal at second attempt was successful preventing the need for pharyngotomy. Present case provides us a latest technologically advanced tool which can help us remove an entangled button battery from upper aero digestive tract preventing complications hitherto unreported in world medical literature.*

**Keywords:** Button battery, Telescope

---

## Introduction

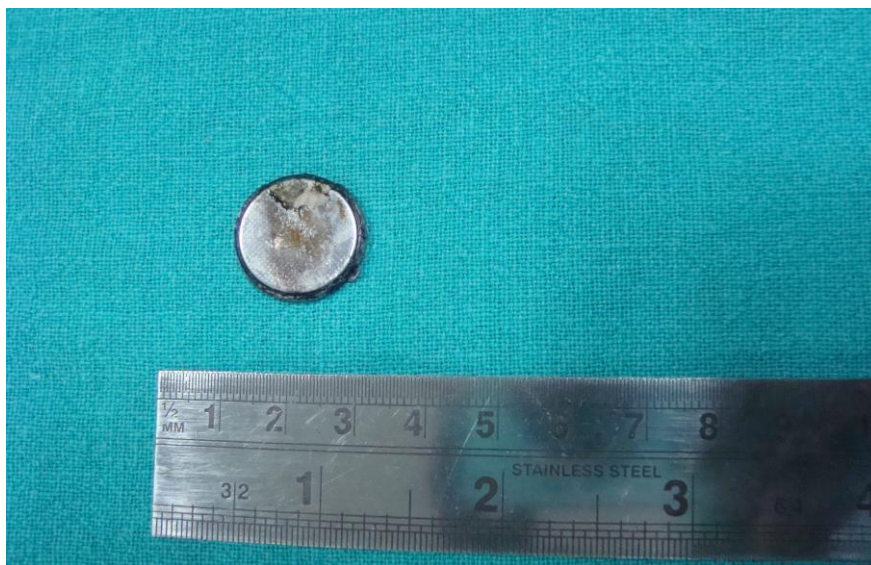Foreign body ingestion is a common occurrence in infants. The oesophageal ingestion of a fully charged button battery is associated with lot of life threatening complications.<sup>1</sup> Lithium battery of 20 mm is more dangerous due to its size.<sup>1</sup> The oedema and slough produced by discharging of the button battery makes it difficult to remove such a foreign body by a conventional oesophagoscope. A rigid tele-endoscope attached with camera and monitor is a novice modality used in removal of upper aero-digestive tract foreign bodies especially which are difficult to remove.

We hereby are presenting such a rare case of difficult entangled button battery removal in an infant with precise control under tele-endoscopic guidance without any complication.

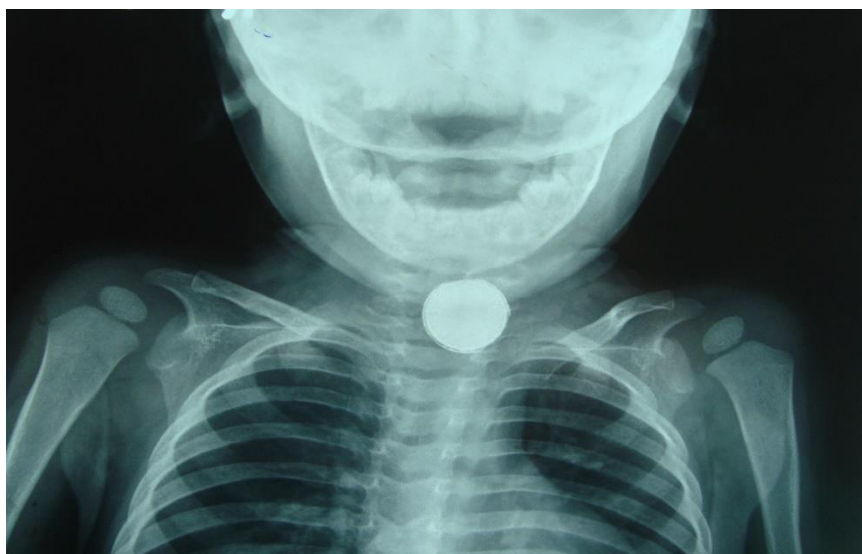
## Case Report

A child of 1 year age came to ENT OPD with history of button battery ingestion and the chief complaints of dysphagia, respiratory difficulty and fever since one day. The patient was immediately admitted and as a routine investigation chest X-ray and X-ray soft tissue neck was advised. A button battery was found stuck at the level of upper oesophagus (Fig. 1). The child was kept in emergency operation theatre for removal of

foreign body. On esophagoscopy, we found a lot of slough at the level of upper end of oesophagus. The slough was cleaned and the battery was found stuck in the mucosa. Even after giving 2-3 attempts at battery removal we could not retrieve the battery. The case was abandoned at that time. Then the case was planned for either tele-endoscopy removal or removal through lateral pharyngotomy. And the very next day the child was kept for battery removal under general anaesthesia in main operation theatre. To improve our vision we used rigid tele-endoscope through the esophagoscope which was attached to the monitor through a camera. Due to a distal vision provided by tele-endoscope, the battery was dislodged from its mucosal attachments (3 places) by its sharp edges. Button battery (20mm size) could be removed in a single attempt with no further mucosal injury avoiding the need for lateral pharyngotomy (Fig. 2). The patient was easily extubated and discharged the next day after she started to accept feed after getting a chest X-ray done which was normal. After 1 month the child was kept for check esophagoscopy and there was normal mucosal healing with no stricture formation. Child could be managed without any complications.



**Fig. 1: Removed Button battery**



**Fig. 2: X-ray showing button battery at the level of upper esophagus**

### **Discussion**

Button battery ingestion is not an uncommon occurrence. It more commonly presents in quite tender age group of 1-4 years. Complications are not exceptions in these cases which include simple stricture to trachea-oesophageal fistula.<sup>2,3</sup> Prevention of complications has always remained a cause of concern for the clinicians. There had been a long research on various methods to decrease the complications which include preventing the access of button battery for children, development of waterproof quantum tunnelling composite coated button batteries and formation of button battery task force.<sup>2,3</sup> Despite all these efforts the incidence of button battery ingestion as well as its associated complications

has not come down.<sup>3</sup> Late presentation remains the most common cause for the patient going into complications.<sup>3</sup>

Improper removal of a discharged button battery contributes a lot to mucosal trauma in an already compromised mucosal tissue thus contributing to complications. Slough as well as oedema makes life of the surgeon difficult during its removal. The sharp edges of the button battery (which happens due to discharged battery) gets entangled into adjacent mucosal tissue leading to further mucosal trauma to an already necrosed and vulnerable oesophageal mucosa which can convert a superficial ulcer to more deeper one.

It is important to prevent this mucosal injury by using more precise and meticulous endoscopic

removal. Conventional oesophagoscope provides a distant vision as well as poor control over the foreign body during its removal. Removal under rigid tele-endoscopic guidance with camera attachment and monitor provides a closer and better view with good anatomical details which is very much needed during removal of sharp foreign bodies. Our case highlights the importance of using tele-endoscopescope in such cases. In our case, this prevented need for lateral pharyngotomy or thoracotomy and the patient morbidity. Future search is needed in this direction which can contribute significantly in preventing complications in cases of button battery ingestion.

3. Jatana KR, Litvitz T, Rielly JS, Koltai PJ, Rider G, Jacob IN. Pediatric button battery injuries: 2013 task force update. *Int J Pediatr Otorhinolaryngol* 2013;77:1392-9.

### **Acknowledgement**

The authors thank Director, Lady Hardinge Medical College & Associated Hospitals, for allowing us to publish this manuscript.

### **Author's Contributions**

Dr. A. Chakravarti and Dr. Sunil Garg contributed towards clinical management of the patient; conceptualization and revision of the manuscript. Dr. Sunil Garg contributed towards the literature search and drafting the manuscript. Dr. Sunil Garg also helped in clinical management and revision of the manuscript.

### **Declaration of the conflicting interests**

The authors declared no potential conflicts of interest with respect to and/ or publication of the article.

### **Funding**

Authors received no financial support for the research, authorship and/ or publication of the article.

### **Ethical Approval**

Consent was taken from parents of the children for surgery and publication of the case report.

### **References**

1. Soccorso G, Grossma O, Martinelli M, Marven SS et al. 20mm lithium battery causing an esophageal perforation in a toddler: lessons in diagnosis and treatment. *Arch Dis Child* 2012;97:746-7.
2. Lailitch B, Traverso G, Deshpande V, Langer R, Karp JM. Simple battery arm or to protect against gastrointestinal injury from accidental ingestion. *Proc Natl Acad Sci USA* 2014;111(46):16490-5.