

Content available at: <https://www.ipinnovative.com/open-access-journals>

IP Indian Journal of Anatomy and Surgery of Head, Neck and Brain

Journal homepage: <https://www.ijashnb.org/>

Case Report

An interesting case of reruptured endovascularly coiled aneurysm managed with clipping

Bhavuk Kapoor^{1,*}, Anil Kansal¹, Rohit Bansil¹, Dhawal Sharma¹, Siddharth Mittal¹, Amit Rustogi¹

¹Dept. of Neurosurgery, BLK-Max Super Speciality Hospital, Delhi, India



ARTICLE INFO

Article history:

Received 30-11-2021

Accepted 25-12-2021

Available online 16-01-2022

Keywords:

Endovascular coiling

Recurrent aneurysm

Clipping

Aneurysmal bleed

ICH

ABSTRACT

Background: Endovascular treatment has proven to be effective in the management of intracranial aneurysm, and can achieve permanent occlusion in up to 85% of cases, reducing the bleeding or rebleeding rate. A paradigm shift from microsurgical clipping to endovascular intervention has been observed since the publication of the International Subarachnoid Aneurysm Trial. Aneurysm recurrence after coil embolization remains both a major shortcoming of endovascular treatment and a daunting challenge for neurosurgeons without optimal management strategies.

Materials and Methods: We present a case report of a patient with history of previously endovascularly coiled and presenting with aneurysmal bleed.

Conclusions: Microsurgical clipping is an effective intervention for managing reruptured previously coiled intracranial aneurysm.

This is an Open Access (OA) journal, and articles are distributed under the terms of the [Creative Commons Attribution-NonCommercial-ShareAlike 4.0 License](https://creativecommons.org/licenses/by-nc-sa/4.0/), which allows others to remix, tweak, and build upon the work non-commercially, as long as appropriate credit is given and the new creations are licensed under the identical terms.

For reprints contact: reprint@ipinnovative.com

1. Introduction

Introduction of Guglielmi detachable coil has changed the management of intracranial ruptured and unruptured aneurysm with lower initial morbidity and mortality rates. But coiling has been shown to have greater association with aneurysm recurrence, rebleeding and aneurysm remnant. However, the expansion of endovascular therapy has led to a significant increase in documented incidences of incomplete aneurysm obliteration, neck remnants, and recurrences, indicating an association between endovascular treatment and aneurysm rerupture in the current literature.¹⁻³

Aneurysm recurrence after coil embolization remains both a major shortcoming of endovascular treatment and a daunting challenge for neurosurgeons without optimal management strategies.⁴⁻⁷ However, few data are

available regarding the morphological changes of recurrent aneurysms and their management strategy.

We present a case of reruptured previously coiled anterior communicating artery aneurysm managed with microsurgical clipping.

2. Clinical History and Examination

A 54-year-old male with history of coiling for Acom aneurysm 9 years back presented in the emergency with altered sensorium and right-sided haemiparesis. CTscan of the patient suggested a massive intra-cerebral bleed in the inter-hemispheric region (Figure 1). DSA showed ruptured ACOM Artery aneurysm and the coils were impacted at the neck of aneurysm and were seen extruding from the dome (Figure 2a, b). Challenges in planning the management -

- It was a wide neck previously coiled ruptured aneurysm
- Coils were seen impacted at the neck
- Adjacent large haematoma

* Corresponding author.

E-mail address: kapoorbhavuk14@gmail.com (B. Kapoor).

Patient was planned for surgical clipping of aneurysm. A left frontal-temporal craniotomy was performed. After gentle dissection of sylvian fissure and evacuation of frontal hematoma, the aneurysm appeared in full view.

The dome of the aneurysm was adherent to surrounding brain parenchyma with thin translucent fragile wall (Figure 3). Coils were found encroaching over the neck lumen. After achieving proximal control, the dome was opened and the coils were gently pulled up, to relieve the impaction at the neck and then a permanent clip was applied at neck, securing the aneurysm (Figure 4). Coils were left inside the dome of aneurysm with wrapping of the dome with muscle (Figure 5). Patient did well in the post-operative period.

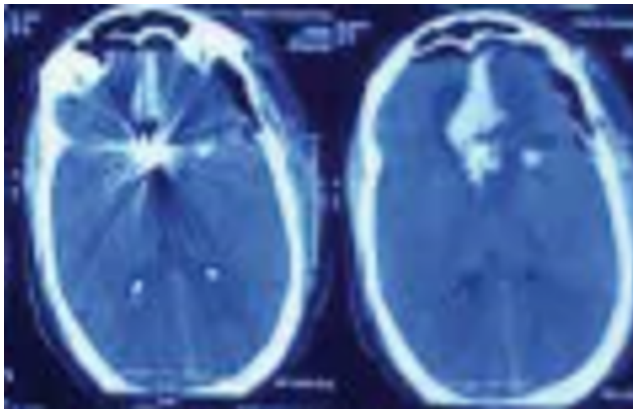


Fig. 1: CT scan of patient

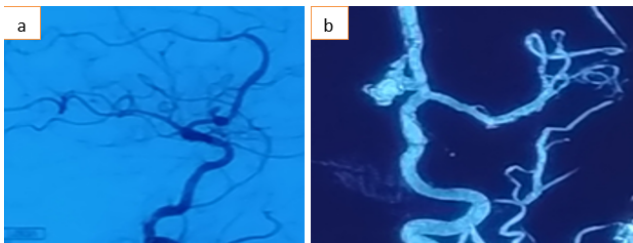


Fig. 2: a and b: Cerebral DSA of patient

3. Discussion

Re-bleed after endovascular coiling occurs mostly within 1 year, with 50% cases reported between 1-3 days. These cases generally carry a high mortality and morbidity rates. Recoiling of recurrent aneurysm comes with its own risk of extrusion of coils, coil compaction, rupture and regrowth of aneurysm. Microsurgical clipping stands as an alternate to recurrent previously coiled aneurysm, but certain conditions make clipping a challenge such as coil mass making it difficult to achieve full occlusion of neck, coil extrusion and availability of minimal neck. The treatment in this case was

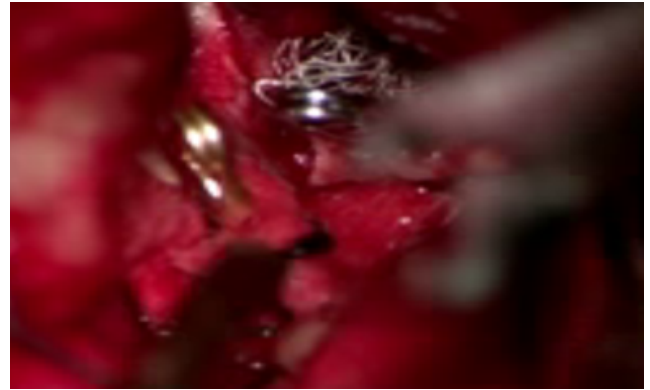


Fig. 3: Intraoperative image

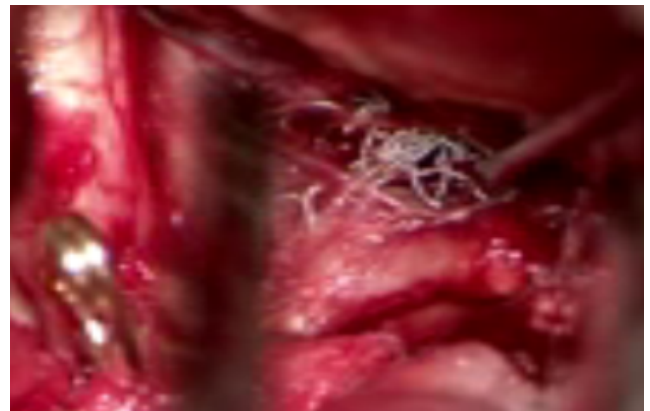


Fig. 4: Intraoperative image

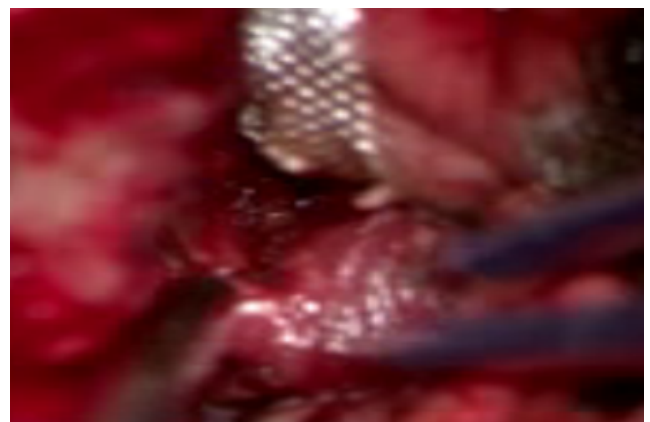

Fig. 5: Intraoperative image

challenging and no clear guidelines are available as very few cases are reported in the literature. This patient was managed surgically with clipping after a lot of meticulous planning.

4. Conclusion

Microsurgical clipping is an effective intervention for managing ruptured previously coiled intracranial aneurysm.

5. Conflicts of Interest

The authors declare that there are no conflicts of interest regarding the publication of this paper.

6. Source of Funding

None.

References

1. Rates of delayed rebleeding from intracranial aneurysms are low after surgical and endovascular treatment. *Stroke*. 2006;37(6):1437–42. doi:10.1161/01.STR.0000221331.01830.ce.
2. Debrun GM, Aletich VA, Thornton J, Alazzaz A, Charbel FT, Ausman JI, et al. Techniques of coiling cerebral aneurysms. *Surg Neurol*. 2000;53(2):150–6. doi:10.1016/s0090-3019(99)00194-9.
3. Hayakawa M, Murayama Y, Duckwiler GR, Gobin YP, Guglielmi G, Viñuela F, et al. Natural history of the neck remnant of a cerebral aneurysm treated with the Guglielmi detachable coil system. *J Neurosurg*. 2000;93(4):561–8. doi:10.3171/jns.2000.93.4.0561.
4. Boet R, Poon WS, Yu SC. The management of residual and recurrent intracranial aneurysms after previous endovascular or surgical treatment—a report of eighteen cases. *Acta Neurochir (Wien)*. 2001;143(11):1093–101. doi:10.1007/s007010100001.
5. Chung J, Lim YC, Kim BS, Lee D, Lee KS, Shin YS, et al. Early and late microsurgical clipping for initially coiled intracranial aneurysms. *Neuroradiology*. 2010;52:1143–51. doi:10.1007/s00234-010-0695-4.
6. Dorfer C, Gruber A, Standhardt H, Bavinzski G, Knosp E. Management of residual and recurrent aneurysms after initial endovascular treatment. *Neurosurgery*. 2012;70(3):537–53. doi:10.1227/NEU.0b013e3182350da5.
7. Sanai N, Caldwell N, Englot DJ, Lawton MT. Advanced technical skills are required for microsurgical clipping of posterior communicating artery aneurysms in the endovascular era. *Neurosurgery*. 2012;71(2):285–95. doi:10.1227/NEU.0b013e318256c3eb.

Author biography

Bhavuk Kapoor, Associate Consultant

Anil Kansal, Director and HOD

Rohit Bansil, Consultant

Dhawal Sharma, Associate Consultant

Siddharth Mittal, Associate Consultant

Amit Rustogi, ICU Incharge Neuro ICU

Cite this article: Kapoor B, Kansal A, Bansil R, Sharma D, Mittal S, Rustogi A. An interesting case of ruptured endovascularly coiled aneurysm managed with clipping. *IP Indian J Anat Surg Head, Neck Brain* 2021;7(4):126–128.