

Content available at: <https://www.ipinnovative.com/open-access-journals>

IP Indian Journal of Anatomy and Surgery of Head, Neck and Brain

Journal homepage: <https://www.ijashnb.org/>

## Case Report

# Dual migration of organic foreign body in bronchus

Suji P S<sup>1</sup>, Abhishek Bhardwaj<sup>1,\*</sup>, Manu Malhotra<sup>1</sup>,  
Surjalata Devi Nongthombam<sup>1</sup>, Madhu Priya<sup>1</sup>, Rachit Sood<sup>1</sup>

<sup>1</sup>Dept. of Otorhinolaryngology and Head Neck Surgery, All India Institute of Medical Sciences, Rishikesh, Uttarakhand, India



### ARTICLE INFO

#### Article history:

Received 25-02-2022

Accepted 08-03-2022

Available online 02-04-2022

#### Keywords:

Organic  
Bronchoscopy  
Foreign body  
Bronchu

### ABSTRACT

The foreign body in the bronchus is one of the most fatal emergencies in the Otorhinolaryngology. Delay in the appropriate treatment may result in acute airway diseases and fatal complications. The aim of this manuscript is to report a clinical case of dual migration of an organic foreign body from left to right and then back to the left bronchus in a 13 months old child. The case was initially diagnosed as left sided severe pneumonia which recurred after initial partial response to medical management and thus raised the suspicion of a foreign body. Computed tomography of the chest revealed a foreign body in the right bronchus contrary to clinical findings on the left side suggesting the first migration. The foreign body was visualized and removed from the left bronchus during bronchoscopy; which was contrary to radiological findings, suggesting the second migration.

This is an Open Access (OA) journal, and articles are distributed under the terms of the [Creative Commons Attribution-NonCommercial-ShareAlike 4.0 License](https://creativecommons.org/licenses/by-nc-sa/4.0/), which allows others to remix, tweak, and build upon the work non-commercially, as long as appropriate credit is given and the new creations are licensed under the identical terms.

For reprints contact: [reprint@ipinnovative.com](mailto:reprint@ipinnovative.com)

## 1. Introduction

The foreign body (FB) in the bronchus is one of the main emergencies in pediatric Otorhinolaryngology. As per the literature, FB aspiration leads to 7% of mortality among children less than four years old in developed countries. The rate is increased to 75-85% in children under the age of 15 years.<sup>1</sup> There are two types of FB; organic and inorganic. Organic FBs (nuts, seeds, shells etc.) were most common and fatal in the pediatric age group than inorganic ones (pins, needles, coins, batteries etc.).<sup>2,3</sup> FBs are more commonly lodged in the right Bronchus due to its anatomical variations like greater diameter of right bronchus, smaller angle of deviation from the tracheal axis, and greater volume of air entering during inspiration. Lodgment of FB site depends on its size (the smaller foreign body will lodge in the segmental bronchi and thin foreign bodies will lodge in the periphery).<sup>4</sup> Organic FBs have more

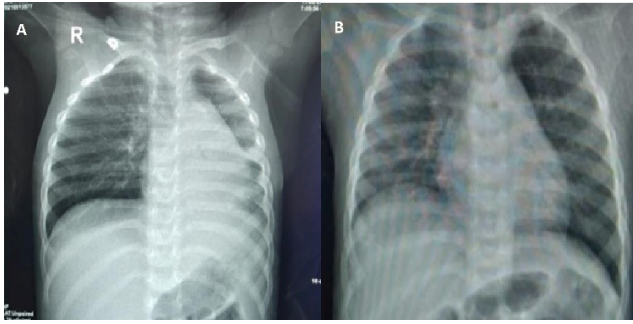
complications as they swell up due to osmosis and result in reaction with bronchial secretions leads to inflammation and granuloma formation, making this difficult to extract. In most cases, they are asymptomatic and may cause a problem in diagnosing and treatment. Delayed diagnosis can lead to fatal complications and severe morbidity. This case report aims to highlight the possibility of migration of FB from one bronchus to the other, which may occur at any time interval after accidental aspiration and hence makes bilateral bronchoscopic evaluation important, irrespective of FB location as suggested by clinical and radiological findings.

### 1.1. Case presentation

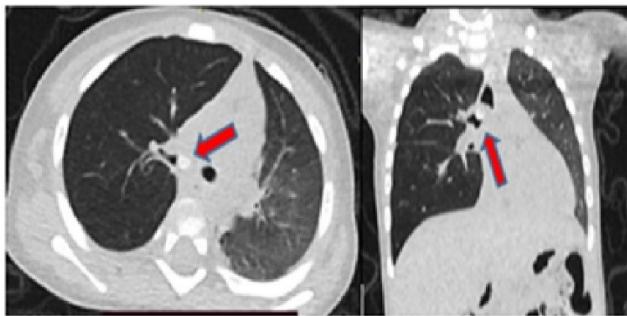
A 13 months old male child was admitted with complaints of high-grade fever for 7 days, shortness of breath and cough for 5 days. For a description of events, the day of onset of fever is being mentioned as day 1; the patient was admitted on day 7. There was no history of FB

\* Corresponding author.

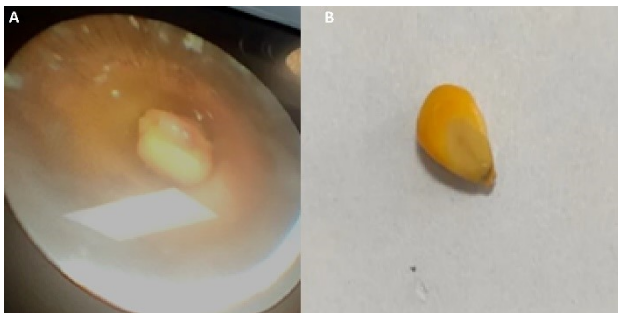
E-mail address: [Abhi04stanley@gmail.com](mailto:Abhi04stanley@gmail.com) (A. Bhardwaj).



**Fig. 1:** Chest x-ray showing A) preoperative x-ray showing left lung collapse and consolidation. B) postop X-ray showing increased broncho vascular markings in the right side and expanded left lung.



**Fig. 2:** CT scan showing foreign body in the right bronchus.



**Fig. 3:** A) rigid bronchoscopy showing yellow-coloured corn seed noted in the left bronchus. B) corn seed removed from the left bronchus.

aspiration. On clinical examination, air entry to the left side of the lung was diminished along with the presence of crepitations, subcostal retraction and grunting. Chest x-ray revealed an opaque left lung field with features of collapse and consolidation (Figure 1). The child was treated for severe pneumonia and received intravenous antibiotics (Ceftriaxone and Azithromycin), along with low flow oxygen. The child improved symptomatically and serial x-rays showed expanding lung, and hence discharged in satisfactory condition on day 10. After discharge, he developed multiple episodes of cough and fast breathing

on Day 11. Chest x-ray on day 11 revealed left side hyperinflation. In view of deteriorating clinical symptoms, the child was readmitted on day 11 and started intravenous Linezolid antibiotics, nebulization with Salbutamol and low flow oxygen. Repeat chest x-ray and fluoroscopy for the expiratory scan on day 12 showed reduced left lung movements and air trapping in the left lower lobe. High resolution computed tomography (HRCT) of the chest done on day 13 showed an FB in the right bronchus and suggested features of left lower lobe collapse (Figure 2). The patient was planned for a rigid bronchoscopy assessment of the airway under general anaesthesia. Rigid bronchoscopy was performed on day 13 showing pooling of secretions in the left main bronchus and normal appearing right main bronchus. After suctioning the secretions in the left main bronchus, a corn seed was identified and removed (Figure 3). The bilateral bronchial tree was evaluated till the level of tertiary bronchi. There was no obvious mucosal injury noted in the bilateral bronchial mucosa. The postoperative period was uneventful and the child was discharged in satisfactory condition on day 15. On follow up examination, he was active and playful, with normal breathing patterns and breath sounds.

## 2. Discussion

Aspirated FB bronchus is one of the major morbidity and mortality in children. In most cases, it can mimic other lung pathologies like asthma, Croup and Pneumonia, which may lead to mismanagement and fatal complications. In 1854, S D. Gross elaborated a study regarding the FB in the air passage. He accentuated the importance of clinical history and examination which may lead to the suspicion of FB.<sup>5</sup> In children, FB in the trachea always mimic viral croup. Recurrent or non-resolving wheeze or stridor after medical management cases should have been investigated for FBs.<sup>6</sup> In our case, fever was the initial symptom followed by respiratory difficulty favouring the diagnosis of pneumonia.

Chest x-ray findings in FB aspiration in children were first described by Chatterjee et al. in 1972. They enlightened that radiographs taken in full inspiration and expiration will improve the sensitivity.<sup>7</sup> Sensitivity of bronchial FB in CT scan is 100% as compared to the specificity (66.7-100%).<sup>8</sup> Chest radiograph may reveal normal findings as well as features of air trapping, pneumonia, atelectasis and perihilar infiltrates which may mislead to other lung pathologies.

As per the literature, the FB has male predominance and is most common in the right bronchus due to its anatomical variations. In our case, the FB was lodged initially in the left bronchus as per clinical and x-ray findings. HRCT chest showing the FB in the right bronchus indicates the possibility of migration of FB to the right either on day 13 or prior. Bronchoscopy findings suggest the re-migration to the left on day 13 itself. Non- development of right sided

pulmonary symptoms or clinical findings suggest a small duration of lodgment of FB in the right bronchus. Forceful tidal airflow in the bronchi during inspiration and expiration may result in blowing of small FB in and out of bronchi. A comparatively larger internal diameter of the bronchi to the small size of the FBs results in migration of FB from one bronchus to the other by the tidal airflow. Sharply pointed as well as irregularly shaped objects will tend to adhere to the tracheal mucosa and would not expel.<sup>9</sup> Migration is unlikely in organic FBs due to the immediate response of inflammatory reactions. We encountered a dual migration possibly due to the small size and the smooth surface of corn seed, which did not swell up, hence resulting in hindering of inflammatory responses on tracheal mucosa.

Rigid bronchoscopy is a universally accepted best treatment modality in FB removal.<sup>10</sup> The FB's position may change any time before the surgical intervention. The bilateral bronchial tree should be evaluated till the maximum point of negotiation of endoscope or bronchoscope to rule out the possibility of migrated or another FB. The major complications noted during bronchoscopy are mediastinal emphysema, atelectasis, pneumothorax, tracheoesophageal fistula and bronchiectasis.<sup>11</sup> In our case, the procedure was uneventful. As per the literature search on PubMed and Google Scholar with keywords, "Bronchoscopy", "Foreign body", and "Bronchus", this is the first case report of dual migration of an organic foreign body in the bronchus.

### 3. Conclusion

The foreign body may migrate from one bronchus to the other. Both the bronchus should be evaluated even if the radiology or clinical findings are suggestive of a foreign body in one bronchus. Bronchoscopy is the definitive way of ruling out the possibility of a foreign body in a suspicious case.

Early suspicion of a foreign body and corresponding investigations will be helpful to prevent fatal acute airway events in pediatric cases.

### 4. Source of Funding

None.

### 5. Conflict of Interest


The author declares that there is no conflict of interest.


### References

1. Baharloo F, Veyckemans F, Francis C, Biottlot MP, Rodenstein DO. Tracheobronchial foreign bodies: presentation and management in children and adults. *Chest*. 1999;115(5):1357–62. doi:10.1378/chest.115.5.1357.
2. Chen CH, Lai CL, Tsai TT, Lee YC, Perng RP. Foreign body aspiration into the lower airway in Chinese adults. *Chest*. 1997;112(1):129–33. doi:10.1378/chest.112.1.12.
3. Dikensoy O, Usalan C, Filiz A. Foreign body aspiration: clinical utility of flexible bronchoscopy. *Postgrad Med J*. 2002;78(921):399–403. doi:10.1136/pmj.78.921.399.
4. Halwai O, Bihani A, Sharma A, Dabholkar J. A study of clinical presentations and complications of foreign body in the bronchus-own experience. *Otolaryngol Pol*. 2015;69(1):22–8. doi:10.5604/00306657.1131145.
5. Gross SD. A Practical Treatise on Foreign Bodies in the Air Passages. Philadelphia: Blanchard and Lea; 1854. Available from: <http://resource.nlm.nih.gov/0220173>.
6. Gurpinar A, Kilic N, Dogruyol H. Foreign body aspiration in children. *Turkish Res J*. 2003;4:131–4.
7. Chatterji S, Chatterji P. The management of foreign bodies in air passages. *Anaesthesia*. 1972;27(4):390–5. doi:10.1111/j.1365-2044.1972.tb08243.x.
8. Hong SJ, Goo HW, Roh JL. Utility of spiral and cine CT scans in pediatric patients suspected of aspirating radiolucent foreign bodies. *Otolaryngol Head Neck Surg*. 2008;138(5):576–80. doi:10.1016/j.otohns.2007.12.039.
9. Afiadigwe EE, Chime EN, Obasikene G, Ezeanolue BC. Migratory Bronchial Foreign Body: Role of Serial Radiographs and Review of Literature. *International Journal of Medical Science and Clinical Invention*. 2020;7(11):5130–5. doi:10.18535/ijmsci/v7i11.11.
10. Jiaqiang S, Jingwu S, Yanming H, Qiuping L, Yinfeng W, Xianguang L, et al. Rigid bronchoscopy for inhaled pen caps in children. *J Pediatr Surg*. 2009;44(9):1708–11. doi:10.1016/j.jpedsurg.2008.11.035.
11. Kapoor R, Chandra T, Mendpara H, Gupta R, Garg S. Flexible Bronchoscopic Removal of Foreign Bodies from Airway of Children: Single Center Experience Over 12 Years. *Indian Pediatr*. 2019;56(7):560–2.

### Author biography

**Suji P S**, Senior Resident  <https://orcid.org/0000-0003-4534-3691>

**Abhishek Bhardwaj**, Assistant Professor  <https://orcid.org/0000-0002-1217-9664>

**Manu Malhotra**, Professor and Head of Department  <https://orcid.org/0000-0003-0913-6652>

**Surjalata Devi Nongthombam**, Junior Resident

**Madhu Priya**, Additional Professor

**Rachit Sood**, Senior Resident  <https://orcid.org/0000-0002-4644-1296>

**Cite this article:** Suji P S, Bhardwaj A, Malhotra M, Nongthombam SD, Priya M, Sood R. Dual migration of organic foreign body in bronchus. *IP Indian J Anat Surg Head, Neck Brain* 2022;8(1):12-14.