

Use of C-Arm in Neck- A Mandatory Tool for Locating Impacted Metallic Foreign Bodies

Sudhir Kumar^{1,*}, Sushil Kumar Aggarwal²

¹Junior Resident, ²Assistant Professor, Dept. of ENT, Institute Medical Sciences, Banaras Hindu University, Varanasi – 221005

***Corresponding Author**

E-mail: doc.sushil.pgi@gmail.com

Abstract

Penetrating foreign bodies in neck may be quite challenging to locate in edematous tissue planes and these require urgent surgical exploration. Retrieval of foreign bodies depends upon the size and location of foreign body and the surrounding anatomical structures. We are reporting an unusual case in which a scissor was stabbed into the patient's neck causing subcutaneous emphysema, hematemesis and impaction of scissor tip in the cervical vertebra. The foreign body was removed by transverse cervical approach with the help of C-arm.

Keywords: C-arm, Metallic foreign body, Neck exploration, Scissor tip.

Introduction

Penetrating injuries to head and neck region with varying objects have been reported in the literature.^{1,2,3,4,5,6,7,8} Majority of these injuries occur due to interpersonal violence, bomb blasts or road traffic accidents. Even though, there is improvement in imaging technologies and surgical methods, penetrating injuries to head and neck region are quite challenging due to the proximity of impacted foreign body (FB) to vital structures and difficulties involved in removing the foreign body.⁹ Following injury, the normal anatomy could be altered because of edema and tissue destruction, which makes the diagnosis or retrieval very difficult.⁹ Removal of embedded foreign bodies in neck can be quite challenging and frustrating because location of the impacted FB is often quite difficult. Hence, while exploring for foreign bodies in neck, patience, high index of suspicion and repeated intra-operative imaging can help us to find the foreign body in edematous tissue planes. This is even more important in cases where the impacted body is made up of different materials with varying radio sensitivity.

We are reporting an unusual case in which a scissor was stabbed into the patient's neck causing subcutaneous emphysema, hematemesis and impaction of scissor tip in the cervical vertebra. The foreign body was removed by transverse cervical approach with the help of c-arm. This case is being reported because of its rarity and to tell the advantage of using c-arm in locating metallic foreign bodies in neck.

Case Report

A 46 year old male was admitted in our emergency department with a history of stab injury with a scissor by his relatives and swelling in the neck. He had complaints of difficulty in swallowing and breathing. The patient was conscious, oriented and hemo-dynamically stable on general examination. On local examination, there was a 1cm wound over left anterior part of neck, lateral to the thyroid cartilage with mild edema present around the entry point (Fig. 1). The x-ray showed a 2 x 1cm triangular radio-opaque shadow embedded in C5 vertebra (Fig. 2). The shape of the object was corresponding well with the tip of the scissor. As the impacted object was metallic in nature, contrast enhanced computed tomography (CECT) scan of the neck was done which revealed a hyper-intense shadow of about 2x1cm size embedded into C5 cervical vertebra (Fig. 3). The foreign body was not breaching any vital structures in the neck. So, we planned for transverse cervical approach under general anaesthesia to remove the foreign body. Intra-operatively, there was lot of edema in the soft tissues and it was difficult to identify the planes. Hence, we took the help of C-arm to see the depth and trajectory of the foreign body (Fig. 4). Foreign body was localized to the under surface of pharynx impacted in the C5 vertebra after doing extensive dissection along with frequent finger palpation. The alar fascia was incised to expose the foreign body adequately which was then removed with an

allis forceps (Fig. 5). Prophylactic tracheostomy was done intraoperatively as patient had lot of subcutaneous emphysema in the neck. Patient did not have complications post-operatively and he was discharged after decannulation after 7 days.

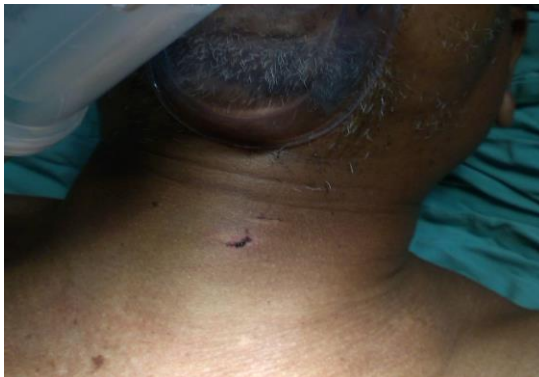

Fig. 1: Clinical picture showing entry point on left anterior part and swelling in the neck

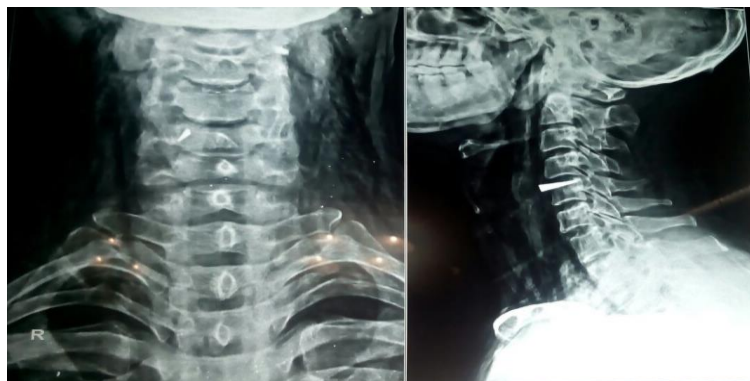

Fig. 2: X-ray (AP and lateral view) showing foreign body embedded in C5 vertebra

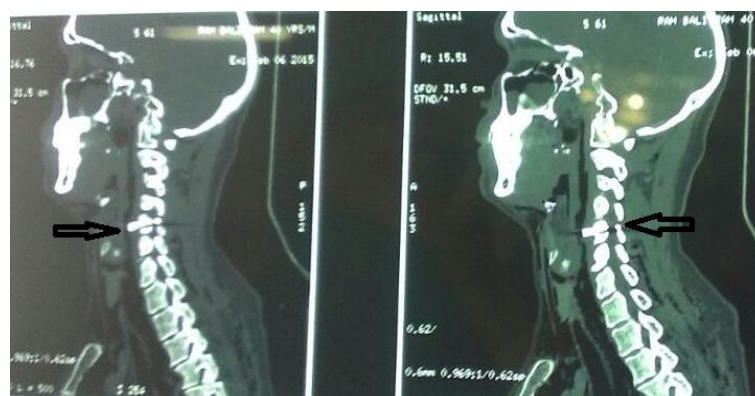


Fig. 3: Computed tomography (CT) picture showing foreign body embedded in C5 vertebra

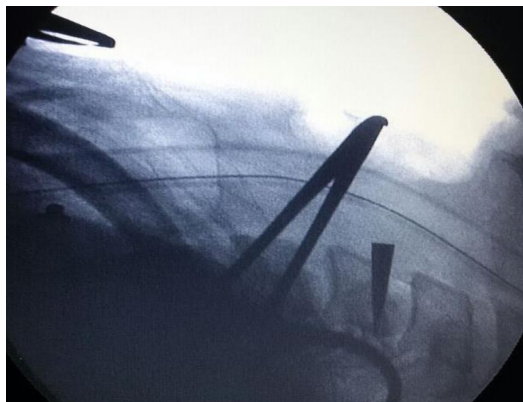


Fig. 4: C-arm picture taken intra-operatively which helped us to locate foreign body in neck

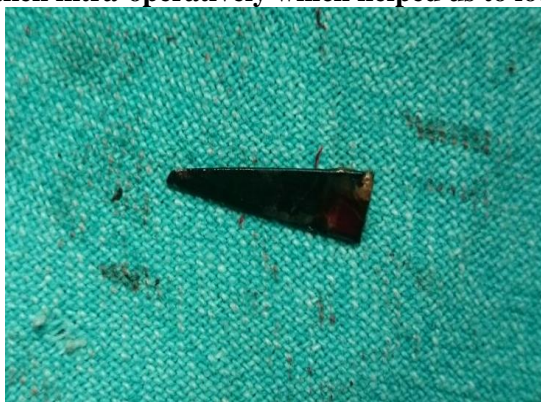


Fig. 5: Picture showing foreign body taken out after surgery

Discussion

Though soft tissue injuries to the head and neck are very common, penetrating injuries resulting in the impaction of foreign bodies are still rare and are usually secondary to a gunshot or stab wound.¹ Accidental falls leading to penetration of foreign body is another source of trauma to the neck.¹⁰ There have been reports of impacted chopsticks also.² Parapharyngeal or prevertebral space is an unusual place for lodgment of foreign bodies and in these cases the usual point of entry is the oral cavity, cheek or neck.⁹ However retention of scissor tip in the neck has not been reported till date.

The foreign body incidences are usually common in infants and young children due to their habit of mouthing and exploring everything with their mouth. In adults risk factors include alcohol influence, psychiatric illness and sheer carelessness etc.¹¹

The diagnosis of penetrating neck trauma with an associated foreign body in-situ is generally quite obvious from history and clinical examination. However, identifying a foreign body on CT scan can be very challenging at times, especially in cases where the impacted body is

very thin or where foreign body is not very clear on imaging.³

Precise localization of the foreign body is essential for complication free removal. Plain radiographs are essential at the initial assessment. When there is delay between the injury and surgical exploration, repeat films immediately prior to surgery are mandatory, to assess any further migration in the interim period.¹² Both CT and MRI have been described as useful techniques for detecting the presence of a foreign body in the soft tissues of the neck⁴ and provide sufficient information to enable location of the foreign body and determination of the relation between the foreign body and the major vessels. However, CT scans are not without their drawbacks. The soft tissues of the neck are mobile in relation to the bony and cartilaginous structures. Thus, at the time of surgery, the foreign body may not be situated exactly as where it is seen in the CT,¹³ though in our case, due to impaction, the foreign body was found at exactly the same place as was seen in CT scan. Thus, C-arm is also recommended to localize the foreign body in the neck intra-operatively when it is difficult to locate.¹²

There is currently no consensus among surgeons regarding the management of cervical foreign bodies. There are advocates for both mandatory explorations and exploration in selected cases.^{5,6} Asensio et al⁷ in their study have performed a thorough review of the literature on the subject of "mandatory exploration versus selective exploration. They found no advantage of one approach over the other. Proponents of mandatory exploration favour removal of foreign bodies at the earliest as they are known to migrate⁸ and can cause secondary complications such as haemorrhage or hematoma, infection and neurovascular compromise. In our case, the part of scissor left inside acted as a portal of entry for contaminants/infection to deeper tissues.

Conclusion

Preoperative imaging is very important in deciding upon the surgical approach for the retrieval of impacted foreign bodies and CT and MRI are equally efficient for it. In spite of having both CT and MRI, it is also advantageous to have the C-arm intra-operatively for metallic foreign body detection. Thus, exploration of foreign bodies in neck requires patience, high index of suspicion and repeated intra-operative imaging to find impacted foreign bodies in edematous tissue planes.

Conflict of Interest: None

Source of Support: Nil

References

1. Wakisaka H, Takahashi H, Ugumori T, Motoyoshi K, Takagi D. A case of a wooden foreign body penetrating the oral cavity and reaching the posterior neck. *Inj Extra* 2010;41:92-6.
2. Park SH, Cho KH, Shin YS, Kim SH, Ahn YH, Cho KG, et al. Penetrating craniofacial injuries in children with wooden and metal chopsticks. *Paed Neurosurg* 2006;42:138-146.
3. Hersman G, Barker P, Bowley DM, Boffard KD. The management of penetrating neck injuries. *Int Surg* 2001;86:82-9.
4. Shankar L, Khan A, Cheung G. *Head and Neck Imaging*. 1st ed. New York: McGraw Hill; 1998. p. 15-36.
5. Khan MS, Kirkland PM, Kumar R. Migrating foreign body in the tracheobronchial tree: An unusual case of firework penetrating neck injury. *J Laryngol Otol* 2002;116:148-9.
6. Obeid FN, Haddad GS, Horst HM, Bivins BA. A critical reappraisal of a mandatory exploration policy for penetrating wounds of the neck. *Surg Gynecol Obstet* 1985;160:517-22. [PUBMED]
7. Asensio JA, Valenziano CP, Falcone RE, Grosh JD. Management of penetrating neck injuries. The controversy surrounding zone II injuries. *Surg Clin North Am* 1991;71:267-96.
8. Landis BN, Giger R. An unusual foreign body migrating through time and tissues. *Head Face Med* 2006; 2: 30.
9. Reiss M, Reiss G, Pilling E. Gunshot injuries in the head-neck area-basic principles, diagnosis and management. *Schweiz Rundsch Med Prax* 1998;87:832-8.
10. Oropharyngeal foreign body. Mishra A, Shukia GK, Bhatia Naresh. *J Laryngol Otol* June 2000;114:469-470.
11. Robert H Stround, Ronald W Deskin; Foreign bodies in the aero digestive tract. Available from <http://otohns.net/default.asp?id=14063>.
12. Khan MS, Kirkland PM, Kumar R; Migrating foreign body in the tracheobronchial tree. An unusual case of firework penetrating neck injury. *J Laryngol Otol.*, 2002;116(2):148-149.
13. Chung SM, Kim HS, Park EH. Migrating pharyngeal foreign bodies: A series of four cases of saw-toothed fish bones. *Eur Arch Otorhinolaryngol* 2008;265(9):1125-1129.