

Content available at: <https://www.ipinnovative.com/open-access-journals>

IP Indian Journal of Anatomy and Surgery of Head, Neck and Brain

Journal homepage: <https://www.ijashnb.org/>

Editorial

Short analysis & awareness on tongue & its common clinical disorder

Sanhati Das^{1,*}, Mayukh Pandit²

¹Dept. of Dental Surgery, Nyarkotey University College of Holistic Medicine and Technology, Ghana, West Africa

²Dept. of Anatomy, Nyarkotey University College of Holistic Medicine and Technology, Ghana, West Africa



ARTICLE INFO

Article history:

Received 20-01-2023

Accepted 27-01-2023

Available online 20-02-2023

This is an Open Access (OA) journal, and articles are distributed under the terms of the [Creative Commons Attribution-NonCommercial-ShareAlike 4.0 License](https://creativecommons.org/licenses/by-nc-sa/4.0/), which allows others to remix, tweak, and build upon the work non-commercially, as long as appropriate credit is given and the new creations are licensed under the identical terms.

For reprints contact: reprint@ipinnovative.com

1. Background

Our tongue is very vital organ responsible for chewing and swallowing food present in oral cavity which is covered with mucosa & number of taste buds responsible for communicating the sense of taste to the brain. A healthy tongue should be idealized as pink in color with papillae over its surface. Whereas unhealthy tongue is characterized by the presence of presence of large patches of white, brown, black or any other colors indicating a specific disease of our body. In our day to day modern practice we often have encountered various oral lesions most commonly including leukoplakia, oral thrush, oral lichen planus, geographic tongue and hairy tongue.

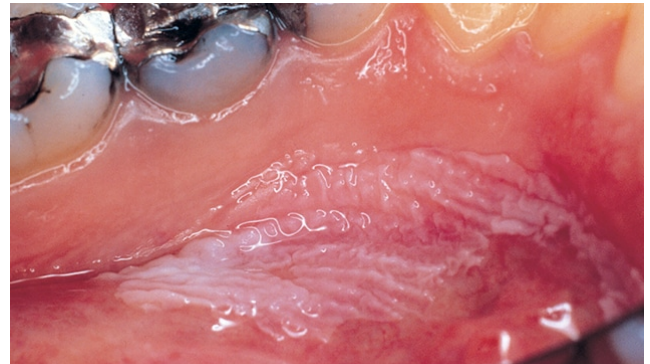
2. Clinical Disorders of Tongue

2.1. Leukoplakia

Leukoplakia also know by the name as Smoker's Keratosis which is mouth condition involving thickened white or gray patches especially on tongue, cheeks & on the floor of mouth. We further have studied and inferred that the most anatomical common sites affected are the labial mucosa, buccal mucosa, and the alveolar mucosa. It also could be stated that although any mucosal surface in the mouth may be involved by leukoplakia.

* Corresponding author.

E-mail address: sanhatidas7@gmail.com (S. Das).

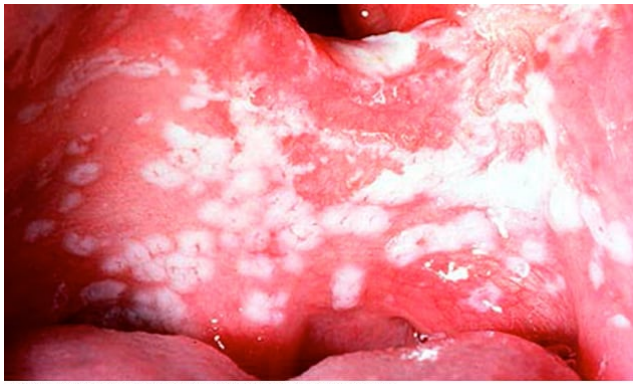

© MAYO FOUNDATION FOR MEDICAL EDUCATION AND RESEARCH. ALL RIGHTS RESERVED.

Fig. 1: Leukoplakia, Source credits:- <https://www.mayoclinic.org/diseases-conditions/leukoplakia/symptoms-causes/syc-20354405>

3. Oral Thrush

Oral Thrush commonly known by the name as Oral Candidiasis which is a mouth infection caused by yeast candida albicans. We have encountered in our practice that the most common anatomical site or oral thrush includes white and yellow patches on buccal mucosa, tongue & gingiva. It could also cause burning sensation & dysphagia in patients suffering from it.

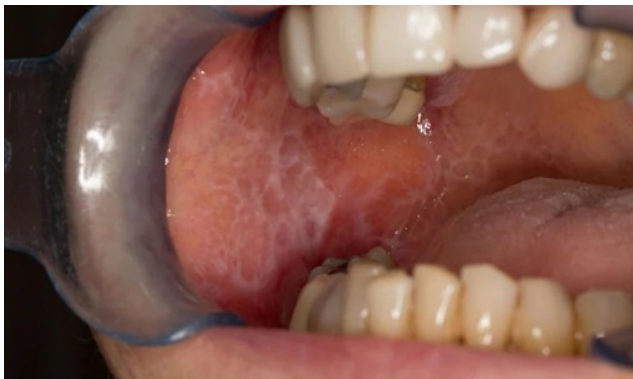

© MAYO FOUNDATION FOR MEDICAL EDUCATION AND RESEARCH. ALL RIGHTS RESERVED.

Fig. 2: Oral thrush, Source Credits:- <https://www.mayoclinic.org/diseases-conditions/oral-thrush/symptoms-causes/syc-20353533#dialogId49632276>

3.1. Oral Lichen Planus

Oral Lichen Planus also known by the name as Lichen rubber planus, an oral condition an inflammatory condition which is a white lesion with lacy and thread like appearance. We have analyzed that oral lichen planus is most commonly observed on the interior surface of the cheek, the most common anatomical site.

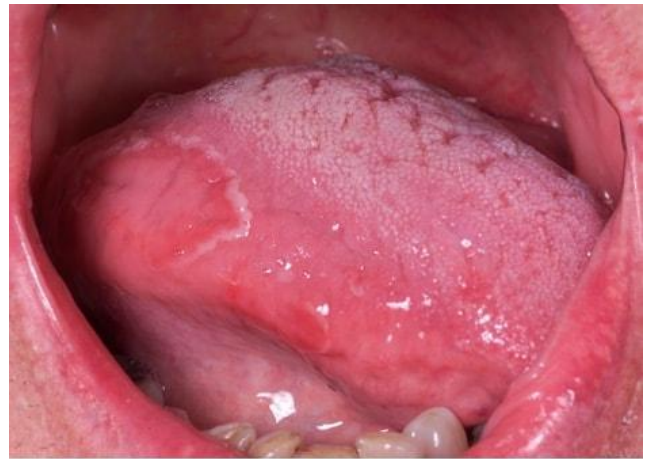

© MAYO FOUNDATION FOR MEDICAL EDUCATION AND RESEARCH. ALL RIGHTS RESERVED.

Fig. 3: Oral lichen planus, Source Credits:- <https://www.mayoclinic.org/diseases-conditions/oral-lichen-planus/symptoms-causes/syc-20350869#dialogId6380226>

3.2. Geographic Tongue

Geographic Tongue also known by the name as Benign Migratory Glossitis which forms map-like pattern to appear on the tongue. This condition is inflammatory but known as harmless condition occurring in the surface of tongue. The lesions of this disorder often heal in particular area and migrates to another area of our tongue. In our practice we have encountered our patients usually have no symptoms but in some cases they have complaint of burning or stinging sensation on their tongue.

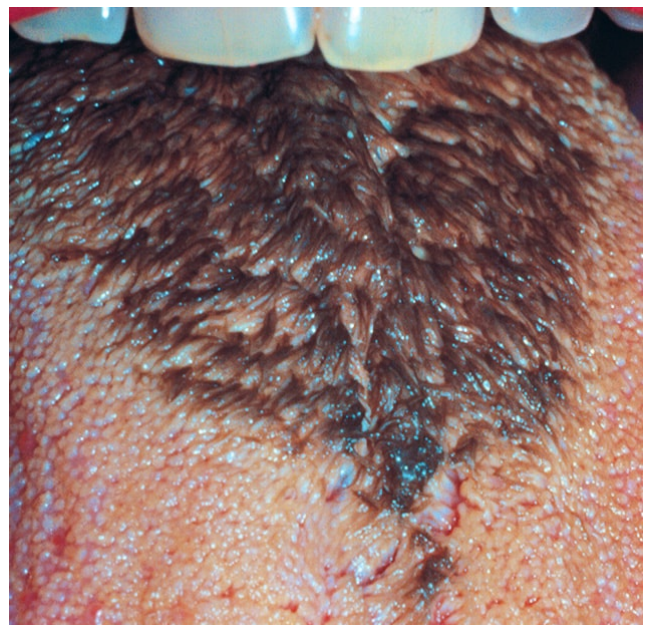


© MAYO FOUNDATION FOR MEDICAL EDUCATION AND RESEARCH. ALL RIGHTS RESERVED.

Fig. 4: Geographic tongue, Source credits:- <https://www.mayoclinic.org/diseases-conditions/geographic-tongue/symptoms-causes/syc-20354396>

4. Hairy Tongue

Hairy Tongue also known by the name as lingua villosa nigra which is a harmless and fairly common condition in which colour of our tongue appears to be black and hairy usually caused by too much bacteria or yeast growth in our oral cavity. The patient with poor oral hygiene usually experience this condition along with metallic taste and halitosis.



© MAYO FOUNDATION FOR MEDICAL EDUCATION AND RESEARCH. ALL RIGHTS RESERVED.

Fig. 5: Black hairy tongue, Source Credits:- <https://www.mayoclinic.org/diseases-conditions/black-hairy-tongue/symptoms-causes/syc-20356077#dialogId41709881>

5. Conclusion

We hereby would like to conclude our short editorial by enlightening the importance of awareness on oral health. Oral health awareness also emphasis on the hygiene of tongue which could have serious implications on health of one's well being.

We would also like to provide referral advice that patients with a tongue lesion of unclear etiology can be referred to an dentist, oral and maxillofacial surgeon, head and neck surgeon, or someone who is experienced in oral pathology for critical diagnosis and treatment.

6. Conflict of Interest

None.

Author biography

Sanhati Das, Dental Surgeon

Mayukh Pandit, HOD Anatomy

Cite this article: Das S, Pandit M. Short analysis & awareness on tongue & its common clinical disorder. *IP Indian J Anat Surg Head, Neck Brain* 2022;8(4):112-114.