

Content available at: <https://www.ipinnovative.com/open-access-journals>

IP Indian Journal of Anatomy and Surgery of Head, Neck and Brain

Journal homepage: <https://www.ijashnb.org/>

## Case Report

# Plexiform neurofibromatosis of face – Recent advances in the management

Kaushik Bhattacharya<sup>1,\*</sup>, Neela Bhattacharya<sup>2</sup>, Aditya Shikar Bhattacharya<sup>3</sup>

<sup>1</sup>Dept. of Surgery, Shristi Cosmetic & General Surgery Clinic, Siliguri, West Bengal, India

<sup>2</sup>Dept. of Plastic Surgery, Anandaloke Multispeciality Hospital, Siliguri, West Bengal, India

<sup>3</sup>Stanley Medical College, Chennai, Tamil Nadu, India



### ARTICLE INFO

#### Article history:

Received 03-12-2022

Accepted 28-12-2022

Available online 20-02-2023

#### Keywords:

Plexiform Neurofibromatosis

Selumetinib

Sclerotherapy

Laser

### ABSTRACT

Plexiform neurofibromas (PNs) are benign tumors that grow in the nerves of people with neurofibromatosis type 1 (NF1), a genetic disorder that affects the development and growth of nerve cell tumors. PNs can occur anywhere in the body but are most commonly found in the skin, nerves, and bones. They can cause disfigurement and functional impairment, and may also increase the risk of malignant transformation. Treatment options include surgery, radiation therapy, and medications to manage symptoms.

This is an Open Access (OA) journal, and articles are distributed under the terms of the [Creative Commons Attribution-NonCommercial-ShareAlike 4.0 License](https://creativecommons.org/licenses/by-nc-sa/4.0/), which allows others to remix, tweak, and build upon the work non-commercially, as long as appropriate credit is given and the new creations are licensed under the identical terms.

For reprints contact: [reprint@ipinnovative.com](mailto:reprint@ipinnovative.com)

## 1. Introduction

Plexiform Neurofibromatosis (PNs) are a common manifestation of the genetic disorder neurofibromatosis type 1 (NF1). Known classically as a benign nerve sheath tumor, they often cause significant morbidity, with treatment options largely limited to surgery only. However, in the past two decades, the Mitogen-activated protein kinase (MEK) inhibitor selumetinib is showing promising treatment of PNs.<sup>1</sup> The incidence of Neurofibromatosis (NF 1) type 1 (von Recklinghausen NF) occurs in 1 of 4000 births and is inherited in an autosomal dominant pattern with variable penetrance. Spontaneous mutation occurs in 50% of cases. Genetically, the disease results from a defect in a tumor suppressor gene on chromosome 17, predisposing the patient to benign and malignant tumors.

## 2. Surgical Management

Surgeons were reluctant to perform surgery on PNs as it was noted that 54% recur within a 10-year period, with the

greatest risk of recurrence found in lesions involving the head and neck and in children treated when younger than 10 years.<sup>2</sup> A considerable controversy persists regarding the indications and timing of surgical interventions for PNs of the head and neck. Recurrence is more if the surgical resection had been incomplete. Moreover, surgery cannot achieve complete tumor removal and carries a high risk of postoperative deficits and morbidity as PNs can be highly vascular, involve multiple nerve fascicles, and become large enough to cause significant deformity with pain and functional changes. Another challenge for surgical intervention in PNs is the lack of a well-defined capsule and a mesh of interwoven spindle cells, collagen fibres and axons that diffusely infiltrate the involved nerve making it extremely difficult to get a well-defined surgical plane of dissection.<sup>3</sup> There has been a case report of a giant plexiform neurofibroma of the lower back and buttock who underwent pre-operative embolization and intraoperative use of a linear cutting stapler system to assist with haemostasis during the surgical resection.<sup>4</sup> A pre-operative biopsy may cause inflammation and scarring within the lesion, resulting in adhesion of the tumor to the

\* Corresponding author.

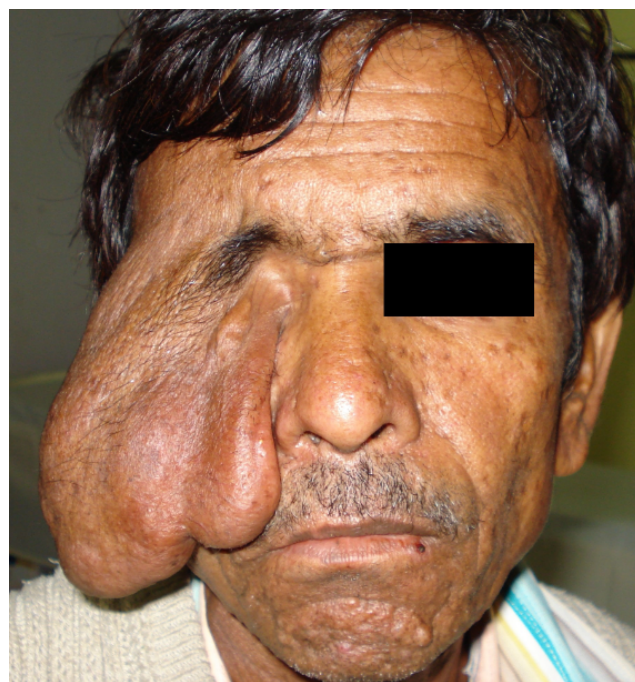E-mail address: [kbhattacharya10@yahoo.com](mailto:kbhattacharya10@yahoo.com) (K. Bhattacharya).

fascicles, so there is a vexing problem even there. However, PNs in two specific locations, orbital–periorbital plexiform neurofibroma (OPPN) and paraspinal PN, deserve special surgical attention.

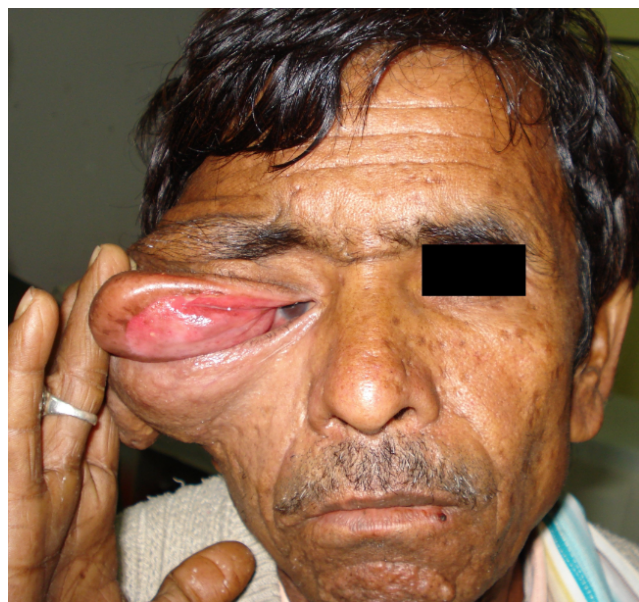In a gist, the indications for surgical intervention in PNs of the head and neck are: 1) to exclude malignant transformation in a rapidly growing mass; 2) to keep the airway patent 3) to alleviate compressive symptoms of neural structures, particularly in paraspinal PNs; 4) to achieve aesthetic results, particularly in individuals with trigeminal lesions and the risk of facial nerve palsy.<sup>5</sup>

### 2.1. Non-surgical management

Due to surgical difficulty and recurrence post-surgery many non-surgical interventions were tried for non-cutaneous PNSTs including cryoablation, radiosurgery, microwave ablation, sclerotherapy, laser, and radiofrequency ablation. The indication for the use of chemotherapy and radiotherapy is limited by high toxicity rates in NF1 patients and is not recommended. [Figures 1 and 2]



**Fig. 2:** – Plexiform Neurofibromatosis involving the right eye.



**Fig. 1:** Plexiform neurofibromatosis of right trigeminal nerve

### 2.2. Medical management with mitogen-activated protein kinase inhibitors (MEKi )

Mitogen-activated protein kinase (MEK) is a key protein in the signal transduction pathway for many growth factor receptors that supply growth signals to the tumor cells. Selumetinib is an inhibitor of MEK (MEKi), which can mediate anti-tumor effects in PNs by inhibiting Ras signaling. The recent regulatory approvals (including the United States, Europe, and Brazil) of the MEK inhibitor selumetinib for children with NF1 and symptomatic,

inoperable PNs have changed the clinical landscape in its management. The phase 1 and 2 clinical trials with the MEKi selumetinib for children with inoperable symptomatic PNs resulted in a partial response in 71% and 74% of patients, respectively.<sup>1</sup> It was also seen that the patients also experienced less pain and improved function and quality of life while on treatment which was significant. Thus, selumetinib became the first medical drug of choice to be approved by the FDA for the management of PNs in children. Several trials have established that Selumetinib exhibits impressive antitumor activity and sustained clinical benefit in patients lacking other viable treatment options. In a case series observational study on 19 patients who underwent treatment with selumetinib in head and neck PNs (31.6%), chest (26.3%), and pelvis (21%) with the most important comorbidities being disfigurement (47.4%) and pain (26.3%), in a mean follow-up time of 223 days, it was concluded that except in one case, all the rest had sustained clinical improvement, mainly in the first 60-90 days of treatment.<sup>6</sup> Finally, in a study from India, the verdict given was that selumetinib can produce sustained shrinkage in most patients with NF1 and symptomatic plexiform neurofibroma and provide meaningful benefit in functional ability, acceptable safety profile and absence of cumulative toxic effects, with more robust evidence in children than previous studies.<sup>7</sup> The estimated progression-free survival at 3 years was 84%.<sup>8</sup>

### 3. Conclusion

Plexiform Neurofibromatosis can grow to grotesque sizes, have painful and restrictive symptoms and be a challenge to treat surgically. The mitogen-activated Protein Kinase inhibitor Selumetinib is a beacon of hope as it seems to be effective in reducing progression, mitigating symptoms, and safe enough to use long-term in children.

### 4. Source of Funding

None.

### 5. Conflict of Interest

None.


### References

1. Fisher MJ, Blakeley JO, Weiss BD. Management of neurofibromatosis type 1-associated plexiform neurofibromas. *Neuro Oncol.* 2022;24(11):1827–44. doi:10.1093/neuonc/noac146.
2. Needle M, Cnaan A, Dattilo J, Chatten J, Phillips PC, Shochat S, et al. Prognostic signs in the surgical management of plexiform neurofibroma: the Children's Hospital of Philadelphia experience, 1974-1994. *J Pediatr.* 1997;131(5):678–82. doi:10.1016/s0022-3476(97)70092-1.
3. Nicoli TK, Saat R, Tarkkanen J, Kinnunen I, Mäkitie AA, Jero J, et al. Challenging Management of Plexiform Schwannoma and Plexiform Neurofibroma. *J Craniofac Surg.* 2022;33(3):803–8. doi:10.1097/SCS.00000000000008381.
4. Vélez R, Barrera-Ochoa S, Barastegui D, Pérez-Lafuente M, Romagosa C, Pérez M, et al. Multidisciplinary management of a giant plexiform neurofibroma by double sequential preoperative embolization and surgical resection. *Case Rep Neurol Med.* 2013;p. 987623. doi:10.1155/2013/987623.
5. Marjanska A, Galazka P, Wysocki M, Styczynski J. New Frontiers in Therapy of Peripheral Nerve Sheath Tumors in Patients with Neurofibromatosis Type 1: Latest Evidence and Clinical Implications. *Anticancer Res.* 2020;40(4):1817–31.
6. Santo E, Passos V, Nzwallo J, Carvalho H, Santos I, Martins F, et al. Selumetinib for plexiform neurofibromas in neurofibromatosis type 1: a single-institution experience. *J Neurooncol.* 2020;147(2):459–63. doi:10.1007/s11060-020-03443-6.
7. Sharawat IK, Panda PK, Sihag RK, Panda P, Dawman L. Efficacy and safety profile of selumetinib in symptomatic inoperable plexiform neurofibromas. *J Neurosurg Sci.* 2022;66(6):501–10. doi:10.23736/S0390-5616.21.05528-4.
8. Anderson MK, Johnson M, Thornburg L, Halford Z. A Review of Selumetinib in the Treatment of Neurofibromatosis Type 1-Related Plexiform Neurofibromas. *Ann Pharmacother.* 2021;56(6):716–26. doi:10.1177/10600280211046298.

### Author biography

**Kaushik Bhattacharya**, Consultant  <https://orcid.org/0000-0002-4825-9148>

**Neela Bhattacharya**, Consultant  <https://orcid.org/0000-0002-9414-1503>

**Aditya Shikar Bhattacharya**, Student  <https://orcid.org/0000-0002-5241-5318>

**Cite this article:** Bhattacharya K, Bhattacharya N, Bhattacharya AS. Plexiform neurofibromatosis of face – Recent advances in the management. *IP Indian J Anat Surg Head, Neck Brain* 2022;8(4):139-141.