

Content available at: <https://www.ipinnovative.com/open-access-journals>

IP Indian Journal of Anatomy and Surgery of Head, Neck and Brain

Journal homepage: <https://www.ijashnb.org/>

Original Research Article

Morphological variations of vermiform appendix: A cadaveric study

Mohini M. Joshi^{1,*}, Sandeep V. Pakhale²¹Dept. of Anatomy, Rural Medical College, Pravara Institute of Medical Sciences, Loni, Maharashtra, India²Dept. of Anatomy, BVP Rural Medical College, Pravara Institute of Medical Sciences, Loni, Maharashtra, India

ARTICLE INFO

Article history:

Received 30-01-2023

Accepted 25-02-2023

Available online 20-05-2023

Keywords:

Appendix
Morphology
Variations

ABSTRACT

Background and Objective: A common and deadly cause of sudden abdominal discomfort is acute appendicitis. The surgeons frequently had trouble locating the vermiform appendix in its regular location. For an effective therapy, a thorough analysis of the vermiform appendix's various locations is required. The objective of this study is to investigate and compile extensive anatomical data on the location variation of the vermiform appendix in the cadavers of western Indians. The structure's morphometry was determined.

Materials and Methods: The study of appendix was carried out on 25 cadavers available in the department of anatomy. Metrical parameters such as length, diameter and distance of appendicular orifice from ileum were measured. The different positions of appendix in and the variations of the mesoappendix were noted. Mean and standard deviations were calculated.

Results: Length of appendix was 5.47 ± 1.59 , diameter at base was 6.85 ± 1.82 , diameter at tip was 3.94 ± 1.11 , distance of appendicular orifice below ileum was 1.14 ± 0.85 and Distance of appendicular orifice below ileum inside was 2.19 ± 0.78 . The most common position of mesoappendix was mesoappendix reaches the tip 37 (74%) followed by mesoappendix does not reaching the tip was 13 (26%).

Conclusion: The most common position was retrocaecal 20(40%) followed by pelvic 15 (30%) least common was midinguinal. From various positions of vermiform appendix we can understand the possible outcome of the appendicitis specifically location of site of pain.

This is an Open Access (OA) journal, and articles are distributed under the terms of the [Creative Commons Attribution-NonCommercial-ShareAlike 4.0 License](https://creativecommons.org/licenses/by-nc-sa/4.0/), which allows others to remix, tweak, and build upon the work non-commercially, as long as appropriate credit is given and the new creations are licensed under the identical terms.

For reprints contact: reprint@ipinnovative.com

1. Introduction

The posteromedial caecal wall, just below the end of the ileum, gives rise to the vermiform appendix, a small vermiform (worm-like) structure.¹ The most frequent factor leading to emergency laparotomies has been identified as its inflammation. The primary role of the vermiform appendix, which also performs other gastrointestinal tract-related tasks, is immunological. Vermiform appendix's tonsil-like behaviour has also been claimed. Similar to how the tonsils protect the upper digestive system from pathogens, the vermiform appendix protects the small

intestine from bacteria found in the large intestine.² An organ with changeable location is the vermiform appendix. The location of the vermiform appendix is not governed by any set rules, however it is believed that it is strongly tied to the caecum's development.³ Recognizing the vermiform appendix variation; scientists have been studying its position as early as 1933.⁴ The clinical manifestation of appendicitis is notoriously unpredictable due to variations in the location of the appendix, the patient's age, and the level of inflammation.⁵ Determining the appendix's typical position is crucial since it might create symptoms and signs specific to its position during appendicitis, which can cause it to resemble other conditions.⁶ We discovered that there is a dearth of material on this significant structure in terms of

* Corresponding author.

E-mail address: atharvamohini@gmail.com (M. M. Joshi).

age while reading the literature. In light of this context, the current work is an effort to investigate the location and morphometry of the vermiform appendix in cadavers available in the anatomy department.

2. Aim

The aim of present study is to investigate certain morphological features of vermiform appendix in cadavers.

3. Objectives

To measure the different parameters of appendix such as length, diameter and distance of appendicular orifice from ileum.

To note the different positions of appendix in cadavers.

To see the variations of the mesoappendix.

To correlate the significance of these findings with clinical finding

4. Material and Methods Study

4.1. Design

Descriptive, Cross sectional study

4.2. Study setting

Pravara Institute of Medical Sciences (PIMS), Loni.

4.3. Sample size

50 CADAVERS available in the department of Anatomy will be utilized for study purpose.

In each specimen the appendix was exposed and its position, length and diameter and the extent of mesoappendix was noted.

How to measure the vermiform appendix's length, Using a measuring tape with a centimetre graduation, the length of the vermiform appendix was determined by measuring the distance from the base to the tip of the appendix. Where the taenia coli on the ascending colon and caecum merge is where the base of the appendix was found to be. The appendix serves as a point of reference for the anterior caecal taenia coli, which is typically identifiable.⁷ The findings of present work will be correlated with clinical findings in the light of available literature.

4.4. Exclusion criteria

Appendix with any pathological abnormalities such as inflammation, perforation, gangrene and those associated with congenital anomalies of gastrointestinal tract such as subhepatic caecum, mobile caecum and situs inversus etc. will not be taken into consideration.

4.5. Inclusion criteria

Cadaveric appendix in good state will be utilized for study.

4.6. Statistical analysis

Data obtained in this work will be entered into Microsoft Excel 2007. The data will be analyzed and tabulated using the software GraphPad Instat. For each of the parameters, the mean, standard deviation (S.D.) and range (minimum value-maximum value) will be calculated.

5. Results

Table 1: Different parameters of appendix

Type of measurements	Mean	Range	Mean \pm S.D
Length of appendix	5.47cm	2.6-10 cm	5.47 \pm 1.59
Diameter at base	6.85 mm	1.5-10 mm	6.85 \pm 1.82
Diameter at tip	3.94 mm	2-6mm	3.94 \pm 1.11
Distance of appendicular orifice below ileum outside	1.14 cm	0.3-5.2 cm	1.14 \pm 0.85
Distance of appendicular orifice below ileum inside	2.19 cm	0.9-3.8 cm	2.19 \pm 0.78

It is evident from table no I Length of appendix was 5.47 \pm 1.59, diameter at base was 6.85 \pm 1.82, diameter at tip was 3.94 \pm 1.11, distance of appendicular orifice below ileum was 1.14 \pm 0.85 and Distance of appendicular orifice below ileum inside was 2.19 \pm 0.78.

Table 2: Different positions of appendix

Positions	Number	Percentage
Retrocaecal	20	40%
Pelvic	15	30%
Paracolic	4	8%
Splenic (postileal)	4	8%
Promonteric	4	8%
Midinguinal	3	6%

It is evident from this table that the most common position was retrocaecal 20(40%) followed by pelvic 15 (30%) least common was midinguinal.

It is evident from present study the most common position of mesoappendix was mesoappendix reaches the tip 37 (74%) followed by mesoappendix does not reaching the tip was 13 (26%)



Fig. 1: Showing retrocaecal appendix

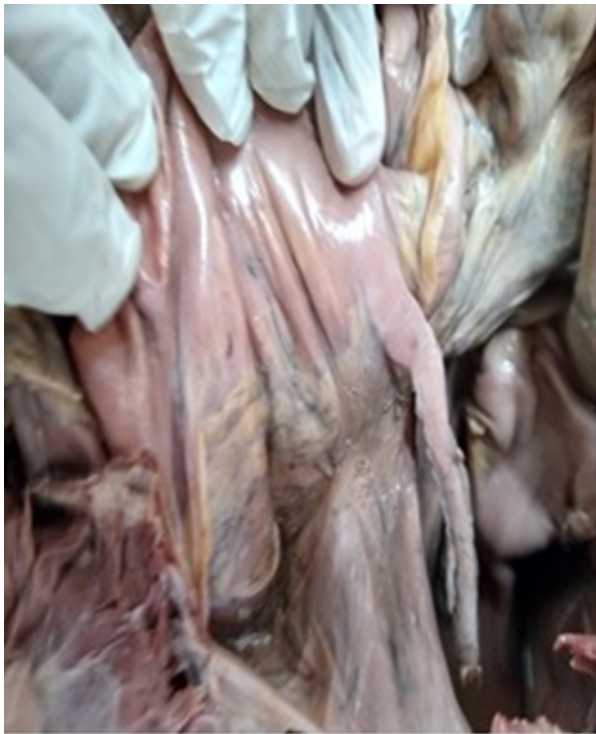

Fig. 2: Showing pelvic appendix

Table 3: Different positions of Mesoappendix

Positions of Mesoappendix	Number	Percentage
Mesoappendix reaches the tip	37	74%
Mesoappendix does not reach the tip	13	26%

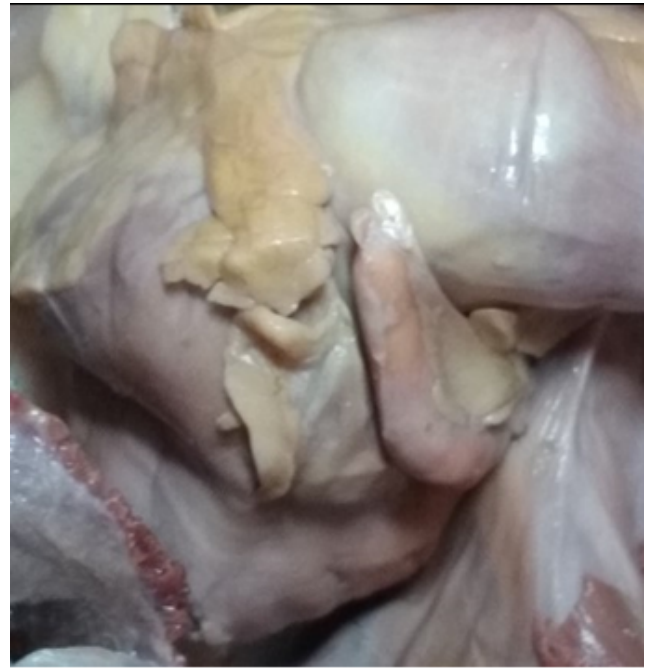

Fig. 3: Showing postileal appendix

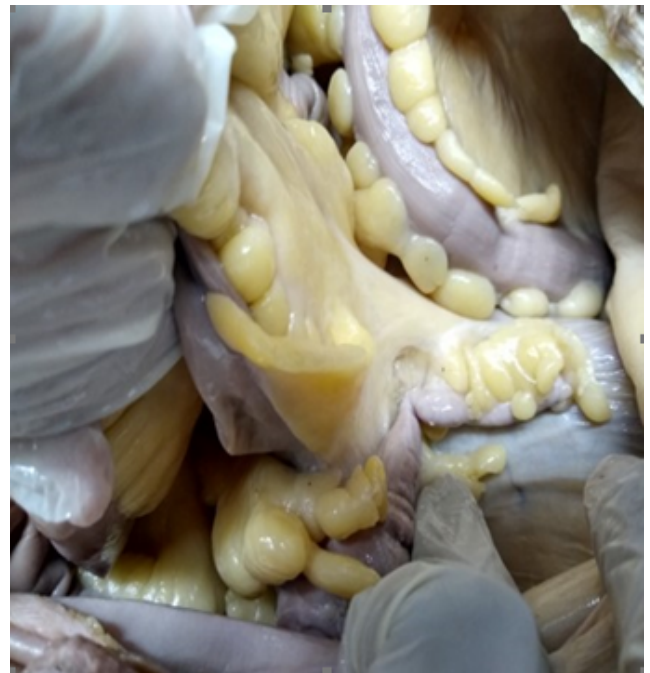

Fig. 4: Showing promonteric appendix

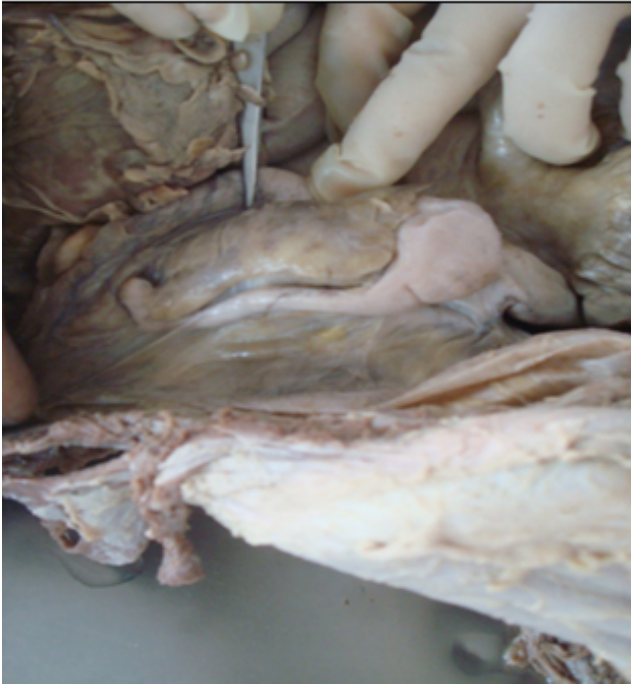

Fig. 5: Showing paracolic appendix

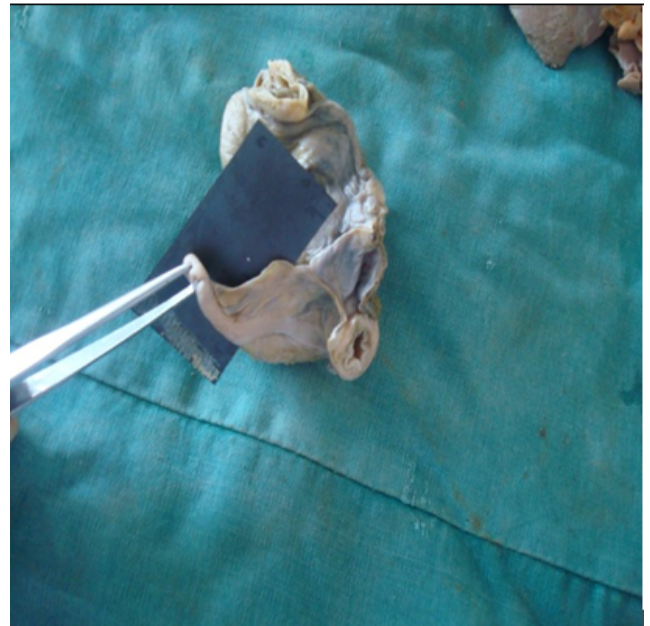

Fig. 7: Showing mesoappendix not reaching the tip

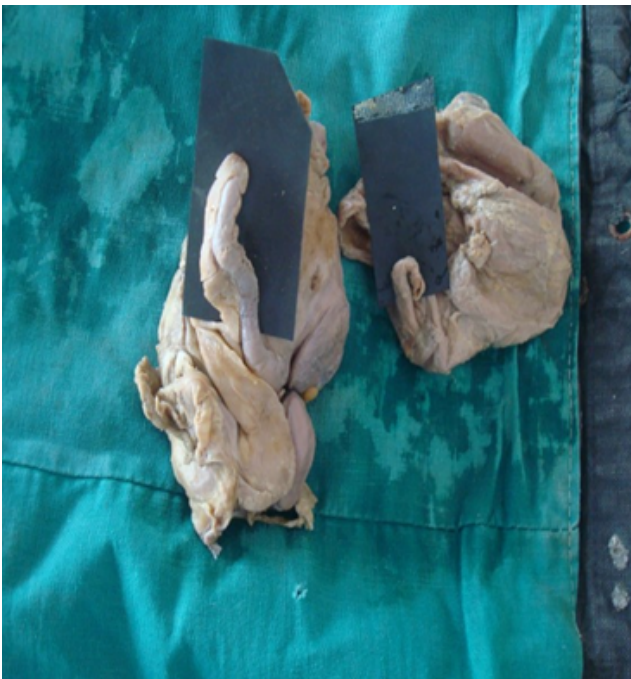

Fig. 6: Mesoappendix reaching the tip

6. Discussion

Most people think of the vermiform appendix as a vestigial organ, and the only reason it's important in surgery is because of its predisposition for inflammation, which causes the clinical illness known as acute appendicitis. The most frequent cause of "acute abdomen" in young teenagers is acute appendicitis, and an appendectomy is frequently the first major procedure carried out by a surgeon-in-training. The clinical presentation of appendicitis is notoriously unpredictable due to variations in the position of the appendix, the patient's age, and the level of inflammation.^{8–10} Misdiagnosis rates range from 10% to 33% depending on the age group.¹¹ The diagnosis of appendicitis remains primarily clinical and requires a combination of observations, clinical judgement, and surgical sense despite tremendous breakthroughs in current radiography imaging and diagnostic laboratory studies.

Paul et al studied Sixty (60) human post mortem vermiform appendix, age ranging from 0 to 65 years. Length of vermiform appendix decreases gradually with increasing age and was highly significant⁷ ($P < 0.001$) when compared between the groups.¹²

Golalipour, M. J et al observed The average length of appendix was 6.61cms in males and 6.06 cms in females. Pelvic position was the predominant position (in 33.3%) followed by retrocaecal in 32.4%, preileal in 18.8% and subcaecal in 12.8% respectively. In 65.8% of cases, the mesoappendix failed to reach appendicular tip. Retrocaecal and pelvic positions were the most common position in Turkman and native Fars races, respectively.¹³

Arindom et al carried out study on 25 cadavers where^{he} found length of appendix was more in male cadavers than female.¹⁴ The length of appendix was 6.3 ± 2.08 SD close to our study. In present study the length of appendix was 5.47 ± 1.59 (Table 1) which is close to Gopalipour, M. J et al.¹³ Syed et al.¹⁵ found adult male length of appendix was 7.72 cm and adult female length of appendix it was 6.93 cm which is similar to our study.

In present study diameter at base was 6.85 ± 1.82 , diameter at tip was 3.94 ± 1.11 , distance of appendicular orifice below ileum was 1.14 ± 0.85 and Distance of appendicular orifice below ileum inside was 2.19 ± 0.78 these measurements could not be compared with other studies as we did not come across any reference with these measurements.

In present study the most common position was retrocaecal 20(40%) followed by pelvic 15 (30%) least common was midinguinal which was similar to Arindom et al^{14,15} Retrocaecal position was common in Syed et al study and least common was preileal and postileal. Retrocaecal was similar to our study. We have not observed postileal position in our study. Ehab I. El-Amin et al¹⁶ appendix was found in the retrocaecal position (60%), which is the normal developmental position of the appendix, followed by pelvis position (35.0%), and the pre-ileal position (1.7%).

In present study the most common position of mesoappendix was mesoappendix reaches the tip 37 (74%) followed by mesoappendix does not reaching the tip was 13 (26%). Arindom et al¹⁴ found complete in four cases and in 21 cases it is incomplete which is reverse of our cases. Syed et al observed in 17 cases it reached the tip of appendix and in 33 cases it failed to reach the tip of appendix.

7. Conclusion

This study provide gross anatomical information for the surgeons and to contribute to the medical world for updating the data. Having standard data on the vermiform appendix is useful for clinicians as well as anthropologists. The findings of the present study can provide information about morphologic variations of the appendix in western Indian population. However, further studies with a larger sample size are required to make better decision.

8. Source of Funding

None.


9. Conflict of Interest

The authors declare no conflict of interest.

References

1. Standring S, Anatomy G. The Anatomical Basis of Clinical Practice. 42nd ed. Philadelphia: Churchill Livingstone; Elsevier; 2008. p. 1142–3.
2. Glover JW. The human vermiform appendix. *TJ Arch.* 1988;3(1):31–9.
3. Moore KL, Dalley AF. Clinically oriented anatomy. 4th ed. and others, editor; 1999. p. 350–4.
4. Wakeley CP. The position of the vermiform appendix as ascertained by analysis of 10,000 cases. *J Anat.* 1933;67:277–83.
5. Ohmann C, Young Q, Frank C. Diagnostic scores for acute appendicitis. Abdominal pain Group. *Eu J Surg.* 2002;16:273–81.
6. Sabiston DC, and CT. Sabiston's textbook of surgery, the biological basis of modern surgical practice. W.B. Saunders Company. Philadelphia; 2001. p. 918.
7. Borley NR, Vermiform, Standring S, Ellis H, Healy JC, Johnson D. Gray's anatomy: the anatomical basis of clinical practice. Edinburgh: Elsevier Churchill Livingstone; 2005. p. 1189–90.
8. Ronan P, Connell. In Bailey and Love's Short Practice of Surgery. RC R, NS W, CJ B, editors. London, UK: Arnold Publishers; 2000. p. 1076–82.
9. Rosemary A, Kozar JJ, Roslyn. The Appendix. In: Principles of Surgery. 10th ed. Seymour I Schwartz: McGraw-Hill Health Profession Division; 1999. p. 1383–94.
10. Condon RE. Sabiston's textbook of surgery, the biological basis of modern surgical practice. in: Appendix. 10th ed. and others, editor; 1986. p. 967–82.
11. Ohmann C, Young Q, Frank C. Diagnostic scores for acute appendicitis. Abdominal pain Group. *Eu J Surg.* 2002;161(4):273–81.
12. Paul UK, Naushaba H, Alam MJ. Length of Vermiform Appendix: A Postmortem Study. *Bangladesh J Anat.* 2011;9(1):10–2.
13. Gopalipour MJ, Arya B, Azarhoosh, Jahanshahi M. Anatomical Variations Of Vermiform Appendix In South-East Caspian Sea (Gorgan-IRAN). *J Anat Soc India.* 2003;52(2):141–3.
14. Arindom B, Kumar A. Morphological variations of vermiform appendix and caecum: A cadaveric study. *Int J Anat Res.* 2017;5:2–3.
15. Ahmed SN, Ahmed MK. Syed Nazeer Ahmed Mohammed Khaleel Ahmed A Study of Vermiform Appendix and Its Various Position in Adults. *Indian J Anat.* 2020;9(1):69–72.
16. Ehab I, El-Amin GY. Waled Amen Mohammed Ahmed et al. Lengths and Positions of the Vermiform Appendix among Sudanese Cadavers. *AIMS Med Sc.* 2015;2:222–7.

Author biography

Mohini M. Joshi, Professor  <https://orcid.org/0000-0001-6081-3271>

Sandeep V. Pakhale, Professor and HOD

Cite this article: Joshi MM, Pakhale SV. Morphological variations of vermiform appendix: A cadaveric study. *IP Indian J Anat Surg Head, Neck Brain* 2023;9(1):20-24.