

Content available at: <https://www.ipinnovative.com/open-access-journals>

IP Indian Journal of Anatomy and Surgery of Head, Neck and Brain

Journal homepage: <https://www.ijashnb.org/>

Case Report

Use of adjuvant intravenous bevacizumab for aggressive recurrent respiratory papillomatosis- A case report

Deepa Shivnani^{1,*}

¹Dept. of ENT, Manipal Hospitals, Bengaluru, Karnataka, India



ARTICLE INFO

Article history:

Received 18-09-2023

Accepted 17-10-2023

Available online 30-10-2023

Keywords:

JORRP

Medical Treatment

Bevacizumab

ABSTRACT

Recurrent Respiratory Papillomatosis (RRP) is a benign condition which needs frequent surgical interventions for debulking of papillomatosis lesions for securing the airway. There is no definitive treatment for the management of RRP so far. Bevacizumab either intralesional or systemic has emerged as a promising solution for RRP patients undergoing repeated surgeries. We are reporting a case of a 6-year-old child with juvenile onset RRP who was treated by surgical excision of lesion with adjuvant systemic bevacizumab therapy.

This is an Open Access (OA) journal, and articles are distributed under the terms of the [Creative Commons Attribution-NonCommercial-ShareAlike 4.0 License](#), which allows others to remix, tweak, and build upon the work non-commercially, as long as appropriate credit is given and the new creations are licensed under the identical terms.

For reprints contact: reprint@ipinnovative.com

1. Introduction

Recurrent Respiratory Papillomatosis (RRP) is caused by Human Papilloma Virus and characterised by recurrent papilloma of respiratory tract mainly involving the larynx. The symptoms can vary from the hoarseness to the acute airway obstruction due to extensive papillomatous lesion. Two forms have been characterised – JoRRP – Juvenile onset which presents below the age of 12 years and Adult onset - AoRRP which is Adult age group. In a Juvenile form, transmission of HPV is believed to occur from the mother to the foetus during the vaginal delivery.

In JoRRP, child may become symptomatic between the age 2 to 6 years. The initial presenting symptoms could be dysphonia, progressive stridor, respiratory distress or sometimes with recurrent cough and haemoptysis. In developing country like India patients are often misdiagnosed due to the lack of healthcare facilities in general and ENT services in particular. Flexible laryngoscopic examination and biopsy are mandatory to confirm the diagnosis. Surgical debulking of the lesion to

maintain the airway patency is the mainstay of treatment.¹ The recurrent nature of the disease can be devastating in an young child. Various systemic and intralesional adjuvant therapies have been proposed in literature but very limited data is available for paediatric age group. The purpose of this case report is to share our experience in an aggressive juvenile RRP case who was successfully treated with multiple surgical procedures and intravenous bevacizumab therapy.

2. Case Report

A 6-year old girl from lower socioeconomic background was first presented in 2017 as an out-patient with a history of hoarseness of voice for 3 months. She had been treated for gastro esophageal reflux disorder empirically with no improvement in symptoms. She underwent direct laryngoscopic examination and extensive lesion noticed at the larynx obscuring the airway completely (Figure 1).

The lesion was removed with the help of microdebrider. Initially, child underwent multiple debulking procedures every 3–4 weeks interval since 2018 when the papillomas were limited only on laryngeal surface. Later, the child

* Corresponding author.

E-mail address: Deepa.shivnani14@gmail.com (D. Shivnani).

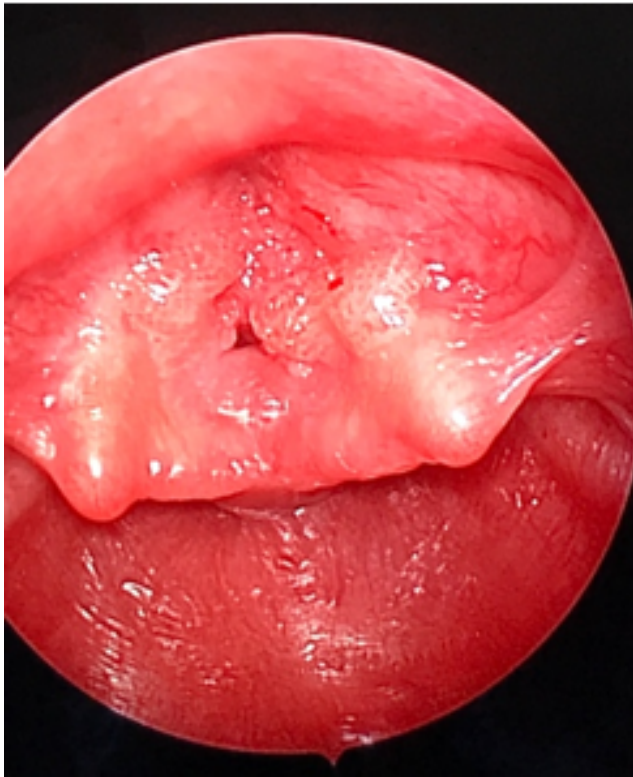


Fig. 1: Laryngeal papilloma lesion involving bilateral false vocal cords causing 90 % obstruction in the airway lumen

underwent tracheostomy due to excessive respiratory distress in 2019 during which the symptoms increased and the lesions became more extensive (Figure 2) and obvious at the level of trachea and carina.

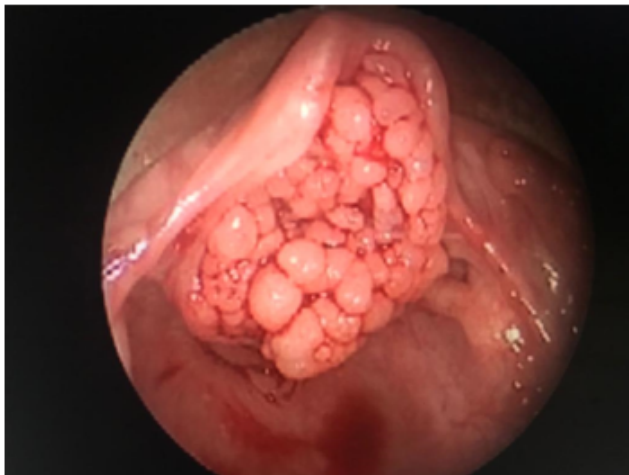

Fig. 2: Extensive papillomatosis lesion causing complete obstruction of airway

She underwent overall 64 procedures before starting the intravenous bevacizumab therapy. Intravenous bevacizumab

(Avastin, Genetech Inc.) was started with the dose of 10 mg/kg body weight infusion every 3 weekly when the patient's airway status deteriorated. The family counselling was done about the risks of bevacizumab and its off-label use for this indication. The patient was monitored with blood pressure testing on the days of the procedures/infusions. Prior to each infusion, lab work was sent for a complete metabolic profile, urine protein: creatinine ratio, magnesium, and phosphorous. Remarkable improvement was noticed in her laryngotracheal disease within 9 weeks of therapy. The patient had significantly lower disease burden at the laryngeal level and in the trachea (Figure 3).

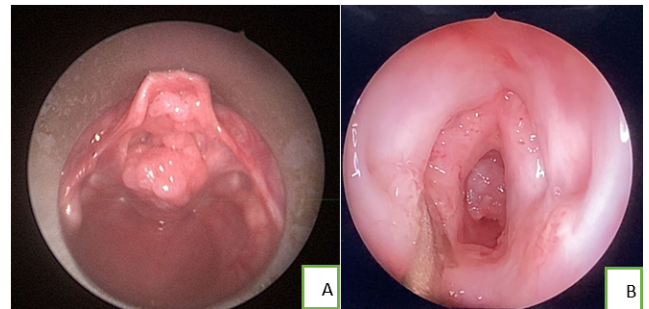


Fig. 3: a: reduction in laryngeal lesion after first dose of intravenous bevacizumab b: remarkable reduction in the papilloma lesion after 3 doses of intravenous bevacizumab

She is still on follow up and the interval between the procedures have been prolonged to 6-8 months. The patient had no major or minor complication from the chemotherapy to date.

3. Discussion

RRP can be life threatening as it can cause airway narrowing due to mass effect of the papillomatous lesion. The most common outcome is mortality related to difficult intubation/anaesthesia, cancerous transformation and severe pulmonary infections. The classical treatment modality is surgical debriement. The adjuvant therapies are advocated in cases with multiple surgical procedures, extensive lesions and in the cases with pulmonary involvement.²

Bevacizumab (Avastin, Genetech Inc., South San Francisco, CA) is a recombinant humanized monoclonal immunoglobulin G antibody which inhibits angiogenesis of the human vascular endothelial growth factor-A (VEGF) and blocking their binding to VEGF receptors (VEGFR). Bevacizumab blocks the development of a tumor's own blood supply and helps slow down the tumour growth.³ Intralesional or Intravenous administration of bevacizumab have shown beneficial effect in increasing the interval between surgeries as well as resolution of the lesions in a few patients. The improvement is voice outcome has been noticed too.^{4,5}

While intralesional injections are not reported to have any systemic complications, systemic administration of the drug is known to cause fewer side effects like proteinuria, hypertension, joint pain, haemoptysis, and lethargy which mostly improve after discontinuation of therapy and had been reported more in adults than children.^{6–8}

4. Conclusion

The mainstay of treatment is surgical excision of papillomatosis lesion. Adjuvant therapy with intravenous bevacizumab has shown promising results and can be used in aggressive RRP cases. Although bevacizumab usage has been increased in recent past for the management of RRP, its efficacy for intralesional and systemic administration needs multicentric trials. The long term side effects and dose adjustments need further research for paediatric cases.

5. Declaration

Informed consent for publication was taken from the parents of the child.

6. Source of Funding

None.

7. Conflict of Interest

None

References

1. Carifi M, Napolitano D, Morandi M, Olio D. Recurrent respiratory papillomatosis: current and future perspectives. *Ther Clin Risk Manag.* 2015;11:731–8. doi:10.2147/TCRM.S81825.
2. Schraffs D, Burkeb L. American Society of Pediatric Otolaryngology members' experience with recurrent respiratory papillomatosis and the use of adjuvant therapy. *Arch Otolaryngol Head Neck Surg.* 2004;130(9):1039–42.
3. Best SR, Mohr M, Zur KB. Systemic bevacizumab for recurrent respiratory papillomatosis: a national survey. *Laryngo- Scope.* 2017;127(10):2225–9.
4. Bedoya A, Glisinski K, Clarke J, Lind RN, Buckley CE, Shofer S, et al. Systemic bevacizumab for recurrent respiratory papillomatosis: a single centre experience of two cases. *Am J Case Rep.* 2017;18:842–46. doi:10.12659/ajcr.904416.
5. Rahbar R, Vargas SO, Folkman J. Role of vascular endothelial growth factor-A in recurrent respiratory papillomatosis. *Ann Otol Rhinol Laryngol.* 2005;114(4):289–95.
6. Mohr M, Schliemann C, Biermann C. Rapid response to systemic Bevacizumab therapy in recurrent respiratory papillomatosis. *Oncol Lett.* 2014;8(5):1912–8.
7. Raymond ST, Roubey F, Default A, Jean-Pastor MJ. Bevacizumab induced serious side-effects: a review of the French pharmacovigilance database. *Eur J Clin Pharmacol.* 2012;68(7):1103–7.
8. De Pasquale M, Castellano A, Sio D. Bevacizumab in pediatric patients: how safe is it? *Anticancer Res.* 2011;31(11):3953–7.

Author biography

Deepa Shivnani, Associate Consultant

Cite this article: Shivnani D. Use of adjuvant intravenous bevacizumab for aggressive recurrent respiratory papillomatosis- A case report. *IP Indian J Anat Surg Head, Neck Brain* 2023;9(3):96-98.