

Content available at: <https://www.ipinnovative.com/open-access-journals>

IP Indian Journal of Anatomy and Surgery of Head, Neck and Brain

Journal homepage: <https://www.ijashnb.org/>

Case Report

Plexiform schwannoma: A rare histological entity at a rare site

Kratee¹, Sumindra Mora¹, Kafil Akhtar^{1*}

¹Dept. of Pathology, Jawaharlal Nehru Medical College, Faculty of Medicine, Aligarh Muslim University, Aligarh, Uttar Pradesh, India



ARTICLE INFO

Article history:

Received 10-01-2024

Accepted 05-02-2024

Available online 21-02-2024

Keywords:

Plexiform

Schwannoma

Histopathology

Rare

ABSTRACT

Plexiform schwannoma is an uncommon Schwann cell tumor, characterized by its multinodular growth with a plexiform histological pattern. Plexiform schwannoma arises from the soft tissues around the head and neck region. Few cases are associated with neurofibromatosis type 2 or schwannomatosis. We present a rare case of this tumor in a 25-year-old man, who presented with a discrete movable, deep seated nodule, associated with pain and tenderness over the spinal region, across the seventh cervical vertebrae with chief complaints of dizziness and vertigo for the last one year.

This is an Open Access (OA) journal, and articles are distributed under the terms of the [Creative Commons Attribution-NonCommercial-ShareAlike 4.0 License](https://creativecommons.org/licenses/by-nc-sa/4.0/), which allows others to remix, tweak, and build upon the work non-commercially, as long as appropriate credit is given and the new creations are licensed under the identical terms.

For reprints contact: reprint@ipinnovative.com

1. Introduction

Plexiform schwannoma (PS) is a rare variant of schwannoma, which was first described by Harkin et al in 1978.¹ It presents as a plexiform multinodular growth.

The distinguishing features of plexiform schwannoma are compact palisaded arrangement of Schwann cells (Antoni A) admixed with loose cystic areas (Antoni B), with verocay body formation and hyalinized blood vessels.² As compared to conventional schwannomas, plexiform schwannoma exhibits increased cellularity.³ PS is a benign indolent tumor, with no evidence of metastasis.⁴ PS is not associated with neurofibromatosis type 1 (NF1), but it may occur in cases of NF2 and schwannomatosis.⁵⁻⁷ PS is a superficial soft tissue tumor in young adults and occurs commonly as a solitary, slow-growing, asymptomatic nodule on the head, neck, trunk, or upper extremities.^{1,3}

2. Case Summary

A 25-year-old man presented to the Neurology clinics with complaints of dizziness and vertigo for the last one year. There was no history of throbbing headache of projectile vomiting. He had no family history of neurofibromatosis (NF). On physical examination, a 1.5×0.5 cm-sized, discrete movable, deep seated painful nodule was observed on the neck across the seventh cervical vertebrae. There was no NF-1-related cutaneous lesions, like neurofibromas, café-au-lait spots, axillary freckling or Lisch nodules seen. Magnetic resonance imaging (MRI) revealed a unilateral schwannoma, with foci of calcifications.

An excisional biopsy was performed and grossly the specimen from the neck showed multiple lobulated tumor masses, surrounded by a thin fibrous capsule. Microscopically, the mass revealed multiple interlacing and interconnecting fascicles of Schwann cells, surrounded by delicate rigid reticular fibers. Characteristic cellular Antoni type A areas with palisaded nucleus and verocay bodies were observed along with loose acellular Antoni B areas (Figures 1 and 2).

* Corresponding author.

E-mail address: drkafilakhtar@gmail.com (K. Akhtar).

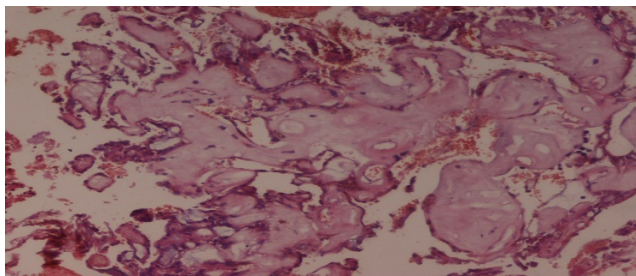


Figure 1: Section shows cellular Antoni type A c with nuclear palisading, verocaybodies admixed with loose acellular Antoni B areas. H &E x10X

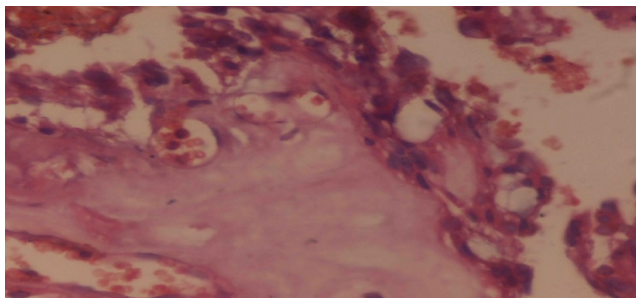


Figure 2: Section shows cellular antoni type a areas along with acellular antoni b areas. H & E x40X

Immunohistochemical analysis showed strong cytoplasmic positivity for S-100 in the tumor cells (Figure 3) and negativity for neurofilaments, which confirmed the diagnosis of plexiform schwannoma.

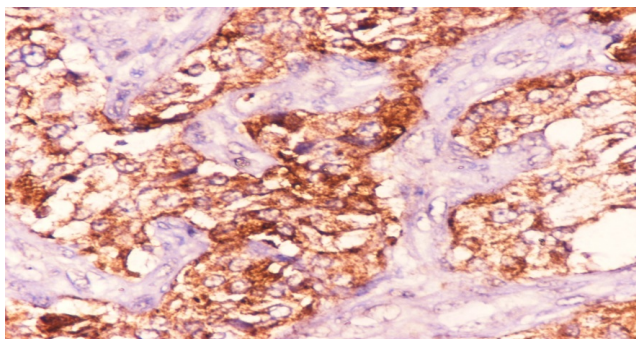


Figure 3: Section shows cytoplasmic positivity of S-100 in the tumor cells. IHC S-100x40X

Based on these findings, a final diagnosis of plexiform schwannomas was given. Our patient is doing well after three months of follow up period.

3. Discussion

Plexiform schwannoma was first described by Harkin et al in 1978.¹ It is a benign peripheral nerve sheath tumor composed of Schwann cells arranged in a plexiform

architecture.¹ It presents as a single, small, soft to rubbery, mobile, non-tender mass.¹ Histopathologically, the tumor is composed of cellular Antoni type A areas with palisading nuclei (verocay bodies).¹ It is important to differentiate a plexiform schwannoma from a plexiform neurofibroma because the latter is pathognomic of NF1 with a significant risk of malignant transformation.⁴ Plexiform schwannomas can be distinguished by their increased cellularity, nuclear palisading (with or without Verocay bodies), and hyalinized blood vessels.^{7,8}

PS is usually a superficial tumor with involvement of the skin and subcutaneous tissue in the head and neck and the trunk.^{2,3} Iida et al., have reported the age of these patients between 2 to 80 years, with a mean age of 30 years, with equal gender predisposition.⁸ Neurofibromatoses, including neurofibromatosis type 1, neurofibromatosis type 2, and schwannomatosis are neurogenetic disorders characterized by the development of multiple nerve sheath tumors.⁹ Plexiform schwannoma mostly occurs sporadically, as in our case. It can occur occasionally in patients with neurofibromatosis type 2 or schwannomatosis but very rarely in neurofibromatosis type 1.³ Our patient had a solitary tumor, with no familial history of neurofibromatoses.

Plexiform schwannoma is typically multinodular and plexiform, with an intraneural growth pattern, which distinguishes it from other variants of schwannoma. This tumor is highly cellular histologically in infants and young children.¹⁰ Solitary schwannomas and neurofibromas occur sporadically while multiple tumors are associated with genetic syndromes, like NF-1.^{3,5} About 8–15% of patients with NF-1 progress to malignant peripheral nerve sheath tumor (MPNST) during their lifetime.¹¹

4. Source of Funding

None.

5. Conflict of Interest

None.

References

1. Lim HS, Jung J, Chung KY. Neurofibromatosis type 2 with multiple plexiform schwannomas. *Int J Dermatol.* 2004;43(5):336–40.
2. Ishida T, Kuroda M, Motoi T, Oka T, Imamura T, Machinami R, et al. Phenotypic diversity of neurofibromatosis 2: association with plexiform schwannoma. *Histopathology.* 1998;32(3):264–70.
3. Miyakawa T, Kamada N, Kobayashi T, Hirano K, Fujii K, Sasahara Y, et al. Neurofibromatosis type 2 in an infant with multiple plexiform schwannomas as first symptom. *J Dermatol.* 2007;34(1):60–4.
4. Kohyama S, Hara Y, Nishiura Y, Hara T, Nakagawa T, Ochiai N, et al. A giant plexiform schwannoma of the brachial plexus: case report. *J Brachial Plex Peripher Nerve Inj.* 2011;6(1):9–10.
5. Kao GF, Laskin WB, Olsen TG. Solitary cutaneous plexiform neurilemmoma (schwannoma): a clinicopathologic, immunohistochemical, and ultrastructural study of 11 cases. *Mod Pathol.* 1989;2(1):20–6.


6. Plotkin SR, Blakeley JO, Dombi E, Fisher MJ, Hanemann CO, Walsh KS, et al. Achieving consensus for clinical trials: the REiNS International Collaboration. *Neurol.* 2013;81(21):1–5.
7. Dwyer CL, Creager AJ, Lubahn JD. An unusual presentation of a digital schwannoma: case report. *Hand (N Y).* 2015;10(2):301–4.
8. Iida A, Imamura Y, Katayama K, Hirose K, Yamaguchi A. Plexiform schwannoma of the small intestine: report of a case. *Surg Today.* 2003;33(12):940–3.
9. Niveditha SR, Kusuma V. Cutaneous plexiform schwannoma of the digit: A case report. *J Clin Diagn Res.* 2019;13(9):1–3. doi:10.7860/JCDR/2019/37744.13142.
10. Wollina U, Langner D, Gruner M, Schönlebe J, Haroske G. Isolated plexiform schwannoma of the hand. *J Dermatol Case Rep.* 2008;2(2):28–30.
11. Ejiyooye TF, Dirisanala S, Abouzied HM, Mahjabeen SS, Sajjad T, Khan A, et al. A rare case of plexiform schwannoma of the little finger and its management: a case report. *Cureus.* 2022;14(6):e26391.

doi:10.7759/cureus.26391.

Author biography

Kratee, Resident

Sumindra Mora, Resident

Kafil Akhtar, Professor  <https://orcid.org/0000-0002-3482-1195>

Cite this article: Kratee, Mora S, Akhtar K. Plexiform schwannoma: A rare histological entity at a rare site. *IP Indian J Anat Surg Head, Neck Brain* 2023;9(4):140-142.