

Content available at: <https://www.ipinnovative.com/open-access-journals>

IP Indian Journal of Anatomy and Surgery of Head, Neck and Brain

Journal homepage: <https://www.ijashnb.org/>

Case Report

Unusual foreign bodies in upper aero digestive tract – Our experience at tertiary care centre

Ramraj Yadav¹, Ashvaneer Chaudhary¹, Sanjay Kumar Saroj^{1*},
Deepak Kumar Gupta¹, Shishupal Yadav¹, Satya Prakash Verma¹,
Vishwambhar Singh¹, Rajesh Kumar¹

¹Dept. of Ear, Nose & Throat, Institute of Medical Sciences, Banaras Hindu University, Varanasi, Uttar Pradesh, India



ARTICLE INFO

Article history:

Received 05-01-2024

Accepted 08-02-2024

Available online 21-02-2024

Keywords:

Upper aerodigestive tract foreign body

Unusual foreign body

Pediatric ingestion

Endoscopic removal

ABSTRACT

Foreign bodies ingestion is especially common in the pediatric age group, whereas in adults occur accidentally or among those with psychiatric disorders, mental retardation, prisoners and alcoholics. Preexisting GI tract abnormalities, such as previous surgery, strictures, or functional abnormalities, increases the risk of a swallowed foreign body becoming lodged at the site of the abnormality. This retrospective study was conducted in 32 patients with upper aero digestive tract unusual foreign bodies presenting to our department on emergency basis in a duration of one year. This Study was conducted in ENT department tertiary care Centre in duration of 2021-2022, 32 patients presented with unusual FB in upper aero digestive tract were treated in our department on an emergency basis. There were 14 male (43.75%) and 18 female (56.25%) ranging in age from 2 to 62 years. The main symptoms patients complained were difficulty in swallowing and pain. Detailed history with examination of nasal cavity, oral cavity and pharynx by indirect laryngoscopy and finally X-ray or CT scan were the diagnostic tools as required. The location of the FB was in the esophagus, Pyriform sinus, hypopharynx in decreasing order. The treatment consisted of rigid endoscopy and foreign body removal under general anesthesia or sedation. No major complications occurred in procedure except one in with iatrogenic esophageal perforation that was managed conservatively. Endoscopy is a reliable method in the treatment of upper aero digestive tract foreign body (FB) impaction.

This is an Open Access (OA) journal, and articles are distributed under the terms of the [Creative Commons Attribution-NonCommercial-ShareAlike 4.0 License](https://creativecommons.org/licenses/by-nc-sa/4.0/), which allows others to remix, tweak, and build upon the work non-commercially, as long as appropriate credit is given and the new creations are licensed under the identical terms.

For reprints contact: reprint@ipinnovative.com

1. Introduction

Foreign bodies ingestion is especially common in the pediatric age group, whereas in adults occur accidentally or among those with psychiatric disorders, mental retardation, prisoners and alcoholics.¹ Fortunately, most of them pass through the gastrointestinal tract harmlessly but some foreign bodies are dangerous due to its shape, size or nature.^{2,3} However, 10–20% will require intervention and less than 1% requires surgery.^{1–4} A retrospective study was conducted in 32 patients with unusual foreign

body in upper aero digestive tract in order to analyze our experience and nature of foreign body and method of removal at our center. The procedure should be carried out by experienced otorhinolaryngologists, and the department should count on the support of general and thoracic surgeons in case iatrogenic esophageal perforations should happen. Complications rarely happen, however there may be aspiration and upper airway obstruction, mucosal damage, esophageal erosion and trachea-esophageal fistulas. Complications occur mainly because of invasive removal attempts. Preexisting GI tract abnormalities, such as previous surgery, strictures, fistulas,

* Corresponding author.

E-mail address: sk74676@bhu.ac.in (S. K. Saroj).

diverticula, or functional abnormalities, increases the risk of a swallowed foreign body becoming lodged at the site of the abnormality.

Total 32 patients with unusual foreign body in upper aero digestive tract, out of which 14 (43.75%) were male and 18 (56.25%) were female; of age group 2 years to 62 years with an average age of 15 years were managed in ENT Department, SSH, BHU in 2021-2022. The presenting complaints of the patients were difficulty in swallowing, acute onset throat pain, difficulty in deglutition, excessive salivation with most of the patients having clear history of foreign body ingestion. Detailed history, physical examination of nasal cavity, oral cavity, oropharynx, hypopharynx and abdomen (to exclude peritonitis, bowel obstruction) was performed in all the patients. Radiological evaluation in form of X-ray of neck AP and lateral view, Chest X-ray AP view performed in all cases whereas X-ray abdomen and CT scan of required portion was performed as required.

Radio opaque foreign bodies are not visualized with imaging techniques, so one must rely on history and clinical judgement. Endoscopy is a reliable method in the treatment of upper aero digestive tract FB impaction, but due care must be taken to avoid tear of surrounding structures especially in cases with sharp edges.

2. Case Presentation

The foreign body impaction in cervical esophagus, hypopharynx, thoracic esophagus and glottis was 14(43.75%), 14(43.75%), 3(9.38%), and (3.13%) respectively (Table 1). Most common objects were found to be denture 11(34.38%) followed by bone 8(25%) then pin 3(9.34%) (Table 2 and Figures 1, 2 and 3).

Table 1:

S.No.	Site of FB	Number
1	Hypopharynx	14
2	Cervical esophagus	14
3	Thoracic esophagus	3
4	Glottic	1

All the FB were removed by rigid endoscopy under general anesthesia and perioperative period remained uneventful except one with turtle bone ingestion where iatrogenic esophageal tear occurred which got healed by conservative management.

Follow up of the patients was done based on personal interaction over a period of three months in cases with no perioperative complications.

3. Discussion

Materials impacted in upper aero digestive tract are generally foreign body or food bolus. In pediatric age

Table 2:

S.No.	Nature of FB	Number
1	Denture	11
2	Fish bone	5
3	Pin	3
4	Mutton bone	2
5	Plastic bottle cap	2
6	Metallic nut	1
7	Turtle bone	1
8	Metallic ring	1
9	Plastic ring	1
10	Metallic Rakhi	1
11	Pen cap	1
12	Battery	1
13	Metallic key	1
14	Castor seed	1

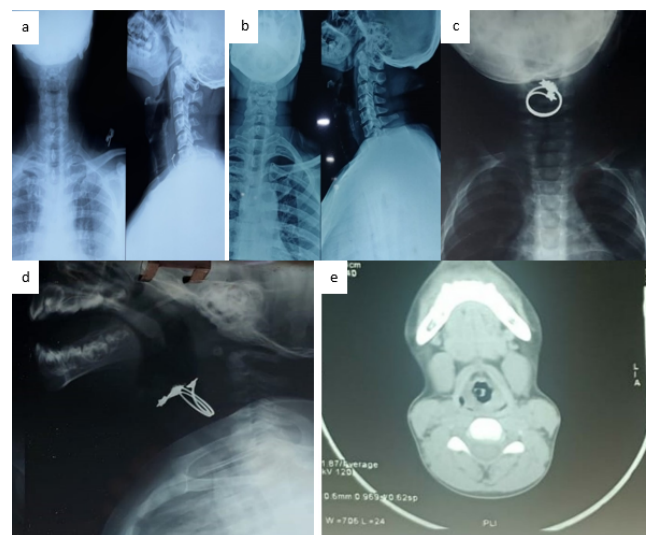


Figure 1: Radiological images- a:b: X ray neck AP/ LAT View showing foreign body denture in cervical esophagus; c: X ray Neck and Chest AP view showing ring in cervical esophagus; d: X ray Neck Lat view showing ring in cervical esophagus; e: NCCT Neck showing glottis foreign body

group, most common foreign bodies are generally coins, toys, ring or any other foreign body that are commonly available to them, but adult can get into problem with ingested meat, bone or denture in older age group.^{5,6} Mental status of the patients carries greater impact.^{1,6} Irregular sized large foreign body can cause local injury, mucosal erosion, inflammation, perforation or even serious infection such as parapharyngeal or retropharyngeal abscess that can be fatal specially by the sharp pointed FB, animal or fish bone.^{3,4,7–10} Detailed history, physical examination of nasal cavity, oral cavity, oropharynx, hypopharynx and abdomen (to exclude peritonitis, bowel obstruction) should be performed in all the patients. Radiological evaluation in form of X-ray of neck AP and lateral view, Chest X-ray,

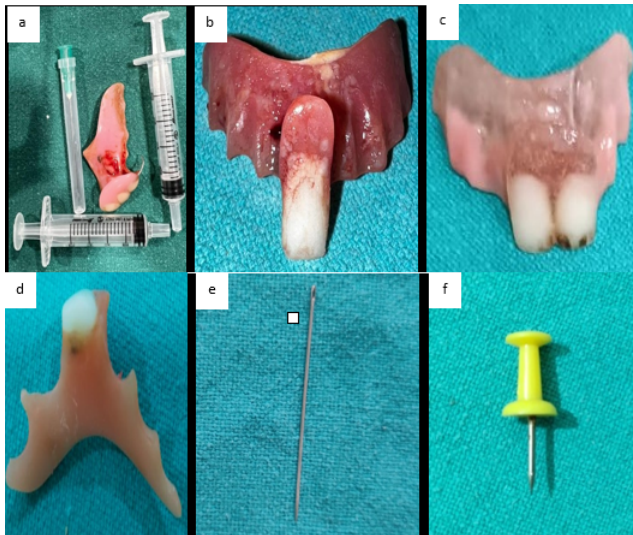


Figure 2: Showing foreign body: **a,b,c,d:** Showing denture; **e & f:** Showing metallic pin

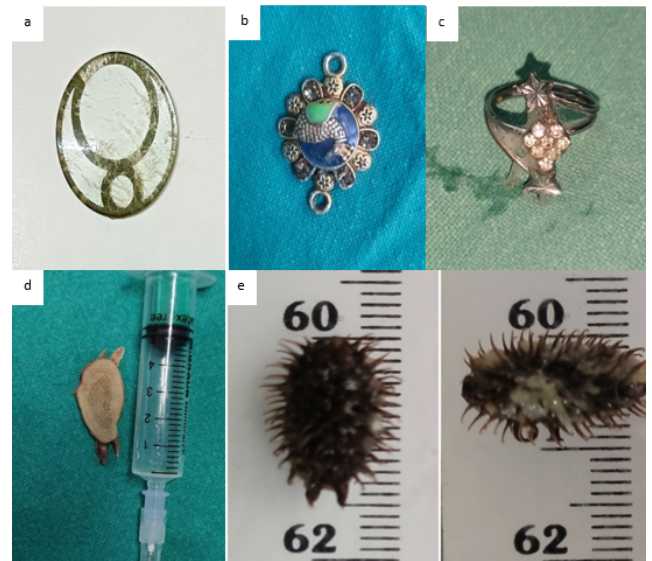

Figure 4: Showing foreign body- **a:** Showing plastic ring; **b:** Showing metallic foreign body Rakhi; **c:** Showing metallic foreign body Ring; **d:** Showing turtle bone; **e:** Showing castor seed



Figure 3: Showing foreign body- **a, b:** Showing plastic bottle cap; **c:** Showing plastic pen cap; **d:** Showing battery; **e:** Showing metallic key; **f:** Showing metallic nut

performed in all cases when indicated, X-ray abdomen and CT scan of required portion is performed as required.

Once a case is diagnosed and site of the foreign body is ascertained by the above measures then urgency of the intervention is anticipated. The timing of intervention depends upon the nature of foreign body and risk of complication as sharp objects and batteries require urgent removal due to high risk of complication.

Most FB ingestions occur in the pediatric population, with a peak incidence between the ages of 6 months and 6

years. It has been shown that most ingested FBs will pass spontaneously the gastrointestinal tract without the need for intervention (80–90%).¹¹ Mental status of the patient having greater impact¹²

The modality of intervention depends on many factors such as patients age, nature of foreign body, site of impaction, shape and size of material impacted, clinical condition of patient and skill of attending doctor as well as available facilities. The most important thing that should be considered is airway of the patient and once airway is secured then any intervention can be done as required. Currently most used modality is endoscopy which bears the advantage of direct visualization of the foreign body and its removal. Currently rigid endoscopic procedures are performed in general anesthesia or sedation depending upon the availability and skill of the doctor, both methods are safe and effective in experienced hands.^{1,5,13} It has been shown that most ingested FBs will pass spontaneously the gastrointestinal tract without the need for intervention (80–90%).

4. Conclusion

Endoscopy is a reliable method for foreign body removal from upper aero digestive tract. It is minimal invasive, safe and effective. Rigid endoscopic removal of foreign body under direct visualization is safe procedure and very less chance of complication.

5. Source of Funding

None.

6. Conflict of Interest

None.

References

1. Webb WA. Management of foreign bodies of the upper gastrointestinal tract: update. *Gastrointest Endosc.* 1995;41(1):39–50.
2. Schwartz GF, Polsky HS. Ingested foreign bodies of the gastrointestinal tract. *Am Surg.* 1976;42(4):236–8.
3. Singh B, Kantu M, Har-El G, Lucente FE. Complications associated with 327 foreign bodies of the pharynx, larynx and esophagus. *Ann Otol Rhinol Laryngol.* 1997;106(4):301–4.
4. Nandi P, Ong GB. Foreign body in the esophagus: review of 2394 cases. *Br J Surg.* 1978;65(1):5–9.
5. Ginsberg GG. Management of ingested foreign bodies and food bolus impactions. *Gastrointest Endosc.* 1995;41(1):33–8.
6. Webb WA. Management of foreign bodies of the upper gastrointestinal tract. *Gastroenterology.* 1988;94(1):204–16.
7. Watanabe KI, Kikuchi T, Katori Y, Fujiwara H, Sugita R, Takasaka T, et al. The usefulness of computed tomography in the diagnosis of impacted fish bones in the esophagus. *J Laryngol Otol.* 1998;112(4):360–4.
8. Fonga-Djimi H, Leclerc F, Martinot A, Hue V, Fourier C, Deschildre A, et al. Spondylodiscitis and mediastinitis after esophageal perforation owing to a swallowed radiolucent foreign body. *J Pediatr Surg.* 1996;31(5):698–700.
9. Wu M, Lai W. Aorto-esophageal fistula induced by foreign bodies. *Ann Thorac Surg.* 1992;54(1):152–6.
10. Yamada T, Sato H, Seki M, Kitagawa S, Nakagawa M, Shimazaki H, et al. Successful salvage of aorto-esophageal fistula caused by a fish bone. *Ann Thorac Surg.* 1996;61(6):1843–5.
11. Ricote GC, Torre LR, De Ayala V, Castellanos D, Menchen P, Senent C, et al. Fiberoendoscopic removal of foreign bodies of the upper part of the gastrointestinal tract. *Surg Gynecol Obstet.* 1985;160(6):499–504.
12. Webb WA. Management of foreign bodies of the upper gastrointestinal tract. *Gastroenterology.* 1988;94(1):204–16.
13. Cambell JB, Foley LC. A safe alternative to endoscopic removal of blunt esophageal foreign bodies. *Arch Otolaryngol.* 1983;109(5):323–5.

Author biography

Ramraj Yadav, Senior Resident

Ashvaneer Chaudhary, Senior Resident

Sanjay Kumar Saroj, Senior Resident

Deepak Kumar Gupta, Senior Resident

Shishupal Yadav, Senior Resident

Satya Prakash Verma, Junior Resident

Vishwambhar Singh, Associate Professor

Rajesh Kumar, Professor

Cite this article: Yadav R, Chaudhary A, Saroj SK, Gupta DK, Yadav S, Verma SP, Singh V, Kumar R. Unusual foreign bodies in upper aero digestive tract – Our experience at tertiary care centre. *IP Indian J Anat Surg Head, Neck Brain* 2023;9(4):143-146.