

## Clinical study of correlation between preoperative CTscan findings with intra-operative findings in cases of chronic rhinosinusitis

Shruti Handanakere<sup>1,\*</sup>, Chidananda Ramappa Devasanudra<sup>2</sup>

<sup>1</sup>Senior Resident, <sup>2</sup>Associate Professor, Dept. of ENT, Yashoda Super Speciality Hospital, Hyderabad

**\*Corresponding Author:**

**Shruti Handanakere**

Senior Resident, Dept. of ENT, Yashoda Super Speciality Hospital, Hyderabad

Email: drshruti83@gmail.com

### Abstract

**Introduction:** Chronic rhino sinusitis (CRS) is one of the most common chronic diseases and affects nearly 50 million individuals every year world over. The advent of CT scan in the delineation of the sinonasal pathology and anatomical variations has proven invaluable to the otolaryngologists in the pre-operative planning but CT scan is not always accurate in depicting the disease and anatomical variants. These discrepancies though minor, need further evaluation and correlation of CT scan findings to that of findings observed during Functional endoscopic sinus surgery

**Methods:** 30 adult patients with chronic rhino sinusitis were studied for one Year CT scan findings were correlated with intraoperative findings during endoscopic surgery.

**Result:** There was excellent correlation >90% between preoperative CT scan and Endoscopic Sinus Surgery in cases of osteomeatal complex widening, anterior ethmoidal polypoidal change. Correlation was good >80% for posterior ethmoidal polypoidal change. Correlation was not good but acceptable >70% for polypoidal changes in nasal cavity and sinuses. The correlation was poor >60% in cases of osteomeatal complex total and partial occlusion, mucosal thickening in nasal cavity and polypoidal change in maxillary and frontal sinuses. P value was significant in all parameters.

**Conclusion:** Thorough anatomical knowledge is necessary for the surgeon to correlate the preoperative CT scan findings with intraoperative findings during Functional endoscopic sinus surgery.

**Keywords:** CT scan, Functional endoscopic sinus surgery, Maxillary sinus, Frontal sinus, Ethmoidal sinus, Chronic rhino sinusitis.

### Introduction

Chronic rhino sinusitis (CRS) is one of the most common chronic diseases and affects nearly 50 million individuals every year world over. The diagnosis of CRS relies on clinical judgement based on a number of subjective symptoms and few findings on physical examination. These symptoms and signs are inherently vague and because of the uncertainty associated with the diagnosis of CRS, it is necessary to have data that is more objective about the extent of the disease.<sup>(1)</sup> Endoscopic sinus surgery has evolved as an effective treatment option and indeed is the treatment of choice for medically refractory chronic rhino sinusitis with excellent success rates.<sup>(2)</sup>

The advent of CT scan in the delineation of the sinonasal pathology and anatomical variations has proven invaluable to the otolaryngologists in the preoperative planning but CT scan is not always accurate in depicting the disease and anatomical variants. These discrepancies though minor, need further evaluation and correlation of CT findings to that of findings observed during Functional endoscopic sinus surgery<sup>(1)</sup>. Radiological investigations and image-guided systems do provide help but they can no way replace surgeon's thorough anatomical knowledge to perform a safe and successful surgery<sup>(12)</sup>.

### Material and Methods

The present study "Clinical Study of Correlation of preoperative CT scan findings with intraoperative findings in cases of chronic rhino sinusitis" was carried out at Yashoda superspeciality hospital, Hyderabad in the department of ENT and Head and Neck surgery. The aim of the study is to correlate the preoperative CT scan findings and the disparity with intraoperative findings in cases of chronic rhino sinusitis. Institutional Ethical Committee approval was obtained.

**Study Type:** Prospective observational study.

**Material:** 30 adult patients between 18-65years of age of either sex.

**Study Period:** 12 months.

### Inclusion Criteria

All patients with history, clinical examination, diagnostic nasal endoscopy and CT scan findings suggestive of chronic rhino sinusitis.

### Exclusion Criteria

1. Patients who have already undergone FESS.
2. Cases of suspected malignancy or any other pathology

### Method

1. History, clinical examination, diagnostic nasal endoscopic examination and optimal medical

- management to shrink and reduce inflammatory and hyper plastic mucosa.
2. Non contrast CT scans of nose and paranasal sinuses with mainly coronal cuts with axial cuts for sphenoethmoidal recess and onodi cell, saggital cuts for frontal with a gross slice thickness of 3mm was taken.
  3. The patients underwent endoscopic sinus surgery after obtaining Routine preoperative investigations and written informed consent for the same.
  4. The CT scan findings were correlated with the intra-operative endoscopic findings during functional endoscopic sinus surgery.

**Statistical Analysis:** Correlation between CT scan and Endoscopic sinus surgery.

Findings was done on the basis of,

1. Sensitivity
2. Specificity
3. Positive Predictive Value (PPV)
4. Negative Predictive Value (NPV)
5. Kappa’s measure of agreement
6. P-value

**Parameters for Study**

Osteomeatal complex normal, total occlusion, partial occlusion(OMC-N,TO,PO),Mucosal thickening in nasal cavity and sinuses(MT-N,S), Polypoidal changes in nasal cavity and sinuses(PC-N,S), Polypoidal changes in individual sinuses like maxillary(M), frontal(F), anterior ethmoid (AE), Posterior ethmoid (PE).

**Observation and Results**

**Table1: Distribution of Sex**

Sex	No of cases	Percentage (%)
Male	23	76.66
Female	07	23.33

In our study, the sex distribution showed male preponderance with **23(76.66%)** males and **7(23.33%)** females.

**Table 2: Distribution of Age**

Age in years	No. of cases	Percentage (%)
20-40	16	53.33
40-60	10	33.33
60-80	4	13.33

Common age group of presentation in our study was between **20-40 yrs** followed by age group between 40-60yrs.

**Table 3: Distribution of Duration of disease**

Duration in years	No of cases	Percentage (%)
<1	02	6.66
1-5	20	66.66
>5	08	26.66

**66.66%** patients with chronic sinusitis had symptoms for **1 to 5 years** and 26.66% had for more than 5 years. Only 6.66% had symptoms for less than 1 year.

**Table 4: Assessment of osteomeatal complex**

Osteomeatal complex	CT Scan		ESS	
	No	%	No	%
Normal	3	10	3	10
Total occlusion	10	33.33	14	46.66
Partial occlusion	7	23.33	9	30

In our study, total occlusion was present in **46.66%** of patients intraoperatively.

As compared to **33.33%** in CT scans. Similarly, partial occlusion was found in about 30% intraoperatively and **23.33%** in CT scan. According to our study, **total occlusion** was common pathology found in middle meatus followed by partial occlusion.

**Table 5: Assessment of mucosal disease**

Mucosal thickening	CT Scan		ESS	
	No	%	No	%
Intranasal	10	33.33	12	40
Sinuses	21	71	18	60

In our study, CT scan showed mucosal thickening in **33.33%** intranasal and **71%** in sinuses and the same finding intraoperatively was found in **40%** intranasal and **60%** in sinuses.

**Table 6: Assessment of polypoidal disease**

Polypoidal changes	CT Scan		ESS	
	No	%	No	%
Intranasal	12	40	14	46.66
sinuses	17	56.66	23	76.66

Polypoidal change was most commonly found in **sinuses** as compared to nasal Cavity.

As compared to intranasal polypoidal changes, the polypoidal changes in the Sinuses showed more discrepancy between CT scan (**56.66%**) and intraoperative (**76.66%**) findings.

**Table 7: Assessment of polypoidal changes in individual sinuses**

Polypoidal changes in sinuses	CT Scan		ESS	
	No	%	No	%
Maxillary	11	36.66	15	50
Frontal	3	10	3	10
Anterior ethmoid	13	43.33	12	40
Posterior ethmoid	15	50	15	50

As per table 8 and graph 8 **posterior ethmoid** was commonly involved followed by the anterior ethmoid, maxillary sinus and frontal sinus.

A wide range of discrepancy about **15%** was found in case of maxillary sinus, CT scan **36.66%** and intra Operative **50%**.

**Table 8: Correlation between preoperative CT scan findings and intraoperative endoscopic findings in chronic rhinosinusitis**

Parameters	Sensitivity	Specificity	PPV	NPV	Correlation
OMC-N	100	100	100	100	Excellent
OMC-TO	64.3	93.7	90	75	Poor
OMC-PO	66.7	95.2	85.7	86.9	Poor
MT-N	66.7	88.9	80	80	Poor
MT-S	100	75	85.7	100	Excellent
PC-N	78.5	93.7	91.6	83.3	Acceptable
PC-S	73.9	85.7	94.4	50	Acceptable
M	60	86.7	81.8	68.4	Poor
F	66.7	96.3	66.7	93.3	Poor
AE	91.6	88.9	84.6	94.1	Excellent
PE	86.7	86.7	86.7	86.7	Good

**Sensitivity** of >90 is excellent correlation

>80 is good correlation

> 70 is acceptable correlation

> 60 is poor correlation

Excellent correlation was found in cases of **normal osteomeatal complex (OMC-N) and mucosal thickening in sinuses (MT-S) and polypoidal change in Anterior ethmoid (AE)**. Correlation was good for **polypoidal change in Posterior Ethmoid (PE)**. Correlation was acceptable for **Polypoidal changes in Nasal cavity and sinuses (PC-N) and (PC-S)**. Correlation was poor for **Osteomeatal complex Total occlusion (OMC-TO), partial occlusion (OMC-PO), mucosal thickening in Nasal cavity (MT-N), polypoidal changes in Maxillary (M) and frontal sinus (F)**

**Table 9: Kappa's measure of agreement and 'p' value**

	Kappa's value	Agreement	P value	Statistical significance
OMC-N	1.0	Very good	0.000	Significant
OMC-TO	0.591	Moderate	0.001	Significant
OMC-PO	0.661	Good	0.000	Significant
MT-N	0.571	Moderate	0.002	Significant
MT-S	0.783	Good	0.000	Significant
PC-N	0.730	Good	0.000	Significant
PC-S	0.478	Moderate	0.005	Significant
M	0.467	Moderate	0.008	Significant
F	0.630	Good	0.001	Significant
AE	0.795	Good	0.000	Significant
PE	0.733	Good	0.000	Significant

**Kappa's Value**

**0.81 - 1.0** is very good agreement between CT scan and operative findings

**0.61 - 0.80** is good agreement

**0.41 - 0.60** is moderate agreement

**0.21 - 0.40** is fair agreement

**<0.2** is poor agreement.

**<0.01** no agreement

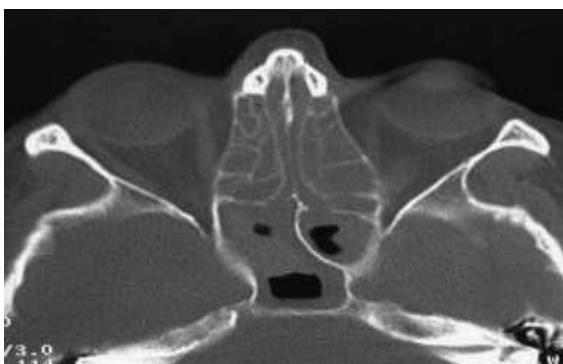
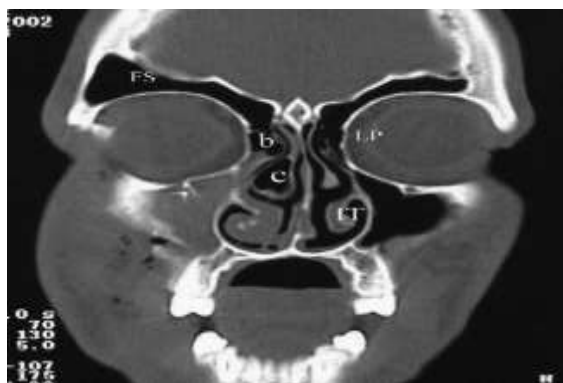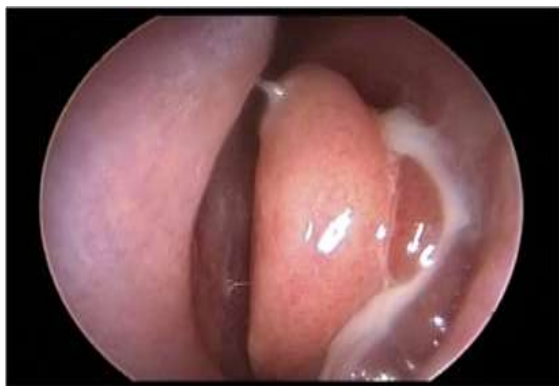**Normal osteomeatal complex** showed VERY GOOD agreement between preoperative CT scan and operative findings. **Osteomeatal complex partial occlusion (OMC-PO), mucosal thickening in sinuses (MT-S), polypoidal changes intranasal (PC-N),**

**polypoidal changes in frontal (F), anterior ethmoid (AE), posterior ethmoid (PO)** showed GOOD agreement.

**OMC total occlusion, mucosal thickening in nasal cavity, polypoidal changes in sinuses and maxillary sinus** showed MODERATE agreement.

**P value <0.05** is statistically significant.

In our study, all parameters were **statistically significant**.



## Discussion

Our study was comparable to study done by **sheetal D, et al** in terms of age distribution and duration of disease, **Zojaji MD, et al** study in terms of sex distribution, OMC-N, mucosal thickening in sinuses, polypoidal changes in nasal occlusion, mucosal thickening in nasal cavity, polypoidal changes in sinuses, polypoidal changes in maxillary sinus. **P value** was significant in all parameters.

## Conclusion

In the present study an attempt has been made to correlate the preoperative CT scan findings and the disparity with intraoperative endoscopic findings in cases of chronic rhino sinusitis. We have tried to find how much CT scan helps in guiding the surgeon during Endoscopic Sinus Surgery. Thorough anatomical knowledge is necessary for the surgeon to correlate the

pre op CT scan findings with intra operative findings during Functional endoscopic sinus surgery.

## References

1. Sheetal. D, Devan P P, Manjunath P, Martin P, Satish Kumar K, Sreekantha, Satisha T G, Manjunath goud. CT PNS – Do we really require before fess? Journal of Clinical and Diagnostic Research. 2011 Apr, Vol-5(2):179-181.
2. R. Zojaji MD, M. Mirzadeh MD, S. Naghibi MD. Comparative Evaluation of Preoperative CT Scan and Intraoperative Endoscopic Sinus Surgery Findings in Patients with Chronic Rhinosinusitis. Iran J Radiol 2008;5(2):77-82.
3. Pawan Singhal, Nishi Sonkhya, Prakash Mishra, Subodh P. Srivastava. Impact of anatomical and radiological findings for consideration of functional endoscopic sinus surgery. Indian journal of otolaryngology and head and neck surgery. October-December 2012,64(4):382-385.
4. Jiannetto DF, Pratt MF. Correlation between preoperative computed tomography and operative findings in functional endoscopic sinus surgery. Laryngoscope 1995 Sept;105(9):924-927
5. Stammberger H, Posawetz W. Functional endoscopic sinus surgery. Concept, indications and results of the Messerklinger technique. Eur Arch Otorhinolaryngol 1990 Feb;247(2):63-76.
6. Sonkens JW, Harnsberger HR. Impact of screening sinus CT on planning of functional endoscopic sinus surgery. Otolaryngol Head Neck Surg 1991,105(6):802-813.
7. A M M Shahizon, A Suraya, Z Rozman, A Aini, B S Gendeh. Correlation of Computed Tomography and Nasal Endoscopic Findings in Chronic Rhino sinusitis, Med J Malaysia 2008;163(3):211-212.
8. Lloyd GA. CT of the paranasal sinuses: study of a control series in relation to endoscopic sinus surgery. J Laryngol Otol 1990 Jun;104(6):477-81.
9. Bolger W, Butzin C, Parsons D. Paranasal sinus bony anatomic variations and mucosal abnormalities: CT analysis for endoscopic sinus surgery. Laryngoscope 1991;101(1):56-64.
10. Vladan Stanojković Correlation between computed tomography and intraoperative finding in functional endoscopic surgery of nose and paranasalsinuses. Acta Medica Medianae 2010,Vol.49(3)19-25.
11. Dua K, Chopra H, Khurana AS, Munjal M. CT scan variations in chronic sinusitis. Indian J Radiol Imaging 2005;15:315-20.
12. Ashok. K. Gupta, Bhumika Gupta, Neha Gupta, Nishikanta Tripathi. Computerized Tomography of paranasal sinuses: A Roadmap to Endoscopic surgery. Clinical Rhinology: An International journal, January-April 2012;5(1):1-10.
13. H. Stammberger, Valerie J Lund, anatomy of the nose and paranasal sinuses. Scott Brown's Otolaryngology. Rhinology. Hodder Arnold 2008;104:1315-1342.
14. Zeiger RS. Prospects for ancillary treatment of sinusitis. In the 1990s. Journal of Allergy and clinical Immunology 1992;90:478-495.
15. David W Kennedy, Zinreich SJ, Rosenbawn AE, Johns ME. Functional endoscopic sinus surgery, Theory and Diagnostic evaluation. Archives of otorhinolaryngology.1985;111:576-582.
16. Bharanagar S, Sharma SC. Surgical treatment for chronic sinusitis whether functional endoscopic sinus surgery has established itself? Indian journal of otorhinolaryngology and head and neck surgery. 2001;53:160-163.