

Study on variations of Foramen Transversarium in 7th cervical vertebrae in the region of Andhra Pradesh – A clinical approach

Shone V. Durge^{1,*}, Nidhi W. Durge², Sangita R. Gosavi³

¹Assistant Professor, ³Professor, Dept. of Human Anatomy, FIMS, Kadapa, Andhra Pradesh, ²Junior Resident, Dept. of Transfusion Medicine, Sent GS Medical College, Mumbai

***Corresponding Author:**

Email: shone_durge@rediffmail.com

Abstract

Introduction: The anatomical knowledge of the variations in the Foramen transversarium of 7th cervical vertebrae can be of immense importance to the neurologists, radiologist, orthopedic surgeons, physiotherapist, for making the right diagnosis and can serve as a helpful guide while performing various surgeries of neck region and for proper interpretation of X-rays and CT scans

Aim: The present study has been undertaken to know the incidence of foramen transversarium in 7th dried cervical vertebrae and the contents passing through it and its clinical significance.

Material and Method: A total number of 106 dried 7thcervical vertebrae were studied.

Result and Discussion: In 36 seventh cervical vertebrae, variations in the Foramen transversarium were observed.

Keywords: Cervical vertebrae, Foramen transversarium, accessory, Bony specule, Cervical ganglion.

Introduction

The transverse foramen is an opening within the transverse process of the cervical vertebrae. Therefore, there is one transverse foramen on each side of the vertebra. The transverse foramen is also commonly called by its latin name, the foramen transversarium. The transverse foramina are not found in the thoracic or lumbar vertebrae. The transverse foramen transmits the vertebral artery and vein as well as the vertebral nerve, a branch from the cervico–thoracic ganglion. However, the transverse foramina in the seventh cervical vertebra (C7) only transmit the vertebral veins. On the rare occasion, the transverse foramina of C7 may transmit the vertebral artery. The Foramen transversarium of seventh cervical vertebra differs from the other cervical vertebrae in the smallness of its size (Moore and Dalley,1999). It transmits only the vertebral vein and a filament (grey ramus) from the inferior ganglion but does not transmit the vertebral artery(Frazer, 1965).

The foramen transversarium may be divided by a bony spicule (Williams et al.,2000) which divides it into two part.

Aim

The present study has been undertaken to know the incidence of foramen transversarium in 7th dried cervical vertebrae and the contents passing through it and its clinical significance.

Materials & Methods

A total number of 106 dried cervical vertebrae of unknown age and sex were collected from the students of 1st M.B.B.S and from the Department of Fatima institute of medical sciences and research Centre. All the collected cervical vertebrae were examined macroscopically for the existence of the Foramen

Transversarium in the 7th cervical vertebrae and the contents passing through it on both sides. The data was then compiled and later analyzed.

Results and Discussion

106 seventh cervical vertebrae were studied for the presence and variations of accessory foramen transversarium. In 36 seventh Cervical vertebrae, variations in the Foramen transversarium were observed (Table 1).

Table 1: Variations in Foramen Transversarium

Accessory foramen transversarium (Bilateral-15)	Accessory foramen transversarium (unilateral- 18)	Absent foramen transversarium 3
Assymetrical-5	Right side 10	Bilateral 1
Symetrical-10	Left side 8	Unilateral 2

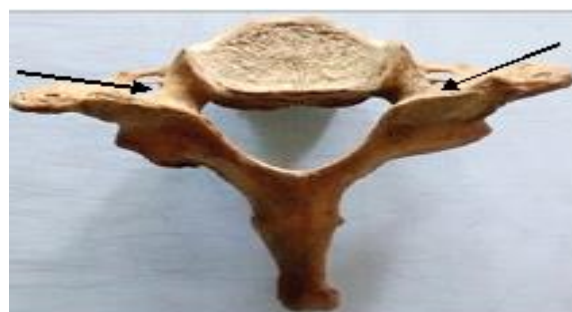

Fig. 1: Arrow pointing towards accessory foramen transversarium (bilaterally)



Fig. 2: Arrow pointing towards accessory Foramen Transversarium (unilaterally)

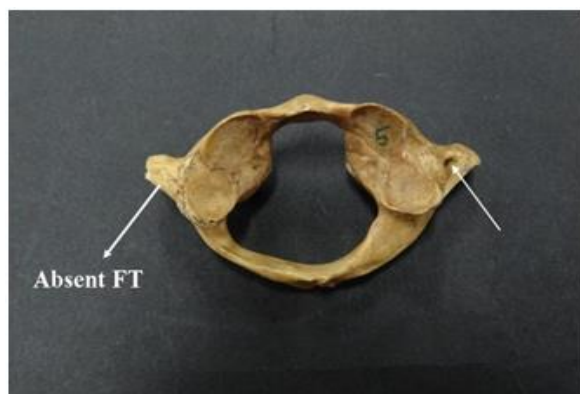


Fig. 3: Absent Foramen Transversarium unilaterally

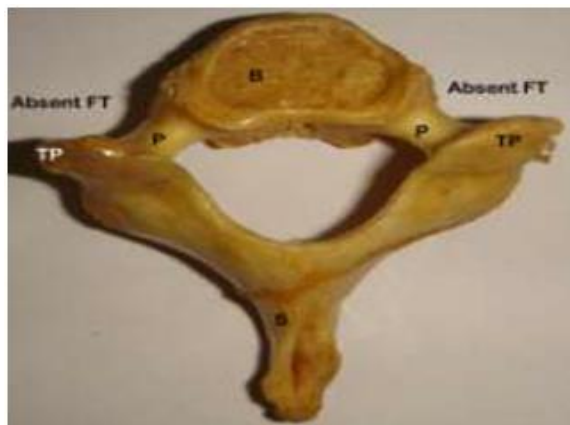

Fig. 4: Absent foramen transversarium bilaterally

Double Foramen Transversarium (FT) is reported by many authors. The incidence of double FT reported by the various authors varies from 1.5% to 23%. The Foramen Transversarium is a result of the special formation of the cervical transverse processes. It is formed by the vestigial costal element fused to the body and the true transverse process of the vertebra. The vertebral vessels and nervous plexus are caught between these two bony parts. The foramen transversarium is closed laterally by the costotransverse bar, and a thin plate of bone connecting the rib element to the original transverse process. Studies have been conducted earlier to study the variations of F.T in

cervical vertebrae (Jovanovic, 1990; Shaaraway *et al.*, 2008). Accessory Foramen Transversarium has been observed in dry skeletons and in cadaver during dissection and reported in C5 & C6 vertebrae (Patasi *et al.*, 2009; Taitz *et al.*, 1978). The present study was undertaken to see the variations in the foramina transversaria of the seventh cervical vertebrae in the region of Andhra Pradesh.

The Foramen Transversarium of the seventh cervical vertebra transmits vascular, nerve branches, fibrous & adipose tissue and is sometimes divided by a bony spicule (Vasudeva and Kumar, 1995; Williams *et al.*, 2000). It may be smaller than the Foramen transversarium of other cervical vertebrae or may be completely absent (Murlimanju *et al.*, 2011). In the present study out of 106 cervical vertebrae, accessory foramen transversarium was present in 33 cervical vertebrae (31.13%) which is less as compared to Bindu Aggarwall and Madhur Gupta (2014) (32.7%). Veeramani and Shankar (2011), out of 31 seventh cervical vertebrae, accessory F.T were observed only in 4 (12.9%) which is less than those observed in the present study. A study conducted by Murlimanju *et al.*, (2011), Wysocki *et al.*, (2003) on 363 typical & atypical cervical vertebrae presented an accessory F.T in 1.6% vertebrae which is very less as compared to present study.

In the present study, the accessory F.T was present bilaterally in 15 and unilaterally in 18 vertebrae (10-right sided and 8 left-sided). In the study conducted by Murlimanju *et al.*, (2011), Wysocki *et al.*, (2003) the incidence of accessory F.T has been reported to be more on the left side while it was more on the right side in the present study, the findings of the present study matches with the study of Bindu Aggarwall and Madhur Gupta (2014), who found that there are more accessory foramen transversarium on right side as compared to left side.

Accessory foramen transversarium might be due to double rib bone element on the same side fusing to the original transverse process resulting in unusual number of F.T (Veeramani and Shankar, 2011). The accessory F.T may be due to variations in the vertebral vessels. The vertebral artery arises from the subclavian artery & usually traverses through the F.T of all cervical vertebrae except the seventh (Frazer, 1965).

The F.T was found to be absent bilaterally in one seventh cervical vertebrae and unilaterally (on left side) in two seventh cervical vertebra. The variations in the number and size of F.T may be an important cause for complaints like headache, migraine and fainting attacks due to compression of the vertebral artery (Hollinshed, 1954). An accessory F.T may narrow the size of real transverse process and may result in pressure on vertebral vessels and sympathetic plexus embedding in it (Taitz *et al.*, 1978).

Conclusion

In the present study, variations were observed in the Foramen transversarium of 36 vertebrae out of the 106 seventh cervical vertebrae that were studied. An accessory F.T was observed in 33 cases while absence of F.T was observed in 3 vertebrae. The reasons for these variations could be improper fusion of the cervical vertebrae, vascular or developmental. The anatomical knowledge of the variations in the Foramen transversarium of 7th cervical vertebrae can be of immense importance to the neurologists, radiologist, orthopedic surgeons, physiotherapist, for making the right diagnosis and can serve as a helpful guide while performing various surgeries of neck region and for proper interpretation of X-rays and CT scan.

Acknowledgements

Work attributed to Fatima medical college and research centre, Kadapa, Andhra Pradesh.

References

1. Bindu Aggarwal and Madhurgupta, Variations of foramen transversarium in seventh cervical vertebrae. *International Journal of Basic and Applied Medical Sciences* 2014 Vol. 4 (2) may- august ,pp 258-262.
2. Shaarawy EA, Sabry SM, Gammaroy T, et al. Morphology and morphometry of the foramina transversaria of cervical vertebrae: A correlation with the position of the vertebral artery. *Egyptian J Med Sci* 2008;29:1133-64.
3. Riew K. Microscope assisted anterior cervical decompression and plating techniques for multilevel cervical spondylosis. *Oper Tech Orthop* 1988;8:22-33.
4. Das S., Suri R, Kapur V. Double Foramen Transversaria: An Osteological Study with Clinical Implications. *Int Med J*. 2005;12:311-313.
5. Chandravadiya L, Patel S, Goda J, Chavda V, Ruparelia S, Patel S. Double foramen transversarium in cervical vertebra: Morphology and clinical importance. *Int J Res Med*. 2013; 2:103-5.
6. Nagar Y, Taitz C, Reich R. What can we make of these fragments? Excavation "Mamilla" Cave, Byzantine period, Jerusalem. *Int J Osteoarchaeol*. 1999;9:29-38.
7. Standring S. The back, in: Susan standing, gray's anatomy. Churchill Livingstone Elsevier, London. 2008;40th Edition:718.
8. Kaya S, Yilmaz ND, Pusat S, et al. Double foramen transversarium variation in ancient byzantine cervical vertebrae: Preliminary report of an anthropological study. *Turk Neurosurg* 2011;21:534-8.
9. Taitz C, Nathan H, Arensburg B. Anatomical observations of the foramina transversaria. *J Neurol Neurosurg Psychiatry* 1978;41(2):170-6.
10. Chaudhari ML, Maheria PB, Bachuwar SP. Double foramen transversarium in cervical vertebra: Morphology and clinical importance. *Indian Journal of Basic & Applied Medical Research* September 2013;2(8):1084-1088.
11. Struthers J. On the variations of the vertebrae and ribs in man. *J. Anat. Phys* 1874;9:17-96.
12. Patra A, Kaur H, Chhabra U, et al. Double foramen transversarium in dried cervical vertebra: An osteological study with its clinical implications. *Indian Journal of Oral Sciences* Jan-Apr 2015;6(1):7-9.
13. Sharma A, Singh K, Gupta V, et al. Double foramen transversarium in cervical vertebra an osteological study. *J. Anat. Soc. India* 2010;59(2):229-231.
14. Rathnakar P, Remya K, Swathi B. Study of accessory foramen transversaria in cervical vertebrae. *Nitte Univ J Health Sci* 2013;3(4):97-9.
15. Katikireddi RS, Setty SN. A study of double foramen transversarium in dried cervical vertebra. *Int J Health Sci Res* 2014;4(1):59-61.
16. Agrawal D, Mohanty BB, Sethy S, et al. Variations in foramen transversarium: an osteological study in eastern India. *International Journal of Current Research* September 2012;4(9):120-122.
17. Murlimanju BV, Prabhu LV, Shilpa K, et al. Accessory transverse foramina in the cervical spine: Incidence, embryological basis, morphology and surgical importance. *Turk Neurosurg* 2011;21(3):384-7.