

Erectile hemangioma: A case report with review of literature

Nikhil M Pradeep¹, Viswanathan V Kollengode², Anoop Sivakumar³, Meer M Chisthi^{4,*}

¹Senior Resident, ²Additional Professor, ³Junior Resident, ⁴Assistant Professor, Dept. of General Surgery, Govt. Medical College, Trivandrum

***Corresponding Author:**

Email: meerchisthi@gmail.com

Abstract

Introduction: Intra-maseteric hemangioma is also known as Erectile Hemangioma because the swelling becomes prominent when the patient masticates. It is a rare benign vascular neoplasm with very limited reports in literature. MRI scan is considered the investigation of choice. Surgical excision is the main modality of treatment.

Case Report: We present a case of 42 year old male who presented with swelling over left side of face near parotid region. On evaluation the patient was found to have hemangioma clinically. After imaging the swelling was suspected to be intra-parotid or intra-maseteric hemangioma. The patient underwent excision of swelling along with parotidectomy on the affected side. Pathological examination confirmed the diagnosis of hemangioma within the maseteric tissue.

Discussion: Surgeons should always consider the possibility of a vascular lesion in the case of patients who present with a compressible swelling in the parotid region especially when there is accompanying pain. Special care has to be taken before sending the patient for a needle biopsy as there can be torrential bleeding. Surgical excision is curative for this disease.

Keywords: Intramuscular; Hemangioma; Erectile hemangioma; Masseter; Parotid

Introduction

Hemangiomas are rare benign vascular neoplasms⁽¹⁾ and are characterized by abnormal proliferation of blood vessels. Though they may occur in any vascularized tissue,⁽²⁾ intramuscular hemangioma are found to be very rare. Till now, only a few cases of hemangiomas have been reported in head and neck region. In the head and neck region itself, it occurs very rarely in oro-facial muscles. There are reported cases of hemangiomas in the digastrics,⁽²⁾ mylohyoid^(1,3) and masseter⁽²⁾ muscles though few in numbers.

Case Report

The patient, a 42 year old male, presented to us with the chief complaints of an insidious onset swelling over left side of face, around the cheek for past 8 years. The swelling was slowly increasing in size since the past 6 months. The patient also reported that the swelling increased in size on bending down and straining. The swelling became characteristically prominent on chewing also. There was no associated pain, trismus or dysphagia. There was no history of any other swellings over the body also.

On examination his vitals were stable and rest of systemic examination was normal. Local examination revealed a fullness in the left side of face extending from the zygomatic arch to the mandible [Fig. 1]. On inspection, the fullness became more prominent on stooping forwards and also on clenching the teeth. On palpation the skin over the swelling was normal with no rise in temperature or tenderness. There was a swelling of size 4x3x2 cm in the left parotid area, which was found to be soft in consistency and compressible, with ill defined margins and borders. On stooping forwards, the swelling increased in size. On clenching the teeth,

the swelling increased in size along with gross restriction of mobility [Fig. 2]. The swelling was not palpable intra orally. No local lymph nodes were palpable. No venous hum or bruit was audible on auscultation.

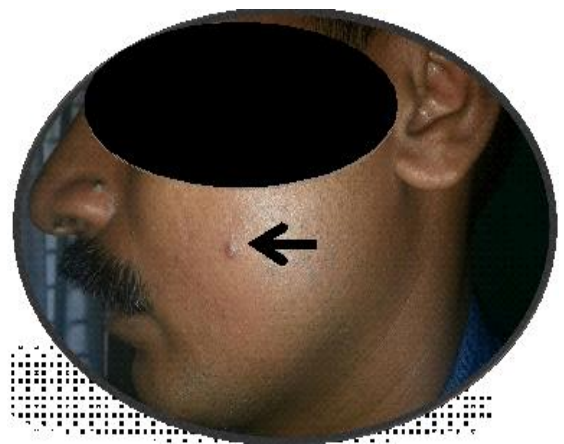

Fig. 1: Swelling over the left side of face and a fullness seen in the parotid region of left side




Fig. 2: Swelling becomes more prominent on clenching the teeth

On investigation his blood investigations were found to be within normal limits. Magnetic Resonance Imaging(MRI) scan was called for and showed an ill defined, altered signal intensity lesion involving the left masseter muscle and parotid gland. The swelling was iso-intense to hyper-intense on T1 and markedly hyper-intense on T2 with hetero-genous mild enhancement post contrast. The lesion was diffusely involving the muscle belly and causing bulkiness of the parotid gland [Fig. 3]. A very small component was noted to be extending into in the left parapharyngeal space. No major vascular feeders of the lesion were seen and the rest of the left masticator space was normal. The report was given as possible intra-masseteric or intra-parotid hemangioma.



Fig. 3: MRI Showing muscle belly involvement and displacing adjacent parotid

On the basis of the clinical and imaging findings, hemangioma was diagnosed and we proceeded with hemangioma excision. Intra-operatively, the hemangioma was found to be located within the masseteric muscle[Fig. 4]. Superficial parotidectomy and excision of the hemangioma along with the

involved masseteric muscle tissue was carried out [Fig. 5]. Post-operative period was uneventful and the patient was discharged after 5 days with a clean wound. The histo-pathological examination confirmed the presence of hemangiomatous tissue within the muscle tissue [Fig. 6]. At 3 months of follow-up, patient was found to be doing well, with no major complaints.

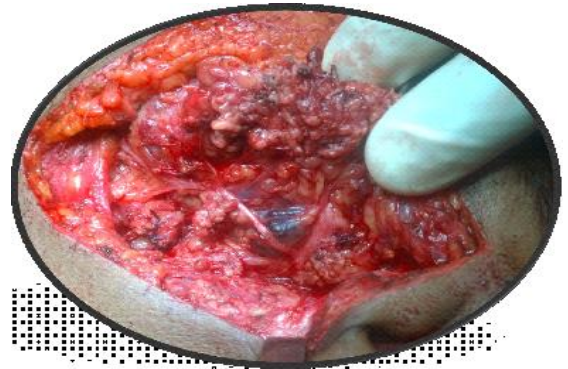

Fig. 4: Intra-operative picture showing dilated vessels suggestive of haemangioma



Fig. 5: Excised specimen showing parotid tissue along with haemangioma

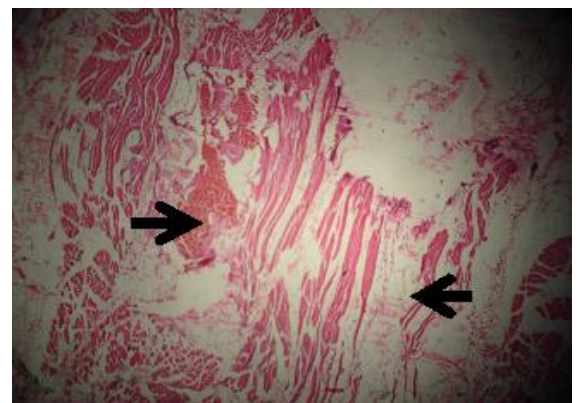


Fig. 6: Histo-pathology picture showing hemangiomatous tissue within muscle (arrow)

Discussion

Hemangiomas are benign vascular neoplasms or hamartomas, which are indigenous to the site of origin. Intramuscular hemangiomas are very rare with masseter muscle accounting for 5% of all intramuscular hemangiomas; other frequently involved muscles are trapezius, extra-ocular muscles, sternocleidomastoid and temporalis.⁽⁴⁾ The first case of intra muscular hemangioma was reported by Listen in 1843. Subsequently other reports have accumulated to a total of 457; of these 63(13.8%) involved head and neck and 23(5.0%) involved the masseter muscle.⁽⁵⁾

Although intramuscular hemangiomas have shown an equal sex distribution, involvement of the masseter has a definite male predominance.⁽⁶⁾ Though various theories have been proposed to explain this observation, none have been proved categorically. The congenital origin hypotheses is supported by the fact that these swellings usually present in the first three decades of life.^(7,8,9) Other researchers have suggested that these lesions arises from malformed tissue which is subjected to repeated trauma.⁽⁷⁾

Allen & Enzinger classified these swellings as large vessel (>140 mm in diameter), small vessel (<140 mm in diameter) and mixed vessel types.⁽¹⁰⁾ They correspond to cavernous, capillary, and mixed type of hemangiomas respectively. This classification is useful and correlates well with the clinical presentation as well as recurrence rates. The capillary type of hemangioma occurs more frequently in the head and neck region. The highly cellular nature of many capillary hemangiomas may explain the lack of clinical signs usually associated with these vascular lesions, thus rendering pre-operative diagnosis difficult. The cavernous and mixed types occur more frequently in the trunk and lower limbs. The mixed type had the greatest tendency for local recurrence: 9 to 28%.⁽¹¹⁾

These tumors present as gradually enlarging mass lesions with a duration often shorter than a year. Accurate preoperative diagnosis has been reported in less than 8% of cases in view of the intramuscular location and due to the overlying parotid gland. Bruits, thrills and compressibility are often absent unlike in other vascular malformations.⁽¹²⁾ The most common clinical presentation is a mass with associated pain symptoms in 50 to 60% of cases. There are usually no skin changes. Clenching the teeth could make the lesion more prominent, more firm and fixed due to the contraction of the masseter.

The 'turkey wattle' sign is an unusual pathognomonic manifestation of intra-masseter and intra-parotid hemangiomas. This refers to enlargement of the lesion with teeth-clenching or with dependent head positioning.⁽¹³⁾ The sign may be due to vascular engorgement within the lesion, which impedes venous return from the head. The turkey wattle is a red vascular structure in the neck of the male turkey that increases in size when filled with blood. Intra masseteric

hemangioma is also called 'Erectile Hemangioma' because the swelling bulges out when the patient chews.⁽¹³⁾ It is to be considered in the differential diagnosis whenever a painful soft tissue lesion within the skeletal muscle of young individual is encountered.

A variety of tumors can be confused clinically with an intramuscular hemangioma. Most of them are often mistaken for salivary neoplasms & the differential diagnosis include cysts, lymphangiomas, rhabdomyosarcomas, schwannomas and even masseteric hypertrophy. MRI and sonography are the important investigations in diagnosing such lesions. MRI has shown superiority in the confirmation and exact delineation of the lesion from its surrounding tissues due to its multi-planar capability. Arteriography is usually not necessary as there rarely is a major arterial component involved in the lesion.

The management of intramuscular hemangiomas should be individualized based on such factors as tumor location, age, depth of invasion and cosmesis. Many less-invasive treatment modalities like cryotherapy, radiation therapy, steroid administration and embolization have been advocated but the treatment of choice still remains surgical excision.^(12,14,15) Parotidectomy is usually added to the excision of the swelling along with resection of the involved muscular tissue.

The pre-auricular incision combined with a superficial parotidectomy allows for a complete excision with preservation of branches of the facial nerve, with very little cosmetic and functional disability. Proximal vascular control can also be achieved through the same incision if required. If major feeders are detected preoperatively, embolisation can be attempted for vascular control. Intraoral approaches give limited exposure to the facial nerve branches and may result in nerve injury and hence are not advocated.⁽¹²⁾

Conclusion

To conclude, this interesting report presents a rare case report of an intra-masseteric hemangioma. Any lesion in the region of the parotid must be evaluated thoroughly prior to surgery. If the swelling appears compressible, FNAC can be withheld before completing imaging. Also, if the FNAC shows a bloody aspirate on repeated sessions, the possibility of a vascular lesion must be thought of and investigations directed accordingly. MRI should be the definitive line of investigation. Parotidectomy with local excision of the swelling has very little cosmetic or functional disability and offers the best possible outcome.

References

1. Chan MJ, McLean NR, Soames JV. Intramuscular haemangioma of the orbicularis oris muscle. *Br J Oral Maxillofac Surg.* 1992;30:192-4.
2. Danielle AK, Timothy AD, David GM. Hemangioma. *Br J Oral Maxillofac Surg.* 2004;32:231-4.

3. Kim DH, Hwang M, Kang YK, Kim IJ, Park YK. Intramuscular hemangioma mimicking myofascial pain syndrome: A case report. *J Korean Med Sci* 2007;22:580-2.
4. Welsh D, Hengerer AS. The diagnosis and treatment of intramuscular hemangiomas of the masseter muscle. *Am J Otolaryngol.* 1980;1:186-90. doi: 10.1016/S0196-0709(80)80014-7.2.
5. Gregory KI, Gerald JB and Allen LS. Intramuscular Hemangioma of the mentalis muscle. *Oral surg Oral Med Oral Pathol.* 1985;60:476-481.
6. Hoehn JG, Farrow GM, Devine KD. Invasive Hemangioma of the Head and neck. *Am J Surg.*1970;120:495-498. doi: 10.1016/S0002-9610(70)80014-9.
7. Ingalls GK, Bonnington GJ, Sisk AL. Intramuscular hemangioma mentalis muscle. *Oral Surg Oral Med Oral pathol.* 1985;60:476-481. doi: 10.1016/0030-4220(85)90232-4.
8. Biller HF, Krespi YP, Som PM. Combined therapy for vascular lesions of the head and neck with intra- arterial embolization and surgical excision. *Otolaryngol Head Neck Surg.* 1982;90:37-47.
9. Rossiter JL, Hendrix RA, Tom L, Potsic W. Intramuscular hemangioma of the Head and neck. *Otolaryngol. Head Neck Surg.* 1993;108:18.
10. Allen PW, Enzinger FM. Hemangioma of skeletal muscle; an analysis of 89 cases. *Cancer.* 1972;29:8-22. doi: 10.1002/1097-0142(197201)29:18.
11. Narayanan CD, Prakash P and Dhanasekaran CK, "Intramuscular hemangioma of masseter muscle: A case report," *Cases J.* 2009;2:7459. doi: 10.1186/1757-1626-2-7459.
12. Wolf GT, Daniel F, Krause CJ, Kaufman RS. Intramuscular Hemangioma of the head and neck. *Laryngoscope.* 1985;95:210-213. doi: 10.1288/00005537-198502000-00018.
13. Saeed WR, Kolhe PS, Smith FW, et al. The 'turkey wattle' sign revisited: diagnosing parotid vascular malformations in the adult. *Br J Plast Surg* 1997;50:43-6.
14. Watson WL, Mc Carthy WD. Blood and lymph vessel tumors; a report of 1056 cases. *Surg Gynecol Obstet.* 1940;71:569-588.
15. Sayan SB, Kogo M, Kouzimi H, et al. Intramuscular Hemangioma of the digastric muscle. *J Osaka Univ Dent Sch.* 1992;32:14-40.