

Morphometric Study of the Third ventricle of Brain by Computed Tomography in Hydrocephalic children in tertiary hospital of Telangana

Radhakrishna Palla

Assistant Professor, Dept. of Anatomy, RVM Institute of Medical Sciences & Research Centre, Siddipet, Hyderabad

***Corresponding Author:**

Email: drradhaeradhae@gmail.com

Abstract

Background: Aim of the study was to determine the morphometric measurement of the third ventricle of brain by computed tomography in hydrocephalic children, and to assess its importance in different age groups.

Materials and Methods: The study group included CT Scans of 50 normal and 50 hydrocephalic children between 0-12 yrs attending the Department of Radiology, Niloufer hospital Hyderabad Telangana between November 2013 to August 2014. Maximum width of the third ventricle were measured and statistically analyzed.

Results: Out of 50 Hydrocephalic cases 24 (48%) were males and 26 (52%) were females, 31 were below 3 years and 19 were above 3 years. In the present study including 50 hydrocephalic children below the age of 12yrs, the mean of third ventricle width (14.08+/-5.92,95 %CI 12.91-15.24 mm) was higher than the mean of control group (3.81+/-0.46,95% CI 3.72-3.9). Mean of Third ventricle width in males (11.61+/-4.8,95 %CI 9.32-13.9mm) is less than Mean of Third ventricle width in females (14.15+/-6.6,95% CI 11.48-16.82mm). Mean of Third ventricle width in children below 3yrs (15.35+/-6.23,95%CI 13.92-16.77mm) is more than Mean of Third ventricle width in children above 3yrs (11.61+/-4.45, 95%CI 9.0-13.31mm).

Conclusions: The study shows significant difference in width of third ventricle among cases and controls. Among the hydrocephalic children there was a significant difference in the above age groups.

Keywords: Hydrocephalic children, Third ventricle.

Introduction

Hydrocephalus is often referred to as “Water on the Brain”, derived from two Greek words “Hydro” meaning water, “Cephalus” meaning head. Obstruction in the circulation of CSF leads to accumulation of fluid within the ventricular system which causes compression of brain.⁽¹⁾ Archaeological surveys have shown the evidence of hydrocephalus since ancient times. The overall incidence of hydrocephalus is not known. Morphometric analysis of cerebral ventricular system is important for evaluating changes due to growth, aging, intrinsic and extrinsic pathologies.⁽²⁾ Computerized axial tomography is a safe non-invasive technique which can be utilized for morphometrical evaluation of the ventricles.³ The present work was undertaken to analyse the morphometry of Third ventricle of brain in hydrocephalic children by CT scan method.

Material and Methods

On approval from ethical committee CT scans of 50 cases of hydrocephalic children of age group 0-12 yrs. were studied for a period from November 2013 to August 2014 attending department of Radiology, Niloufer Hospital for women and children, Hyderabad Telangana. 50 normal CT scans of same age children collected randomly were included as control group.

Exclusion Criteria

- CT scans of teenagers and adults.
- CT scans of trauma, head injury.
- CT scans showing intracranial hemorrhage.
- CT scans of patients with previous head surgeries.

Computed tomography of these patients was performed on Toshiba, Aquilion, TSX-101A, Multi slice Detector CT scanner with a scan time of 0.5sec and slice thickness of 5mm. A constant 120kvp station was used. Routine scanning was done on 360 degree standard scan with the following scan parameters.

CT machine specifications

- Scan protocol: Axial; Patient position: supine; Direction: cranial to caudal; Slice thickness: 5 mm Voltage: 120kvp; Scan time: 0.5sec; Rotation time: 0.5sec; Resolution: standard; Slice increment: 0.5mm; Rotation: 12.5mm; Table position: 50mm; m As: 150 m As/slice.

The patient was placed on CT table in supine position. The table was adjusted in required position using the push button to manipulate the table position; the patient was centralized and supported for correct alignment and to reduce blurring images. Head was centered to the criss cross point of the light beam at external auditory meatus. The vertical light beam was made to coincide with the orbitomeatal line. This position represents the table zero position. The gauze pads were kept on either side of the head and the head band was placed across the forehead to immobilize the head.

- The following CT scan parameters were used in the study: Maximum width of Third ventricle.

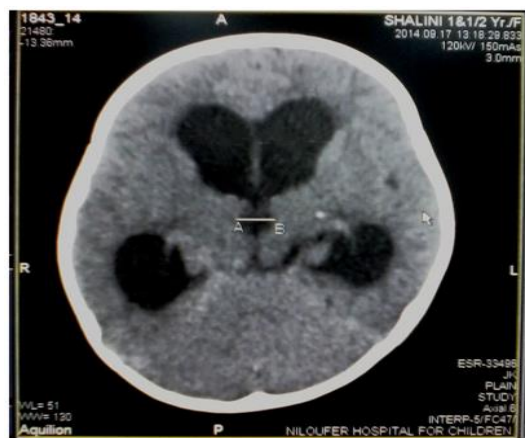

Fig. 1: CT scan of 18 months old female showing grossly dilated Third ventricle. A-B Maximum width of the Third ventricle

Results

Table 1: Measurement of the Third ventricle

| Name of the parameter | Cases | Control |
|---------------------------------------|-------|---------|
| Third ventricle width (mm) Mean | 14.08 | 3.81 |
| Standard deviation | 5.92 | 0.46 |
| 95 %confidence interval (upper limit) | 15.24 | 3.9 |
| 95% confidence interval (lower limit) | 12.91 | 3.72 |

Mean third ventricle width in cases (14.08+/-5.92, 95% CI 12.91-15.24mm) is more than in controls (3.81+/-0.46, 95% CI 3.72-3.9) Z test =12.23; p<0.0001, 95% upper=0.642, Lower = -5.723 Z test =12.4. P<0.0001 shows there Significant difference in two groups in terms of mean of the third ventricle width.

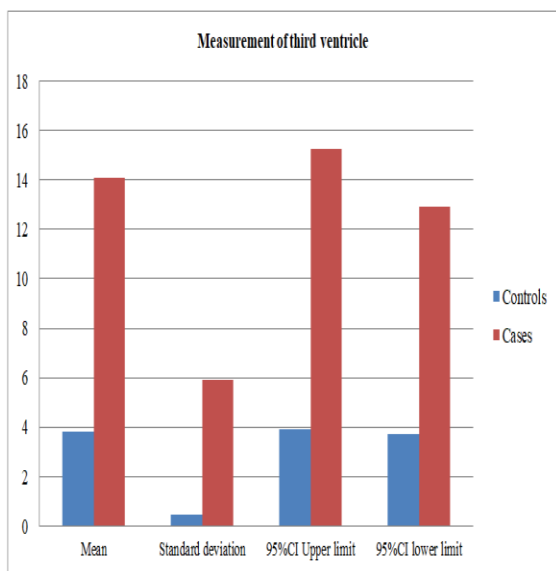


Chart 1: Shows the measurements of Third ventricle.

Table 2: Measurement of the Third ventricle in Hydrocephalic children according to gender

| Name of the parameter | Males | Females |
|---------------------------------------|-------|---------|
| | cases | cases |
| Third ventricle width (mm) Mean | 11.61 | 14.15 |
| Standard deviation | 4.8 | 6.6 |
| 95% confidence interval (upper limit) | 13.9 | 16.82 |
| 95% confidence interval (lower limit) | 9.32 | 11.48 |

Mean of Third ventricle width in males (11.61+/-4.8,95%CI 9.32-13.9mm) is less than Mean of Third ventricle width in females (14.15+/-6.6,95% CI 11.48-16.82mm; Z= -1.565 ; P= 0.117 ; 95% upper=0.642; Lower = -5.723.

Z test = -1.56, P = 0.117 shows No significant difference in two groups in terms of mean of the third ventricle width.

Table 3: Measurements of the Third ventricle in Hydrocephalic children according to age

| Name of the parameter | Below 3yrs | Above 3yrs |
|---------------------------------------|------------|------------|
| | cases | cases |
| Third ventricle width (mm) Mean | 15.35 | 11.61 |
| Standard deviation | 6.23 | 4.45 |
| 95% confidence interval (upper limit) | 16.77 | 13.31 |
| 95% confidence interval (lower limit) | 13.92 | 9.0 |

Mean of Third ventricle width in children below 3yrs (15.35+/-6.23,95%CI 13.92-16.77mm) is more than Mean of Third ventricle width in children above 3yrs (11.61+/-4.45, 95%CI 9.0-13.31mm) Z = 2.470 ; p= 0.013 95% CI Upper =6.709 lower0.771

Z test =2.47, P =0.013 shows Significant difference in two groups in terms of mean of the Third ventricle width.

Discussion

- In the present study including 50 Hydrocephalic children below the age of 12yrs, the mean of third ventricle width (14.08+/-5.92,95%CI 12.91-15.24 mm) was higher than the mean of Control group(3.81+/-0.46,95%CI 3.72-3.9). Z test =12.4 shows Significant difference in width of Third ventricle between two groups in terms of mean P<0.0001
- Mean of Third ventricle width in Males (11.61+/-4.8,95 %CI 9.32-13.9mm) is less than Mean of Third ventricle width in Females (14.15+/-6.6,95% CI 11.48-16.82mm). Z= -1.565; P= 0.117, 95% upper=0.642 Lower=-5.723. Among the hydrocephalic children there is No significant

difference in width of Third ventricle between Males and Females. $P=0.117$

- Mean of Third ventricle width in children below 3yrs (15.35 \pm 6.23,95%CI 13.92-16.77mm) is more than Mean of Third ventricle width in children above 3yrs (11.61 \pm 4.45, 95%CI 9.0-13.31mm). $Z = 2.470$; $P= 0.013$, 95% CI Upper =6.709 lower = 0.771. Among the Hydrocephalic children there is significant difference in width of Third ventricle between two age groups. $P= 0.013$
- P Meese et al (1976)⁽⁴⁾ stated width of the third ventricle as the maximum transverse diameter of the third ventricle. In their study including 260 hydrocephalic children gave a proposal for grading of the ventricular dilatation in hydrocephalic children, which show normal (3-5mm), slight dilatation (6-8mm), moderate dilatation (up to 10mm), and extreme dilatation (over 10mm). In Present study the width of third ventricle was 14.08 \pm 5.92mm, which comes under the grading of extreme dilatation.
- Pedersen H et al(1979)⁽⁵⁾ in a study including 155 normal children below age of 15 years found that the mean third ventricle width in children below 3yrs as 6.6 mm and in children above 3yrs a mean of 5.0 mm.
- Venkataramana et al(2011)⁽⁶⁾ in a study including 25 congenital hydrocephalic children below 6 months of age found the mean third ventricle width of 4.96 mm.

Conclusion

There is Significant difference in width of Third ventricle between Hydrocephalic cases and controls of age 0-12yrs and also there is Significant difference in width of Third ventricle among hydrocephalic children of age 0-12 yrs. but there is No significant difference in width of Third ventricle between Males and Females.

References

1. Standring S, Gray's Anatomy The Anatomical Basis of Clinical Practice 40thedition, Churchill Livingstone Elsevier:2008.
2. Aziz,Aamer , Hu, Qing M, Nowinski, Wieslaw L, Morphometric analysis of cerebral ventricular system from MR images.Med Imag2004;5369:574-82.
3. Torkildsen A. The gross anatomy of lateral ventricles. J Anatomy1934;68:480-91.
4. Meese W, Lanksch W, Wende S. Diagnosis and postoperative follow-up studies of infantile hydrocephalus using computerized tomography. Cranial computerized tomography, Springer-Verlag Berlin Heidelberg 1976.
5. Pedersen H, Gyldensted M and Gyldensted C, Measurement of the normal ventricular system and supratentorial subarachnoid space in Children with computed tomography. , Neuroradiology17,231-237 (1979).
6. Venkataramana .N.K., Mukundan C.R. Evaluation of functional outcomes in congenital hydrocephalus. J Pediatric Neuroscience;6:4-12.,2011.