

Anatomy of surgical presigmoid approach

JAUME Alejandra¹, ROMERO Mariana², DEVITA Andrea³, MARTINEZ Fernando⁴, SPAGNUOLO Edgardo⁵

⁴Associate Professor, ⁵Professor & Chairman, Dept. Of Neurosurgical, ^{1,2,3,5}Maciel Hospital, School of Medicine, Republic University, Montevideo, Uruguay, ⁴Clinical Hospital

***Corresponding Author:**

Email: spagjohn@yahoo.com

Abstract

Introduction: Presigmoid approach is defined as one that allows access to the middle and posterior fossa in front of the sigmoid sinus via transmastoid. The following is a descriptive work of the most important steps to consider during anatomical aspects of this approach.

Materials and Methods: Presigmoid approach was performed in 4 heads cadavers fixed in formalin solution cadavers, match with the help of electric drill and microscope magnification.

Results and Discussion: Starting 1cm skin incision above the zygoma and reaching mastoid 3cm below was performed. The temporalis and trapezius muscles forward and ECM back to expose the skull. The path of the transverse sinus topography by a line joining theinion supramastoid the crest. The dome of the sigmoid sinus level asterion and its drive shaft mastoid before emptying into the jugular gulf. The facial nerve was found on the tympanic and mastoid portion at the end of the mastoidectomy. After completing the craniotomy bone flap and lift the dural opening was performed with ligation of the superior petrosal sinus and tentorium section under a microscope to visualize the IV cranial nerve.

Conclusions: This approach allows access to complex regions in the skull base and the petroclival region. Anatomical knowledge is essential to minimize morbidity of the approach for injury to neurovascular structures.

Keywords: Approaches, Temporal bone, Transpetrosal, Presigmoid, Facial nerve surgery.

Introduction

The choice of the approach for a surgery is a fundamental step that the Neurosurgeon must perform, knowing that surgical success begins with a correct selection of the approach, depending on the topography and characteristics of the lesion. The different types of neurosurgical approaches have been reviewed and analyzed for decades. The present study proposes updating the definition, indication, and surgical anatomy of the presigmoid approach.

The presigmoid approach is defined as the combined supra and infratentorial approach centered on the mastoid; with different variants depending on the degree of resection of the mastoid, and the labyrinthine portion.⁽¹⁾ Usually the most used technique is the presigmoid approach with minimal mastoidectomy,⁽²⁾ which only exposes the dura mater of the posterior and middle fossa, without drilling other sectors, in order to preserve adjacent structures, and prevent injuries. In any case, said approach will depend on the size, and characteristics of the lesion, as well as on the patient's clinic.⁽⁴⁾ If necessary, you can go forward in the drilling and depending on it the name they receive. We speak of a transmastoid, retrolabyrinthine presigmoid approach⁽⁶⁾ when a wide mastoidectomy is performed, until exposure of the otic capsule and sigmoid sinus.⁽⁸⁾ The transpetrosal presigmoid approach, also called posterior petrosal approach, can be: partial translabyrinthine⁽¹³⁾ (drilling of the posterior and superior semicircular canal, with preservation of the lateral semicircular canal); total translabyrinthine⁽¹⁵⁾ (resection of the lateral semicircular canal with skeletation of the tympanic and mastoid

portions of the facial nerve); and / or transcochlear (drilling of the cochlea with exposure of the labyrinthine portion of the facial).⁽¹⁴⁾

Regardless of the variant used for this approach, this constitute a combination of the retrosigmoid and subtemporal approach, with the aim of reaching lesions that encompass the medial sector of the infra and supratentorial fossa.⁽¹⁶⁾

Materials and Methods

Four heads were obtained corresponding to shaped adult corpses, without previous neurosurgical pathology. In each one, the presigmoid approach was performed with its different variants, with the help of an electric drill and a magnifying microscope. From the beginning of the approach, in each plane, important anatomical repels were analyzed to reduce the surgical risk.

Results

A classic incision was planned in the skin, starting 1cm above the zygoma, with the form of a C accompanying the arrangement of the auricular pavilion, reaching up to 3cm below the mastoid. The temporalis muscle was rocked forward and the trapezius and sternocleidomastoid muscle (ECM) backwards to expose the skull.

At the bone level, important anatomical repeaters were used to locate the transverse and sigmoid sinus tract. The transverse sinus was topographed by a line joining the supramastoid crest (CS) to theinion. The sigmoid sinus should be topographed both at the level of its upper edge and also at the level of its lower edge to

avoid injury to it. The upper border is located at the junction of the squamous suture (SE) with the parieto-mastoid suture (SPM); and the lower border was topographed at the asterion level (union of the parieto-occipital, parieto-mastoid, and occipito-mastoid suture) (Fig. 1).

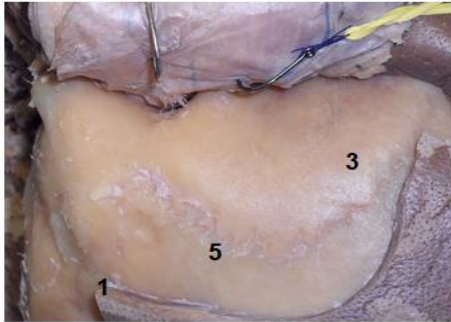


Fig. 1: Surgical position: Left upper view of the skull.. 1, asterion; 2, inion; 3, cresta supramastoid crest; 4, Scamous suture; 5, parieto-mastoid suture

After overcoming these structures, the mastoidectomy was performed, tracing a lower base triangle, whose limits are: a) supramastoid crest; b) line passing in the mastoid axis adjacent to the digastric groove (RD), and, c) external auditory canal (CAE) (Fig. 2).

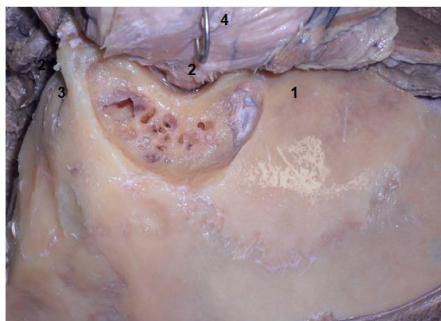


Fig. 2: Surgical position: Left upper view of the skull.. 1, cresta supramastoid crest; 2, External auditive conduct; 3, ranura digastric groove

In different corpses, the variants of the presigmoid approach described above were performed. Once the mastoidectomy and its variants have been completed; craniotomy was performed at supra and infratentorial level. The bone flap was lifted (Fig. 3), and perform the opening of the dura mater: at the subtemporal level above and parallel to the superior petrosal sinus, and at the level of the Trautman's Triangle (limited by the sigmoid sinus below, and the superior petrosal sinus above) to access the posterior fossa, with ligation of the superior petrosal sinus and section of the tentorium under a microscope to visualize the trochlear nerve or IV cranial nerve.

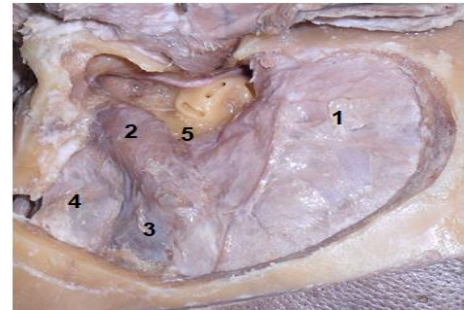


Fig. 3: Left upper view: craniotomy. 1, supratentorial dura matter; 2, seno sigmoid sinus; 3, transvers sinus; 4, retrosigmoid posterior fossa dura matter; 5, presigmoid posterior fossa dura matter

Discussion

It is important to analyze and know the different surgical approaches, given that each one has a different indication according to the pathology, for the field of work that they allow. The presigmoid approach is one of the most used approaches in petroclival pathologies¹⁸. The petroclival region for surgical purposes, can be divided into 3 sectors: a) superior clivus, it is topographed above a point that crosses the sixth cranial nerve, and includes the sellar dorsum; b) middle clivus, extends from the VI to the IX cranial nerve; and c) inferior clivus, which extends from the IX cranial nerve to the Foramen Magno. In turn, the petrous portion of the temporal bone, to locate injuries, and decide the surgical approach to be used, can be divided into two sectors⁽³⁾: a) medial, inside a line drawn between the Meckel Cavum and the Foramen Magnum; and b) lateral, outside of this.⁽²⁾ If the lesion is topographed in the medial sector, most authors recommend a transpetrosal approach.⁽¹⁹⁾ If the lesion is lateral to this line, it can be accessed by performing a retrosigmoid, which has lower morbidity.

If a petrosal approach is defined for a medial lesion, we must decide what type of petrosal approach is appropriate. If the lesion is at the level of the upper third of the clivus, with or without extension to the middle fossa, and does not descend beyond the internal auditory canal (IAC), it is recommended to perform an anterior approach, also called anterior petrosectomy, or Kawase approach, which allows extradural exposure of the superior surface of the petrosal bone at the level of the middle fossa.⁽¹⁷⁾ This approach is of choice in extradural lesions, since the amplitude of the work field is not very large. This approach is carried out by means of a subtemporal, extradural (peeling of the middle fossa), where the Kawase triangle was surveyed. Said triangle is limited by: a) the greater superficial petrosal nerve and the internal carotid nerve in its petrous portion, outward; b) the Gasser ganglion inwards; and c) the cochlea, backwards. The cochlea was topographed in a triangle formed by: the facial nerve in its labyrinthine segment, with the geniculate ganglion, and the birth of the greater superficial petrosal nerve

(Fig. 4). The Kawase triangle can be drilled without risk of injury, accessing the posterior fossa from the middle fossa.⁽¹⁵⁾

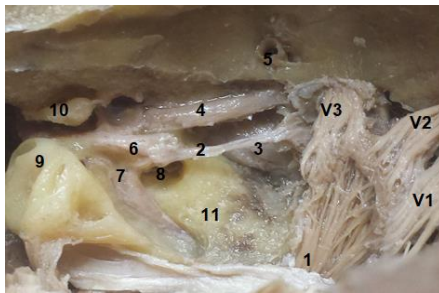


Fig. 4: Skull left upper view: surgical position; 1, Gasser gangly (V1, V2, V3); 2, nervio petrosal bigger superficial; 3, carótida interna petrosal internal carotid artery; 4, tensor muscle of tympanun cord; 5 middle meningeal artery; 6, geniculate gangly; 7, facial nerve: laberinthic section; 8, Choclea; 9, conductos semicirculars conductus; 10; yunque; 11, Kawase triangle

If the lesion is topographed at the level of the middle third of the clivus, or is intradural, the anterior petrosectomy does not allow a correct display of the lesion, therefore, it is preferable to perform a posterior petrosectomy.⁽¹¹⁾

The posterior transpetrosal approach refers to a presigmoid approach. Nowadays, the most used is the presigmoid, transmastoid, retrolabyrinth, which implies mastoidectomy, leaving the otic capsule intact, opening the dura mater behind the labyrinth, at the Trautman's triangle level.⁽⁷⁾ If more amplitude is required, the approach can be expanded with a partial translabyrinthine, total translabyrinthine, or transcochlear.⁽⁵⁾ This is currently in disuse due to the safe loss of hearing, and the risk of injury to the facial nerve.

This approach has key points to achieve the necessary work amplitude, and not injure important neurovascular structures. When the approach is planned, from the superficial planes, it is essential to perform the muscle-cutaneous opening with the closure in mind, to avoid a complication, such as cerebrospinal fluid fistula, in this surgery. In our corpses, we recline the temporal muscle upwards and the ECM downwards.

In bone time, it is important to recognize all the repels mentioned above. There are authors who recommend performing the temporal and retromastoid craniotomy first, being able to make 4 holes (2 above and 2 below the sinus), and after lifting the bone flap, begin the mastoidectomy.⁽¹⁰⁾ Other authors recommend performing the mastoidectomy initially, to ensure the topography of the sigmoid sinus and reduce the risk of injury, and once that breast is discovered, perform the craniotomy.⁽⁹⁾ In our corpses we begin with the mastoidectomy and then the craniotomy.

Before beginning the mastoidectomy it is important to regain the spine of Henle (EH), since in the depth of

it, the lateral semicircular canal and the facial nerve in its tympanic and mastoid portion were topographed. Mastoidectomy is started at the level of the mastoid antrum, drilling the mastoid cells, until compact bone appears. Continue with mastoid drilling until the sigmoid sinus (SS) is exposed, and the otic capsule. Here the most important thing is the valuation of the triangle of Trautman's (TT), since it is where the dural opening is made to access the posterior fossa.

If this triangle is small, it can be assessed according to the characteristics of the lesion and the patient's clinic, expanding the field of work to improve the angle of attack of the lesion, performing: a partial translabyrinth, total translabyrinthine, or transcochlear.⁽⁵⁾ In case of needing to expand the approach, one should start by drilling the otic capsule until exposing the semicircular canals (Fig. 5), and then drilling: the upper semicircular canal (wide to the middle fossa), and the posterior semicircular canal (wide toward posterior fossa) keeping the lateral semicircular canal intact until facial exposure is achieved in its tympanic and mastoid segments (Fig. 6). The facial nerve has five parts: cisternal, meatal, labyrinth, tympanic, and mastoid, being able to recognize up to the meatal segment from this approach. In the usual approaches, try to expose as little as possible the facial, to avoid injury.

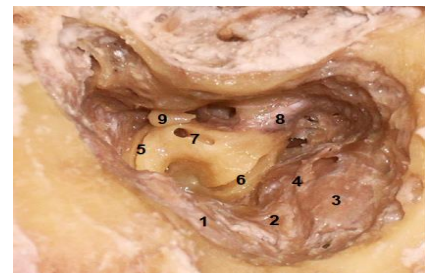


Fig. 5: Skull right superior view: surgical position. 1, supratentorial dura matter; 2, seno petrosal superior sinus; 3, seno sigmoid sinus; 4, Trautman's triangle; 5 Superior semicircular conduct; 6 posterior semicircular conduct; 7 lateral semicircular conduct; 8, facial nerve: porción mastoid section; 9, yunque

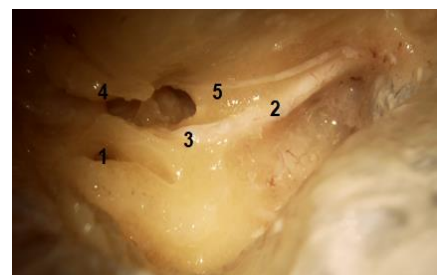


Fig. 6: Skull right superior view: surgical position 1, lateral semicircular conduct; 2, facial nerve, porción mastoid section; 3, facial nerve, timpanic section; 4, yunque, 5, tympanum cord nerve

Once the facial is recognized in its tympanic and mastoid trajectory, the lateral semicircular canal can be

drilled, as well as the structures of the middle ear (anvil, stirrup, hammer, tympanic membrane) until the promontory is exposed. Then the drilling of the cochlea is performed, knowing its relation forward with the petrosal carotid, where it passes from its vertical segment to horizontal. Once the cochlea has been drilled, the labyrinthine segment of the facial can be seen between the cochlea and the lateral semicircular canal, and the geniculate ganglion, which marks the boundary between the labyrinth and tympanic segment of the facial.⁽¹²⁾ (Fig. 7).

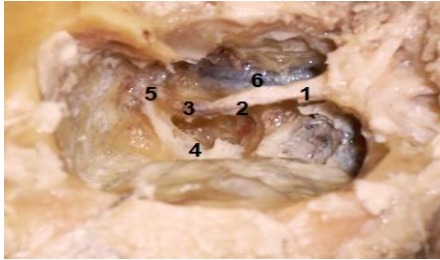


Fig. 7: Skull right superior view: surgical position 1, facial nerve, porción mastoid section; 2, facial nerve, timpanic section; 3, facial nerve, laberinthic section; 4, facial nerve, meathal section; 5, geniculate gangly; 6, petrosal internal carotid artery

During the bone time of this approach, there are mainly two neurovascular structures that can be injured if the surgical anatomy is not clear, and they are: the sigmoid sinus, and the facial nerve.

If the Trautman's triangle allows us a good field of work, the bone time is finished and the dural opening is made. Initially, the dura fossa of the middle fossa is opened, at the subtemporal level, parallel to the superior petrosal sinus, until the vein of Labbé is topographed. Once the indemnity of the vein is assured, the dura mater is opened at the posterior fossa level, in the triangle of Trautman's, parallel and inferior to the superior petrosal sinus. After opening the dura in both sectors, the superior petrosal sinus is ligated, continuing with the opening of the dura mater at the level of the tentorium until it reaches the free edge thereof, previously identifying the IV cranial nerve to avoid its injury (Fig. 8 & 9). Once the cut of the tentorium is made, the exposition of this approach is achieved, to begin the resection of the lesion.

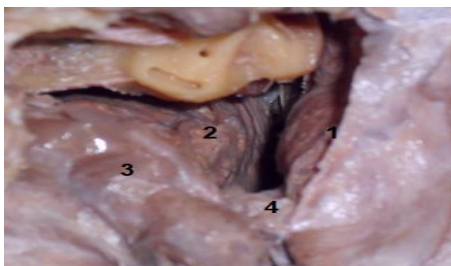


Fig. 8: Left upper view. 1, Temporal lobe; 2, cerebelum; 3, seno sigmoid sinus; 4, petrosal sinus (close)

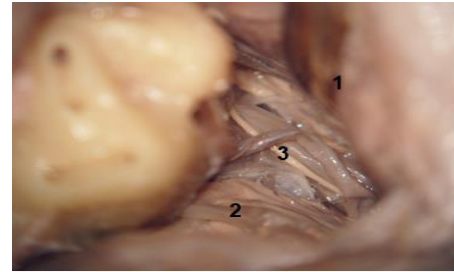


Fig. 9: Microscope view. 1, temporal lobe; 2, cerebelum; 3, chocular nerve

During the dura period, the risk of important neurovascular injuries must be borne in mind, such as the Labbé vein and the trochlear nerve or IV cranial nerve.

Conclusion

This approach allows access to complex regions at the base of the skull such as the petroclival region. It is essential anatomical knowledge, to minimize the morbidity of the approach, by injury of neurovascular structures; knowing that the potentially serious injuries that may occur during this approach are: venous injury (Labbé, and sigmoid sinus), and nerve injury (facial and trochlear).

References

1. A. Perneczky, R. Reisch: Keyhole Approaches in Neurosurgery. Volume 1, cap 3, pag 97-158,2008.
2. A. Rhoton, Cap 8: The Temporal Bone and Transtemporal Approaches. Neurosurgery, vol 47,No 3,211-265, September 2000.
3. A. Rhoton, J. Pulec: Absence of Bone over the Geniculate Ganglion. Neurosurgery 1967,pag48-53.
4. A. Rhoton: Overview of Temporal Bone. Neurosurgery 61:S4-7-S4-60,2007.
5. E. Hanna, F. Demonte: Comprehensive Management of Skull Base Tumors. Cap:1,18, y22,2009.
6. F. Martinez, A. Laxague, L. Vida, H. Prinzo: Anatomia topografica del r. Asterion. Neurocirugía, 2005; 16: 441-446.
7. G. Ribas, A. Rodrigues: The Suprapetrosal Craniotomy. J. Neurosurg 106:449-454,2007.
8. Gulya and Schuknecht's: Anatomy of the Temporal Bone with Surgical Implications. Tercera Edición, 2007.
9. H. R. Winn: Youmans Neurological Surgery. Sexta Edición. Volume 2, cap 116; pag 1275-1282,2011.
10. H. Wen, E. Oliveira, H. Tedeschi: The Pretemporal Approach: Surgical Anatomy, Operative Technique, and Rationale. Neurosurgery vol 4, No 2,2001,pp73-81.
11. J. Tew, H. Van Loveren: Atlas of Operative Microneurosurgery. 2001, cap 1,pag 39-53.
12. L. Sekhar, J. Raso, D. Schessel: The Presigmoid Petrosal Approach. Cap 37,pag 432-465.
13. M. Lehecka, A. Laakso, J. Hernesniemi: Helsinki Microneurosurgery Basics and Tricks. Primera Edición, 2011. Cap5.7:160-169.
14. M. Salcman, R. Heros, E. Laws, V. Sonntag: Kempe's, Operative Neurosurgery, volume 1, segunda edición, cap 21,pag 205-214.
15. M. Sindou: Practical Handbook of Neurosurgery. Volume1,2009,pag233-242.

16. R. Ramina, P. Pires, M. Tatagiba: Samii's Essentials in Neurosurgery. 2008, Cap 12y13, pag 109-136.
17. R. Kockro, P. Hwang: Virtual Temporal Bone: an Interactive 3-Dimensional Learning Aid for Cranial Base Surgery. Neurosurgery 64; ons216-ons230;2009.
18. R. Haberman II: Middle Ear and Mastoid Surgery. 2004
19. V. Dolenc: Microsurgical Anatomy and Surgery of the Central Skull Base. Cap 4.1, pag 185-192, 2003.