



## Case Report

# Uncommon sites of pleomorphic adenoma in salivary glands: Series of 2 cases with review of literature

Madhu Priya<sup>1</sup>, Suji P S<sup>1</sup>, Sumeet Angral<sup>1</sup>, Manu Malhotra<sup>1,\*</sup>, Saurabh Varshney<sup>1</sup>, Manish Kumar Gupta<sup>2</sup>

<sup>1</sup>Dept. of Otorhinolaryngology & Head and Neck Surgery, All India Institute of Medical Science, Rishikesh, Uttarakhand, India

<sup>2</sup>Dept. of Paediatric Surgery, All India Institute of Medical Science, Rishikesh, Uttarakhand, India



### ARTICLE INFO

#### Article history:

Received 1-04-2020

Accepted 13-04-2020

Available online 05-08-2020

#### Keywords:

Pleomorphic adenoma

Salivary gland tumor

Submandibular gland tumor

### ABSTRACT

Salivary gland tumors comprises <3% of the head and neck tumors. Mixed tumor (pleomorphic adenoma) of the salivary gland is a benign tumor arising mainly in the major salivary glands (65%), especially in the parotid and, less frequently, in accessory salivary glands (35%). A small minority (8%) occurs in the oral cavity, neck and nasal cavity. Most common site for minor salivary gland pleomorphic adenoma is palate, though it can also occur in the upper lip, cheek, floor of the mouth, larynx and trachea. Here we report series of 2 cases of pleomorphic adenoma of submandibular gland and floor of mouth respectively. Both are less frequent sites for this pathology.

© 2020 Published by Innovative Publication. This is an open access article under the CC BY-NC license (<https://creativecommons.org/licenses/by-nc/4.0/>)

## 1. Introduction

Salivary gland tumours are rare and its only 1-4% of head- face- neck tumours.<sup>1</sup> Pleomorphic adenoma, is the most common salivary gland tumour. Because of its dual origin of epithelial and myoepithelial elements, pleomorphic adenoma is also known as benign mixed tumour. It constitutes two-third of all salivary gland tumours. Most of the tumours affect the major salivary gland especially the superficial lobe of parotid gland. Submandibular tumour pleomorphic adenoma comprise only 5-10%.<sup>2</sup> Most common site for minor salivary gland pleomorphic adenoma is palate, though it can also occur in the upper lip, cheek, floor of the mouth, larynx and trachea.<sup>3</sup> Intraoral pleomorphic adenoma is a rare slowly growing, painless mass occurring in 4<sup>th</sup> or 5<sup>th</sup> decade with female preponderance.<sup>4</sup>

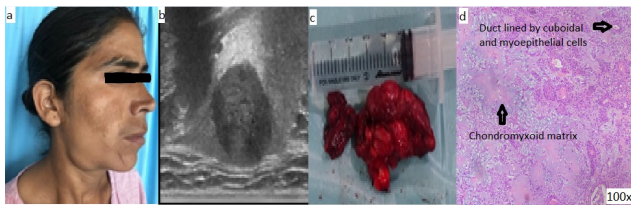
## 2. Case 1

A 27yr old female presented with complaints of swelling in right submandibular region for 2 years. It was a slow growing and painless. On Examination, a firm non tender 3 x 2 cm solitary swelling in right submandibular was present. (Figure 1 a) On intraoral palpation the swelling was ballotable. FNAC done from the swelling revealed pleomorphic adenoma.

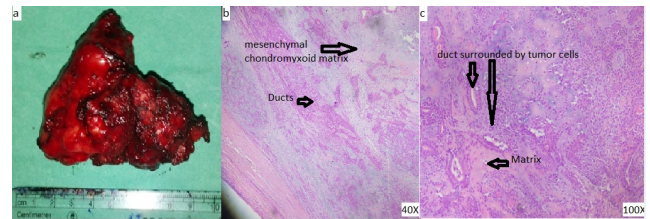
USG neck was suggestive of a well define oval shaped isoechoic lesion within the right submandibular gland. No internal vascularity /calcification/hyperechoic areas/necrotic areas were seen within it. Submandibular duct was not dilated. No cervical lymphadenopathy was noted (Figure 1b). Patient underwent complete excision of left submandibular gland (Figure 1c) and specimen was sent for histopathology examination. Histopathologic sections revealed darkly stained tumour cells lying in chondromyxoid mesenchyme and was reported as pleomorphic adenoma. (Figure 1d)

\* Corresponding author.

E-mail address: manumalhotrallrm@gmail.com (M. Malhotra).



**Fig. 1:** Case 1a) Clinical image of patient showing right submandibular swelling. b) USG image showing well defined isoechoic lesion within rt S/M gland. c) Excised specimen. d) HPE:100x image showing tumor cells in chondromyxoid mesenchyme.



**Fig. 2:** Case 2a) Excised specimen of tumor (pleomorphic adenoma) from floor of mouth. b) HPE 40X image showing ducts and mesenchymal chondromyxoid matrix. c) 100x image showing ducts surrounded by inner cuboidal and outer myoepithelial cells. (signifying pleomorphic adenoma).

### 3. Case 2

A middle-aged male presented with slowly growing painless lump in floor of mouth approximately 12cm X 7cm in size since one and half years. On palpation swelling was firm with a small stony hard area, within. The mucosa overlying the swelling was intact, stretched and shiny. Ventral aspect of tongue was pushed up. No enlarged cervical lymph nodes were noted. FNAC was suggestive of pleomorphic adenoma of floor of mouth. CT scan of the neck with contrast revealed well-defined, mildly-enhancing mass measuring about 10 cm by 5 cm with areas of calcification with probable diagnosis of giant adenoma of floor of mouth. Underlying mandible was normal. The overlying mucosa of lesion was intact. Excision of the mass via mandibular split approach with tracheostomy GA, with the patient in Rose's position was done. The mass was excised with preservation of the overlying mucosa. Incision was closed in two layers with absorbable sutures.

Gross specimen was irregular in shape approximately 10 cm by 5 cm in size. (Figure 2 a) Histopathologically it was reported as giant pleomorphic adenoma of floor of mouth. (Figure 2b,c) Microscopically, the intraoral pleomorphic adenoma lacked a well-defined fibrous capsule. It was composed of epithelial and a mesenchymal component. The epithelial component consisted of tumor cells arranged in ducts, cords and sheets. Ducts were lined by inner cuboidal and outer spindle-shaped myoepithelial cells. The mesenchymal area was hypocellular; composed of stellate and spindle-shaped myoepithelial cells dispersed in a chondromyxoid matrix.

### 4. Discussion

Pleomorphic adenoma of major salivary gland is mostly common in superficial lobe of parotid

gland. Submandibular tumour pleomorphic adenoma comprise only 5-10%. Submandibular gland pleomorphic adenoma presents as a slow growing firm swelling and may be felt as well-defined palpable swelling.<sup>5</sup> Microscopically pleomorphic adenoma has variable appearance, such as mixed proliferation of polygonal epithelial and spindle

shaped myoepithelial cells in stroma matrix. Pleomorphic adenoma lacks true capsule and is surrounded by a fibrous pseudocapsule of variable thickness and having finger like pseudopodia which extends into the normal parenchyma. Submandibular Pleomorphic adenoma are characterized by intact anatomical capsule, infrequent occurrence of pseudopodia and low proportion of myxoid subtype. According to Seifret et al, on basis of stroma-cell proportion histopathologically, pleomorphic adenoma was classified into 3 subtypes; a) Classic (mixed) subtype with stroma content 30-50% b) Stroma rich(myxoid) Stroma content more than 50%, c) Cellular Stroma content less than 30%.<sup>6</sup> Our case of right submandibular gland pleomorphic adenoma underwent complete gland removal. Tumour of submandibular gland are treated with simple excision with preservation of mandibular branch of trigeminal nerve, marginal mandibular nerve, hypoglossal nerve and lingual nerve.<sup>7</sup>

Neoplasms of the minor salivary glands are rare and represent 9%-23% of glandular tumors. The majority (40%-50%) are malignant,<sup>8</sup> with only 18% being benign. Pleomorphic adenoma is commonest benign minor salivary gland tumor. The palate is the most common site, followed by lip, buccal mucosa, floor of mouth, tongue, tonsil, pharynx, retromolar area and nasal cavity. It usually presents as a painless slow-growing mass. The differential diagnosis includes odontogenic and nonodontogenic cysts, soft-tissue tumors, lymphomas and salivary gland tumors. History, physical examination, cytology and histopathology help to establish the diagnosis. CT scan and MRI can provide information of the location, size and extension of tumor to surrounding superficial and deep structure.

The treatment of choice for pleomorphic adenoma in the minor salivary gland is wide local excision with the removal of periosteum or bone if they are involved.<sup>9</sup> Our patient with pleomorphic adenoma of floor of mouth underwent excision of the mass in total with preservation of the overlying mucosa.

High chances of recurrence of pleomorphic adenoma is noticed when incomplete removal or simple enucleation is done. The main reason for this recurrence rate is

presence of pseudopodia or capsular protrusion and satellite nodules. Zbaeren et al used various nomenclature such as: a) complete encapsulation defined as the presence of a fibrous capsule completely encasing the tumour, b) capsule exposure defined as a tumor margin/capsule not surrounded by normal salivary gland tissue, c) pseudopodium defined as a secondary nodule separated by a layer of fibrous tissue from the main tumor mass, but localized within the main tumour capsule, d) finally, satellite nodules are distinct tumour nodules in the vicinity of the main tumour but outside the main tumour capsule, separated from it by salivary parenchyma or fat tissue without any connection to the main tumour.<sup>5</sup> Simple enucleation has a high local recurrence rate. Rupture of the capsule, or tumor spillage - increase the risk of recurrence. Metastatic nature and malignant transformation are rare.<sup>3</sup>

Pleomorphic adenoma usually presents as a solitary mobile slow growing, painless mass. Rapid enlargement of nodule should be considered as malignant transformation until otherwise proved. Malignant potential of Pleomorphic adenoma ranges from 1.5% in first 5 year and 9.5% after 15 year. Long standing lesions have a higher risk for malignancy.<sup>10</sup> The diagnosis is mainly by tissue sampling and imaging.

Tissue sampling includes FNA and Core needle biopsy. The main advantage of these two methods are low tumour seedling rates. Core needle biopsy is more invasive technique but provides diagnostic sensitivity of 97% as compared with FNA which has sensitivity of 90%. Immunohistochemistry will be helpful in delineating the cell components.<sup>11</sup>

Ultrasound appears as hypoechoic lesion with lobulated distinct borders with or without posterior acoustic enhancement.<sup>12</sup> CT scan appears as smoothly margined or lobulated homogeneous soft tissue with few foci of calcifications. MRI appears well- circumscribed homogeneous (smaller tumour) or heterogeneous lesion in larger tumour. Kakimoto et al, in their studies mentioned that tumour capsule was difficult to detect in CT scan and is ease in MRI, so in case of Pleomorphic adenomas MRI is best modality.<sup>13</sup>

## 5. Conclusion

Pleomorphic adenoma of submandibular gland and floor of mouth are rare entities in oral, head neck and maxillofacial region. These should be considered in differential diagnosis of swelling in oral and maxillofacial region. Complete excision is the mainstay treatment to prevent recurrences.

## 6. Source of Funding

None.

## 7. Conflict of Interest

None.

## References

- Smolka W, Eggensperger N, Stauffer-Brauch EJ, Bredow FV, and TL. Pleomorphic adenoma in an atypical location near the temporomandibular joint: A case report. *Quintessence Int.* 2007;38:417–21.
- Rai S, Rohit M, Kaur M, Mukul P. Pleomorphic adenoma: Choice of radiographic imaging modality - Computed tomography or magnetic resonance imaging? Illustration through a case report. *Dental Hypotheses.* 2013;4(1):33–6.
- Bae CH, Kim YD, Song SY. Benign pleomorphic adenoma of the soft palate metastasizing to the sphenoid sinus. *Clin Exp Otorhinolaryngol.* 2010;3(3):172–5.
- Kaur S, Thami GP, Nagarkar NM. Pleomorphic adenoma of the hard palate. *Indian J Dermatol Venerol Leprol.* 2003;69:74–5.
- Noghreyaan A, Gatot A, Maor E, Fliss DM. Palatal pleomorphic adenoma in a child. *J Laryngol Otol.* 1995;109(4):343–5.
- Seifert G, Langrock I, Donath K. Pathomorphologische Subklassifikation der pleomorphen Speicheldrüsenadenome. Analyse von 310 pleomorphen Parotisadenomen. *HNO.* 1976;24(12):415–26.
- Bialek EJ, Jakubowski W, Karpińska G. Role of ultrasonography in diagnosis and differentiation of pleomorphic adenomas: work in progress. *Arch Otolaryngol Head Neck Surg.* 2003;129(9):929–33.
- Noghreyaan A, Gatot A, Maor E, Fliss DM. Palatal pleomorphic adenoma in a child. *J Laryngol Otol.* 1995;109(4):343–5.
- Zbären P, Zbären S, Caversaccio MD, Stauffer E. Carcinoma ex pleomorphic adenoma: Diagnostic difficulty and outcome. *Otolaryngol Head Neck Surg.* 2008;138(5):601–5.
- Schultz-Coulon HJ. Pleomorphic giant adenomas of the parotid gland. *Laryngorhinootologie.* 1989;68:445–9.
- Bokhari MR, Greene J. Pleomorphic adenoma. In: Stat Pearls [Internet. StatPearl Publishing; 2019.
- Kakimoto N, Gamoh S, Tamaki J, Kishino M, Murakami S, Furukawa S, et al. CT and MR images of pleomorphic adenoma in major and minor salivary glands. *Eur J Radiol.* 2009;69(3):464–72.
- Gleave EN, Whittaker JS, Nicholson A. Salivary tumours?experience over thirty years. *Clin Otolaryngol Allied Sci.* 1979;4(4):247–57.

## Author biography

**Madhu Priya** Associate Professor

**Suji P S** Junior Resident

**Sumeet Angral** Senior Resident

**Manu Malhotra** Additional Professor

**Saurabh Varshney** Professor

**Manish Kumar Gupta** Assistant Professor

**Cite this article:** Priya M, Suji P S , Angral S, Malhotra M, Varshney S, Gupta MK. **Uncommon sites of pleomorphic adenoma in salivary glands: Series of 2 cases with review of literature.** *IP Indian J Anat Surg Head, Neck Brain* 2020;6(2):56-58.