



Case Report

Infected laryngeal foreign body: A case report

Vignesh A K¹, Bhumika Trivedi^{1,*}

¹Dept. of ENT, Guru Gobind Singh Medical College and Hospital, Faridkot, Punjab, India



ARTICLE INFO

Article history:

Received 09-12-2020

Accepted 10-12-2020

Available online 20-01-2021

Keywords:

Foreign body
Turban Pin
Laryngitis
Misdiagnosed

ABSTRACT

Introduction: Foreign body aspiration is a major cause of accidental death in children. Laryngeal foreign bodies in some cases, especially when it is narrow cause little airway obstruction and may even present like upper airway infection. This can delay the diagnosis and even may be mis-treated as laryngitis.

Case Report: A child presented to the department of ENT with throat pain and hoarseness of voice but gave a history of foreign body ingestion 1 week before. Though the child presented with laryngitis like symptoms, considering the foreign body ingestion history, diagnostic work-up was done to rule out foreign body in larynx. On X-ray, a radio-opaque foreign body was seen in the larynx above the glottis. He was taken to the operation theatre and under general anaesthesia, foreign body was seen and was piercing the posterior pharyngeal wall. It was carefully removed and pus was seen leaking from the removal site. After a course of antibiotics, the child was apparently normal then.

Conclusion: A Laryngeal foreign body shows a wide variety of presentations depending on its size and shape. Hence, the children with laryngitis like symptoms should be investigated for foreign body aspiration irrespective of the symptoms if a history of foreign body ingestion was given.

© This is an open access article distributed under the terms of the Creative Commons Attribution License (<https://creativecommons.org/licenses/by/4.0/>) which permits unrestricted use, distribution, and reproduction in any medium, provided the original author and source are credited.

1. Introduction

Foreign body aspiration is a major cause of accidental death in children.¹ Foreign body ingested can either enter the airway or oesophagus. If it enters the airway, it can either get lodged in larynx above the vocal cord or enter the trachea which may further lead to bronchi. Laryngeal foreign bodies are a rare occurrence in the paediatric age group in comparison to bronchial foreign bodies.² Most foreign bodies lodge in the bronchial tree and only a small percentage (around 4%) become struck in the larynx.³ While the lower respiratory tract foreign body symptoms raise an index of suspicion, laryngeal foreign bodies particularly those causing incomplete obstruction, may present with a different clinical picture resembling infection.⁴ The presentation of laryngeal foreign body depends upon the size, shape, site, nature of foreign body and the degree of obstruction leading to a great variability

in symptoms.^{2,4,5} Sharp objects may cause internal damage in the larynx with or without breathing difficulty depending on the size and shape of the object. Objects like pin may cause little stridor but can be extremely painful. This kind of laryngeal foreign bodies have been misdiagnosed as recurrent laryngitis or asthma for a long duration in few instances.^{6,7}

2. Case Report

A 10-year-old male child was referred to the ENT department with complaints of throat pain and dysphonia for the past 1 day. He gave the history of foreign body ingestion 7 days back. He was apparently normal then. For the past one day, he complained of throat pain. He didn't have any breathing difficulty but had odynophagia and hoarseness of voice. He didn't eat anything since the throat pain started. On examination, he had painful mouth opening, tenderness in the anterior part of neck and mild increase in body temperature. His X-ray (AP and lateral view) of neck was

* Corresponding author.

E-mail address: bhumikatrivedi2001@gmail.com (B. Trivedi).

taken. In X-ray, a radio-opaque sharp object seemed like a pin was seen piercing the posterior pharyngeal wall and is present above the vocal cord, just below the epiglottis.

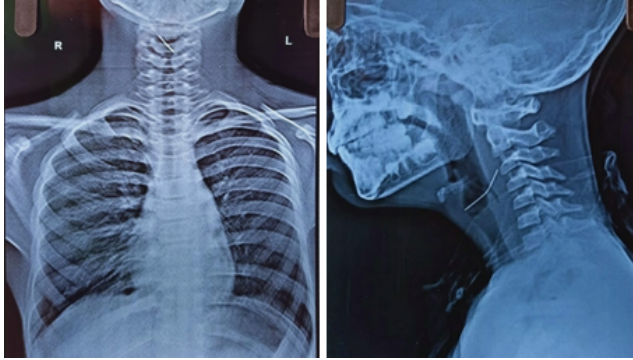


Fig. 1: X-Ray Lateral and AP view of neck respectively showing a radio-opaque sharp object piercing the posterior pharyngeal wall.

After confirming the presence of foreign body, the child was planned for foreign body removal under general anaesthesia. He was given intravenous antibiotics, painkiller, anti-reflux medications and kept nil per oral. He was taken inside the operation theatre and under general anaesthesia, his larynx is visualized using laryngoscope. A sharp turban pin was seen piercing the posterior pharyngeal wall just below the epiglottis. It was carefully removed using forceps without injuring the neighbouring structures. After removal, pus was seen leaking out from the removal site. Pus was suctioned out and the larynx was completely explored. Post operatively antibiotics and nebulization were given. The patient is completely normal now.

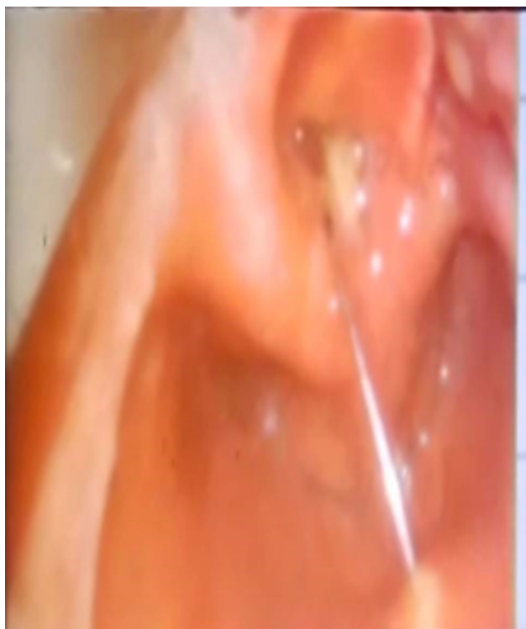


Fig. 2: A metallic pin in the larynx above the vocal cords)

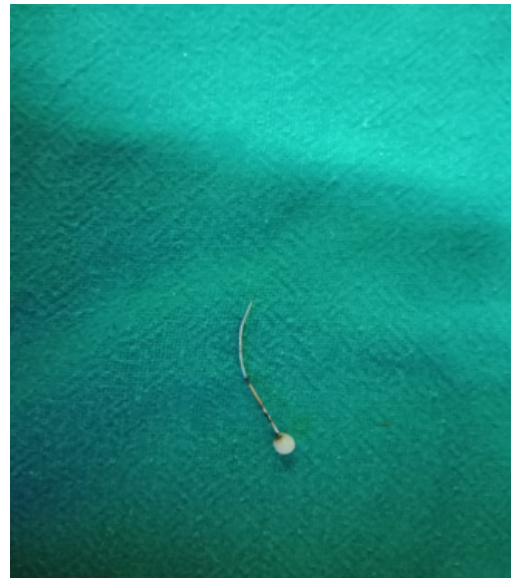

Fig. 3: Foreign body: A Turban pin after removal)

3. Discussion

Aspiration of foreign body into the respiratory tract is a common accident, which occasionally has a fatal outcome. It is said to be one of the commonest recognized causes of sudden death, especially in children.⁸ The majority of the foreign bodies are lodged in the bronchial tree; in five series of cases an incidence of 88-96% was reported.⁹⁻¹² The larynx is a much less common site and accounted for only 2-6.7% of cases.^{9,10,12,13} A foreign body in larynx can cause complete airway obstruction leading to sudden death if not promptly removed. On the other hand, a small foreign body, especially when thin, laminar or triangle shaped may present with a partial laryngeal obstruction, which may present with less severe symptoms. In our case, the patient didn't complaint of any symptoms for the initial 5 days, even though he had history of foreign body ingestion. This is mainly because of the shape of the foreign body. The metallic pin was too narrow to cause any airway obstruction which may delay the diagnosis. Likewise, although choking episode is obtained in the majority (73-85%) of patients with inhaled foreign bodies the diagnosis may be delayed.^{9,11,13} The length of time to diagnose ranged from less than 24 hours in 55% patients to 5.5 months in 5% of cases. However, most laryngotracheal foreign bodies were diagnosed in a week, probably because of greater severity of symptoms.¹⁴ In order to prevent the aspirated foreign body go unnoticed, diagnostic workup should be done in all cases with history of foreign body ingestion, even though the patient didn't show any symptoms. A strong index of suspicion, adequate history and careful examination of x-rays will aid diagnosis. A detailed pre-operative assessment is essential,

since the type of anaesthesia, operative technique and any secondary complications expected can be determined by the exact location and shape of the foreign body. During the whole procedure, the patient's blood oxygen saturation is monitored carefully. 3-dimensional CT scan is a more sensitive diagnostic modality for foreign body aspiration in comparison to conventional radiography and is increasingly becoming the image of choice, especially for radiolucent foreign bodies like plastic materials.^{15,16} X-ray may be enough in some cases if the object is metallic like in our case. In case of impacted foreign body, tracheostomy or jet ventilation may be considered. It is also equally important to counsel the patient to prevent further episodes in the future.

4. Conclusion

A laryngeal foreign body presenting with infection like symptoms rather than obstruction symptoms is a rare occurrence. It can even go mis-diagnosed as laryngitis. So, it is always advised to ask detailed history of foreign body ingestion and do relevant examination in all children with laryngitis like presentation irrespective of the presence or absence of airway obstruction symptoms.

5. Conflicts of Interest

All contributing authors declare no conflicts of interest.

6. Source of Funding

None.

References

1. Jesudason WV, Luff DA, Rothera MP. Delayed diagnosis of laryngeal foreign body. *J Laryngology Otol.* 2003;117(2):143-4. doi:10.1258/002221503762624639.
2. Bloom DC, Christenson TE, Manning SC, Eksteen EC, Perkins JA, Inglis AF, et al. Plastic laryngeal foreign bodies in children: A diagnostic challenge. *Int J Pediatr Otorhinolaryngol.* 2005;69(5):657-62. doi:10.1016/j.ijporl.2004.12.006.
3. Cinar U, Vural C, Turgut S. A laryngeal foreign body misdiagnosed as asthma bronchiale. *Eur J Emerg Med.* 2003;10(4):334-6. doi:10.1097/00063110-200312000-00019.

4. Robinson PJ. Laryngeal foreign bodies in children: First stop before the right main bronchus. *J Paediatr Child Health.* 2003;39(3):477-9.
5. Mathiasen RA, Cruz RM. Asymptomatic Near-Total Airway Obstruction by a Cylindrical Tracheal Foreign Body. *Laryngoscope.* 2005;115(2):274-7. doi:10.1097/01.mlg.0000154732.16034.83.
6. Atmaca S, Unal R, Sesen T, Kilicarslan H, Unal A. Laryngeal foreign body mistreated as recurrent laryngitis and croup for one year. *Turk J Pediatr.* 2009;51:65-6.
7. Chavoshzadeh Z, Golnabi A, Rezaei N, Mehdizadeh M. Laryngeal foreign aspiration misdiagnosed as asthma: Two case reports and a review of the literature. *B-ENT.* 2011;7:137-40.
8. Ross A, McCormack RJM. Foreign body inhalation. *J Royal Coll Surg Edinburgh.* 1980;25(7):104-9.
9. Rothmann BF, Boeckman CR. Foreign Bodies in the Larynx and Tracheobronchial Tree in Children. *Ann Otol, Rhinol Laryngology.* 1980;89(5):434-6. doi:10.1177/000348948008900512.
10. Cohen SR, Lewis GB, Herbert WI, Geller KA. Foreign bodies in the airway. Five year retrospective study with special reference to management. *Rhinol Laryngology.* 1980;89:437-42.
11. Wiseman NE. The diagnosis of foreign body aspiration in childhood. *J Pediatr Surg.* 1984;19(5):531-5. doi:10.1016/s0022-3468(84)80097-4.
12. Banerjee A, Subbarao K, Khanna SK, Narayan PS, Gupta BK, Sekar JC, et al. Laryngo-tracheo-bronchial foreign bodies in children. *J Laryngology Otol.* 1998;102:1029-32.
13. Blazer S. Foreign Body in the Airway. *Am J Dis Children.* 1980;134(1):68-71. doi:10.1001/archpedi.1980.02130130050015.
14. Esclamado RM. Laryngotracheal Foreign Bodies in Children. *Am J Dis Children.* 1987;141(3):259-62. doi:10.1001/archpedi.1987.04460030037019.
15. Fidkowski CW, Zheng H, Firth PG. The Anesthetic Considerations of Tracheobronchial Foreign Bodies in Children: A Literature Review of 12,979 Cases. *Anesthesia Analgesia.* 2010;111:1025-25. doi:10.1213/ane.0b013e3181ef3e9c.
16. Hong SJ, Goohw, Roh JL. Utility of spiral and cine CT scans in pediatric patients suspected of aspirating radiolucent foreign bodies. *Otolaryngol Head Neck Surg.* 2008;138:576-80.

Author biography

Vignesh A K, Junior Resident 3rd Year

Bhumika Trivedi, Junior Resident 3rd Year

Cite this article: Vignesh A K, Trivedi B. Infected laryngeal foreign body: A case report. *IP Indian J Anat Surg Head, Neck Brain* 2020;6(4):138-140.