

Prolene Suture- Optimizing results in DCR!

Tuli IP¹, Sengupta S², Pal S³, Baruah B⁴, Ilapakurty B⁵, Jain A⁶, Lepcha PS⁷

¹Assistant Professor, PGIMER & Dr. RML Hospital, New Delhi, ²Assistant Professor, ESIPGIMSR & Medical College, Kolkata, ³Consultant, Vasana Eye Care, Kolkata, ⁴Consultant, Department of ENT, Tata Memorial Hospital, Jamshedpur, ⁵Senior Resident, Department of Head & Neck Oncology, Dr. B Barooah Cancer Institute, Guwahati, ⁶Consultant, Department of ENT, Head & Neck Surgery, SGL Charitable Hospital, Jalandhar, ⁷Senior Medical Officer 1, District Hospital Mangan, Sikkim

Corresponding Author:

Tuli IP

Assistant Professor, PGIMER & Dr. RML Hospital, New Delhi

E-mail: ishatuli@gmail.com

Abstract

Background: *Dacryocystorhinostomy (DCR) done to treat chronic dacryocystitis and nasolacrimal duct stenosis may fail due to post-operative granulation tissue and synechia that form around the neo-ostium. Success rates vary in different studies and we are reporting our success rates of a modified DCR by using Prolene thread as a stent.*

Methods: *We performed a modified endoscopic DCR on twenty eyes; senior consultants operated ten eyes and the remainder ten eyes by residents under guidance. We used 6-0 Prolene suture as a stent, instead of silicon tubing, with the help of a 23G Viscoelastic cannula, from lower punctum to the neo-ostium, after creating a large bony opening to form an anastomosis for the lacrimal sac and nasal mucosa.*

Results: *The postoperative follow up period was 6 months. The success rate of endoscopic DCR using Prolene stent was 100% even in the hands of residents.*

Conclusions: *This modification enables an easy, safe, effective, reproducible, universally available and low-cost form of DCR easily implemented by surgeons doing this procedure, giving excellent results.*

Key Words: *Endoscopic Dacryocystostomy, Stent, Prolene*

Introduction

Chronic dacryocystitis is permanent nasolacrimal duct obstruction, with constant tearing, because of closed natural tear drainage route, found commonly at the junction between lacrimal sac and nasolacrimal duct.¹

Endoscopic DCR, first described in 1989, popularized due to rhino logical advances has a variable success rate from 70% to 95%.^{2,3} The most important prognostic factor is the obstruction level in lacrimal drainage.³ Failure mainly occurs because of neo-ostium closure by granulation tissue, scarring or synechia.^{4,5,6,7,8}

Our study estimates the effectiveness of a modified endoscopic DCR technique, even in the hands of novice surgeons.

Material and Methods

For the present study, we selected twenty cases of chronic dacryocystitis who underwent endoscopic DCR with prolene stenting at our institution from November 2011 to August 2013. Patients presenting with epiphora and discharge from eye due to a distal obstruction of nasolacrimal

duct were included in the criteria for endoscopic DCR. We then divided them into 2 groups randomly, by draw of lots done by the assisting nurse on the day of the surgery. The experienced consultants of the institute operated the controls and the postgraduate trainees (residents) operated the cases, under the guidance of the consultant. The surgical team was constant. We excluded patients of proximal duct obstruction, revision cases and patients who did not follow-up for 6 months or refused consent from our study. Institution Ethics Committee of SMIMS clearance was obtained [IEC/199/14-02].

An ophthalmologist evaluated all patients before surgery. Pre-operative evaluation consisted of a standard examination that included lacrimal irrigation and probing and nasal cavity examination. The need for additional nasal surgery (i.e., septoplasty, middle turbinate reduction) was determined pre-operatively.

Patient symptoms and endoscopic findings of the neo-ostium were evaluated postoperatively at 3 months and 6 months. Irrigation through the punctum was performed to evaluate the patency of

the neo-ostium post-operatively, and the neo-ostium was judged patent when the marsupialised sac was well maintained in shape and size, with free flow of saline on irrigation. Surgery was considered unsuccessful if the patient had one or more of the following postoperative outcomes: 1) no marked improvement of preoperative chronic epiphora; 2) inability to irrigate the lacrimal system; and 3) nasal endoscopy revealing obstruction of the neo-ostium with granulation tissue or synechia. Cases with granulations or synechia not occluding the neo-ostium were not considered failures.

Operative techniques

DCR was performed under local or general anesthesia, as determined by considering a number of patient factors. Nasal cavity was packed with a mixture of 1ml each of 1:10,000 epinephrine and 4% lidocaine for 10 minutes for topical anesthesia and vasoconstriction. Then, the axilla of the middle turbinate and the mucosa surrounding the lacrimal sac was infiltrated with 1:200,000 epinephrine and 2% lidocaine. The patient was kept in supine position with the head elevated 15° and turned towards the surgeon. A zero or thirty degree, 4-mm diameter endoscope was inserted and an inverted u-shaped incision 10×10 mm in size, was made at the lateral nasal wall anterior and slightly superior to the insertion of the middle turbinate (Fig. 1). The inferiorly based mucosal flap was elevated backwards off the maxillary bone, extending up to the uncinate process, reflected over the inferior turbinate, and protected with a saline soaked tagged cotton pack. The maxillary bone covering the lacrimal sac was gently punched using a DCR punch and drilled (Curved diamond burs, 15°, 5 mm and 2.9 mm with straight shot hand piece) until the sac was widely exposed, extending to the level of the fundus. Metallic lacrimal probe was passed medially through the inferior canaliculus, and gently pushed to tent the sac, facilitating incision through the sac while precisely localizing the position of the sac lumen. An incision was made with a sickle knife, avoiding injury to the sac lumen; hence, minimizing hemorrhage. Patency was checked by saline irrigation via inferior canaliculus and flow into nasal cavity through new stoma visualized (Fig. 2). The elevated nasal mucosal flap was trimmed posteriorly to form a large inferiorly based anterior flap that was adjusted in size and repositioned to cover the denuded bone in front of the surrounding the opened sac. In case of accidental tearing or loss of this mucosal flap, the

remnant mucosa was reflected back as much as possible. The lacrimal sac flaps were incised, everted, and adjusted to accurately oppose the nasal mucosa. A 6-0 polypropylene (Prolene; Ethicon, Inc.) suture was passed from the inferior canaliculus into the nasal cavity using a disposable Viscoelastic cannula, (23G x 7/8", 0.64 x 22mm, Angled at 45°) (Fig. 3,4,5) and tied outside the nose loosely to prevent laceration (Fig. 6). A small gel foam patch was packed lightly in the exposed sac to keep the flap anastomosis in position throughout the initial healing period. Nasal pack was put only if there was an associated nasal surgery (i.e. septoplasty).

Post-operatively, each patient was prescribed oral antibiotics and an analgesic for five days, antibiotic ophthalmic drops four hourly for ten days and nasal decongestant drops twice daily for three days. All patients were followed at weekly for four weeks then at sixth week, third and sixth month post operatively for nasal dressings. In each visit, irrigation of normal saline into the lacrimal system with assessment of the flow through the stoma with a 30° nasal endoscope was done to check the patency. Any crusting, granulations & secretions and were removed. On the bases of these findings, results were classified into patent and blocked nasolacrimal duct and compared with each group to evaluate the success rate. Saline douching of the nasal cavity was advised to prevent crust formation. The prolene thread was removed after six weeks. (Fig. 7)

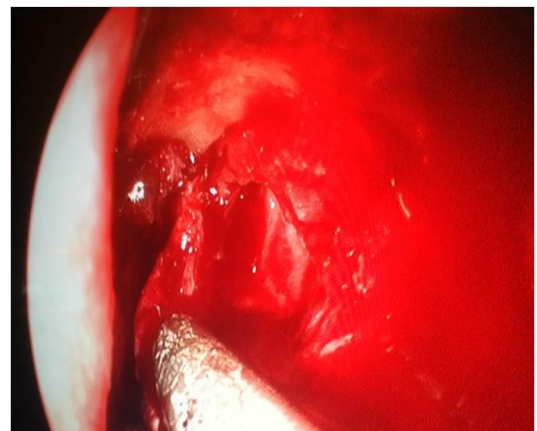

Fig. 1: Incision on the nasal mucosa

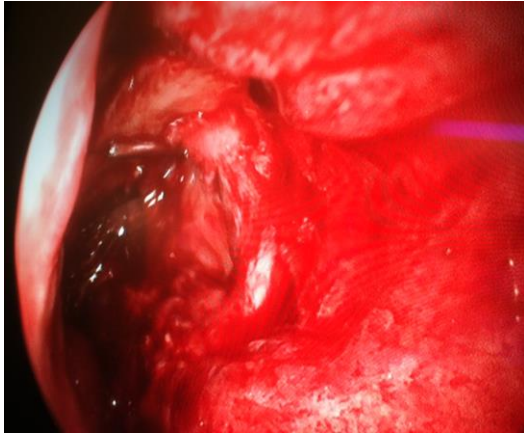


Fig. 2: Probe inserted through the lower lacrimal punctum, visualized endoscopically through the nose after incising the lacrimal sac

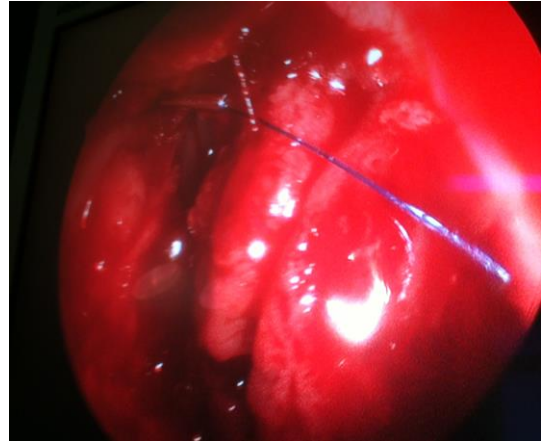


Fig. 5: Prolene suture brought out into the nasal cavity



Fig. 3: 6-0 Prolene suture in the Viscoelastic Cannula

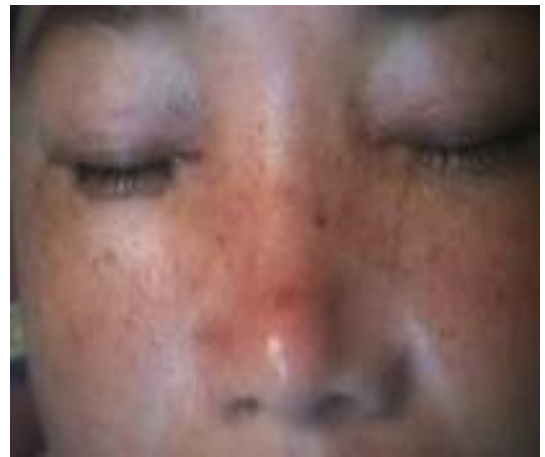

Fig. 6: Prolene suture tied outside

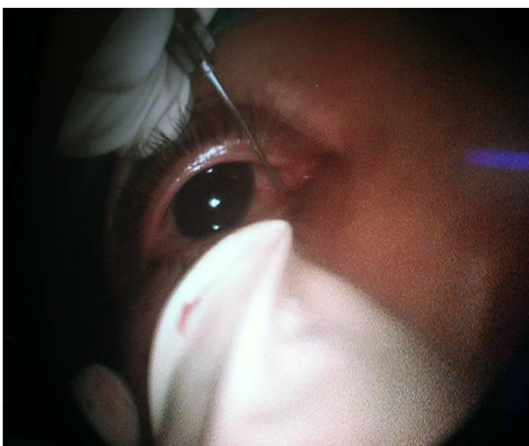

Fig. 4: Inserting Prolene suture through the cannula into the lower lacrimal punctum

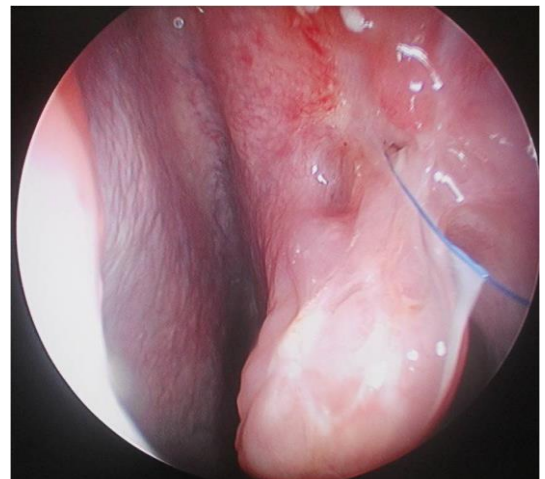


Fig. 7: Patency of neo-ostium on the 6th week follow-up

Results and Analysis

Following the study period, we grouped and analyzed all the data using excel.

Overall, there were 18 patients (20 eyes) in the study and epiphora was the presenting symptom in all. Two patients had bilateral disease that was tackled in the same sitting. 14 (77%) patients were females. The mean age in this group was 45.5 years.

Visual disturbance was noted in six eyes in the form of immature cataract. Associated sino-nasal symptoms were also seen, allergic features in four cases and deviated nasal septum obstructing access to the sac area in four cases. These patients were managed for these problems simultaneously.

Postoperatively, six eyes (33% of patients) had mild cellulitis of the orbital tissues with ocular congestion and purulent eye discharge, three each under the hands of the consultant and the resident respectively. Two (11% of patients) developed granulations at the operative site, both of which were operated by the consultant. Four (22 % of patients) developed synechiae and again the consultant and the resident had operated two each respectively. Any synechiae and granulations were cleared at detection and cellulitis was managed conservatively with topical and oral antibiotic therapy.

All patients had a total relief of epiphora, even at the 6-month follow-up.

Discussion

The endoscopic dacryocystorhinostomy is a safe surgical technique. The results in improvement of lacrimal obstruction symptoms (epiphora, local inflammation) range between 75% and 96%. Compared with other techniques such as when performed by external approach that presents similar results in terms of symptomatic improvement, Endoscopic DCR is associated with better anatomical accessibility, less surgical trauma, operative time and postoperative stay.¹

Several factors may affect the outcome of Primary Endoscopic DCR. Granulation tissue and synechia formation around the neo-ostium are known to be very important causes of failure.^{4,5,8} Gupta has reported that an improper selection of cases may also lead to failure of the surgery. Other factors accounting for failed DCR named in her study were low rhinostomy, inadequate sac opening, pre-existing canaliculitis, contracture at the rhinostomy site, LASER burn causing canalicular scarring and laxity of the lids and atonic sac.¹¹ Numerous researchers have tried to address this problem by different means.^{6,7,9,12}

Some authors recommend the application of Mitomycin C at the rhinostomy site to reduce post-

operative fibrosis and discourage stomal closure.^{13,14} However, conflicting reports suggest no added advantage of Mitomycin C in improving results of Endo-DCR.^{15,16}

Use of LASERs to create the neo-ostium is also known to reduce failures^{4,5,12} Creation of a large marsupialised sac at the time of rhinostomy with mucosal preservation is also reported to improve the success rate.^{7,17} Nevertheless, such flaps warrant complicated and difficult surgical procedures with sophisticated techniques and expert surgical hand for their generation.¹⁸

Silicone stent has also been used successfully to keep the neo-ostium patent,^{1,3,13} however, various researchers have reported no statistically significant benefit on using a silicone stent in a primary DCR.^{11,19} Some studies report a success rate as low as 41% with silicone stent.²⁰ Novel stenting techniques in the form of otological T-tube²¹ or prolene stent^{9,10} instead of silicone stent have shown promising results.

Önerci et al have reported that Endoscopic DCR is a relatively infrequent operation, with an obvious learning curve and experience is plays an important role in the success of the procedure.⁸ Less experienced surgeons performing the procedure infrequently and alone increase the risk of failure, stressing on the need to develop a formal training programme for Endo-DCR.^{1,8,11,}

With all the advantages Endoscopic DCR provides, it is essential to develop a low cost technique that increases the success rate of this surgery even in the hand of novices particularly in developing countries as India.

In the present study, success rate of 100% in endoscopic dacryocystorhinostomy using prolene suture as a stent was achieved in both the groups. While we passed a 6-0 prolene suture as a stent, a larger diameter of the suture 2-0 prolene also passes with ease through the inferior lacrimal punctum.⁹ Aslan et al used a Ritleng probe to pass the 2-0 prolene suture,⁹ but we used a more widely available disposable viscoelastic cannula for the same.

A follow-up of at least 6 month is recommended to detect failure as majority of the failures occur within the first four months of surgery,^{4,5,13,16} so we followed up the patients up to a period of six months. Until the last visit at 6 months, patients did not complain of any epiphora and the neo-ostium was patent on nasal endoscopy in both the groups of patients. Thus, we feel that use of a prolene suture is a low cost, effective stent that

can be practiced in cases of primary DCR, by relatively inexperienced surgeons even in remote areas where LASERs, silicone stent and other such adjuncts are not easily available.

Strengths of this study

Technique of Endoscopic DCR used in this study is easily reproducible even when done by an external route. Prolene suture and Viscoelastic cannula are freely available low cost non-toxic ancillaries that can be easily procured even in developing countries and remote areas, where silicone intubation set are not conveniently available. Even with marsupialization, a failure of 6% - 16% is reported.^{7,20} However, our technique results in good success rates (100%) even in the hands of novice surgeons, challenging the belief of a learning curve of this surgery.

Limitation

The limitations of the study included a small sample size, using draw of lots as a technique of randomization and primary stenting in cases being operated for chronic dacryocystitis as opposed to stenting being reserved for failure cases. Sikkim being the least populated state of India, with only 6.11 lakh population (2011 census of India), it is very difficult to get a larger sample size in the given time period.²² The technique employs stenting incases undergoing surgery for the first time as opposed to the conventional practice of reserving stenting for revision cases only. The stenting is visible externally which may not be preferred by patients. However, in our series, subjects were not worried about the suture and only needed minimal counseling.

Conclusion

Inertness of prolene as a stent for preventing scarring or closure of the neo-ostium or the new tract in endoscopic dacryocystorhinostomy aids in preventing re-stenosis and maintaining post-operative patency of passages. Adjunctive use of a stent increased the success rate of endoscopic endonasal DCR and prolene suture has proved itself as a low cost effective stent. Its intraoperative use seems to be easy and safe, even in the hands of relatively inexperienced surgeons, giving good results. Further, no specific training or expertise is required to perform this technique. The study of this limited series shows no disadvantages yet and this

warrants further studies and evaluation using larger numbers of cases in future.

References

- Martínez Ruiz-Coello A, Arellano Rodríguez B, Martín González C, López-Cortijo Gómez De Salazar C, Laguna Ortega D, García-Berrolcal JR, Pinilla Urraca M, Ramírez-Camacho R. Results of 12 years of endoscopic dacryocystorhinostomy. *Acta Otorrinolaringol Esp.* 2011 Jan-Feb;62(1):20-4.
- McDonogh M, Meiring JH. Endoscopic transnasal dacryocystorhinostomy. *J Laryngol Otol.* 1989 Jun;103(6):585-7.
- Choi JC, Jin HR, Moon YE, Kim MS, Oh JK, Kim HA, Choi MY, Shim WS. The surgical outcome of endoscopic dacryocystorhinostomy according to the obstruction levels of lacrimal drainage system. *Clin Exp Otorhinolaryngol.* 2009 Sep;2(3):141-4.
- Boush GA, Lemke BN, Dortzbach RK. Results of endonasal laser-assisted dacryocystorhinostomy. *Ophthalmology.* 1994 May;101(5):955-9.
- Kong YT, Kim TI, Kong BW. A report of 131 cases of endoscopic laser lacrimal surgery. *Ophthalmology.* 1994 Nov;101(11):1793-800.
- Welham RA, Wulc AE. Management of unsuccessful lacrimal surgery. *Br J Ophthalmol.* 1987 Feb;71(2):152-7.
- Jin HR, Yeon JY, Choi MY. Endoscopic dacryocystorhinostomy: creation of a large marsupialized lacrimal sac. *J Korean Med Sci.* 2006 Aug;21(4):719-23.
- Onerci M, Orhan M, Ogretmenoğlu O, Irkeç M. Long-term results and reasons for failure of intranasal endoscopic dacryocystorhinostomy. *Acta Otolaryngol.* 2000 Mar;120(2):319-22.
- Aslan S, Oksuz H, Okuyucu S, Akoglu E, Dagli S. Prolene: a novel, cheap, and effective material in dacryocystorhinostomy. *Acta Otolaryngol.* 2009 Jul;129(7):755-9.
- Mushannavar SA. A comparative study of endoscopic Endonasal dacryocystorhinostomy with and without prolene stenting. [Dissertation for Masters in Otorhinolaryngology thesis]. Department of ENT, Head and Neck surgery, KVG Medical College and Hospital, Sullia: Rajiv Gandhi University of Health Sciences, Karnataka, Bangalore; 2012. [Cited 2013 Nov 16]. Available from: <http://hdl.handle.net/123456789/6159>
- Gupta N. Improving Results in Endoscopic DCR. *Indian J Otolaryngol Head Neck Surg.* 2011 Jan;63(1):40-4.
- Singh AP, Narula V, Meher R. A new approach to endoscopic DCR. *Braz J Otorhinolaryngol.* 2012 Oct;78(5):7-11.
- Zilelioğlu G, Uğurbaş SH, Anadolu Y, Akiner M, Aktürk T. Adjunctive use of mitomycin C on endoscopic lacrimal surgery. *Br J Ophthalmol.* 1998 Jan;82(1):63-6.
- Cheng SM, Feng YF, Xu L, Li Y, Huang JH. Efficacy of mitomycin C in endoscopic dacryocystorhinostomy: a systematic review and meta-analysis. *PLoS One.* 2013 May 13;8(5):e62737.
- Tirakunwichcha S, Aejumjaturapat S, Sinprajakphon S. Efficacy of mitomycin C in endonasal endoscopic dacryocystorhinostomy. *Laryngoscope.* 2011 Feb;121(2):433-6.
- Wadhwa R, Gulati SP, Khurana AK, Sharma H, Kalra V, Ghai A. A comparative study of endoscopic endonasal dacryocystorhinostomy with and without intraoperative mitomycin-C application. *Clin Rhinol An Int J* 2013 Jan-Apr;6(1):5-9.

17. Kodama S, Hirano T, Suzuki M. Endoscopic dacryocystorhinostomy with mucosal flap. *Nihon Jibiinkoka GakkaiKaiho*. 2011 Oct;114(10):820-3.
18. Ota Y, Ikemiyagi Y, Takizawa K, Yamada C, Rikitake R, Suzuki M. Efficacy of covering mucosal defects with polyglycolic acid sheets after ear or nose surgery. *Laryngoscope*. 2015 Mar;125(3):567-70.
19. Feng YF, Cai JQ, Zhang JY, Han XH. A meta-analysis of primary dacryocystorhinostomy with and without silicone intubation. *Can J Ophthalmol*. 2011 Dec;46(6):521-7.
20. Evelyn-Tai LM, Jessica MPT, Wan-Hazabbah WH, Ramiza R, Baharudin A, Adil H. Effect of stenting and mucosal flap preservation on outcome of endoscopic dacryocystorhinostomy. *Guoji Yanke Zazhi (Int Eye Sci)* 2014;14(3):381-5.
21. Oghan F, Ozcura F. A novel stenting technique in endoscopic dacryocystorhinostomy. *Eur Arch Otorhinolaryngol*. 2008 Aug;265(8):911-5.
22. Sikkim Population Census data 2011. [Internet] 2011. [Cited 2014 June 26]. Available from <http://www.census2011.co.in/census/state/sikkim.html>.