

Oesophageal Foreign body in a neonate: Report of an uncommon case

Vadisha Srinivas Bhat¹, Avanish Bhandary², Satheesh Kumar Bhandary³, Shama Shetty⁴

^{1,3}Professor, ⁴Resident, Department of ENT, ²Professor, Department of Anesthesiology, KS Hegde Medical Academy, Mangalore

Corresponding Author:

Vadisha Srinivas Bhat

Professor, Department of ENT, KS Hegde Medical Academy, Mangalore

E-mail: bvadish@yahoo.co.in

Abstract

Ingestion of foreign body is not uncommon in paediatric population; most of them being act of curiosity while some are ingested accidentally while playing. However foreign body ingestion is unusual in a neonate. This is a report of a 29 day old neonate who ingested a finger ring presented by her uncle. The foreign body impaction was confirmed radiologically, and it was removed by transoral oesophagoscopy using paediatric bronchoscope under general anaesthesia.

Key words: Foreign body; Neonate; Oesophagoscopy; Paediatric bronchoscope

Introduction

Oesophageal foreign body is a well-known entity in ENT practice. This can be seen in any age group, but the type of foreign body varies with the age. Accidental ingestion of foreign body is common in paediatric population, especially in the age of 2 years to 4 years, when the child had achieved the grasping ability and starts exploring the environment.¹ Most of the cases of foreign body oesophagus are accidental ingestion, but sometimes this may be an act of homicide also.² Oesophageal foreign bodies in a neonate are extremely rare, only few cases being reported in the literature. Here we report a case of a neonate with accidental ingestion of an ornament presented by her uncle. The foreign body was retrieved by trans-oral oesophagoscopy after radiological confirmation.

Case Report

A 29 day old baby girl was brought to the ENT department of our hospital with history of ingestion of a finger ring (ornament). The ring was presented by her uncle on a religious ceremony, and while sucking the finger, the baby swallowed the ring, which was fitting loosely. Anxious parents, staying in a remote village, rushed to our hospital. On the way to hospital, baby was fed breast milk. There is no history of vomiting, regurgitation or breathing difficulty. On arrival to

hospital, baby was examined for evidence of respiratory distress, which was conspicuously absent, and the baby was apparently comfortable. Plain radiograph of the neck with the chest was ordered, which showed the radio opaque foreign body at the level of C6-C7. (Fig. 1 and 2)

The baby was shifted to the operation theatre. Probes for monitoring the vitals were connected, including oxygen saturation and Electrocardiograms. Intravenous access secured with 22 G canula. Pre-oxygenation was done with 100% oxygen. General anaesthesia was induced with sevoflurane, without muscle relaxant. Oesophagoscopy was done using 3.5mm paediatric rigid bronchoscope. The foreign body, ring was impacted just below the cricopharynx circumferentially. This was grasped with an optical forceps, rotated and retrieved trans-orally. (Fig. 3 & 4) Postoperative period was uneventful, and baby was discharge from the hospital on the next day.

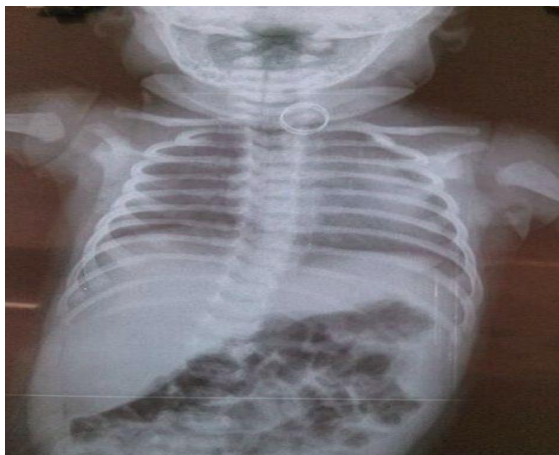

Fig. 1: X-ray Soft tissue neck Anteroposterior view

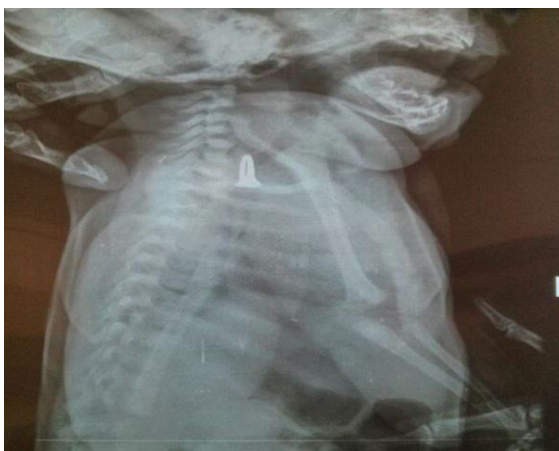

Fig. 2: X-ray Soft tissue neck lateral view

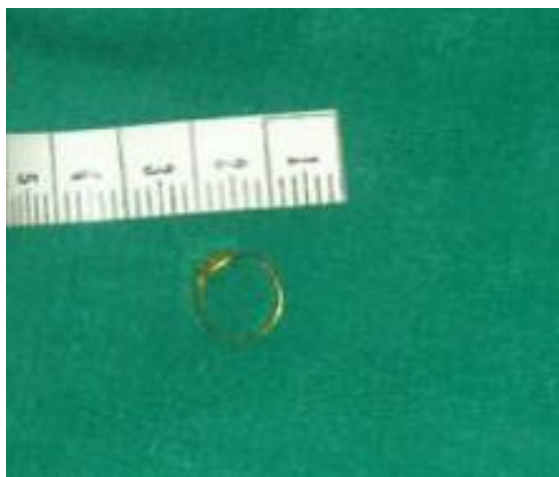


Fig. 3

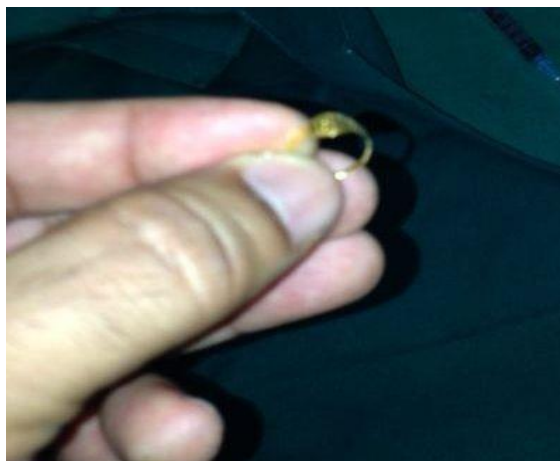

Fig. 3, 4: Foreign body(finger ring)

Discussion

The Oesophagus is a common site for entrapment of ingested foreign bodies. Though this is seen in all age groups, it is more common in paediatric age group. Manning et al, in their study of 100 cases of aerogidestive tract foreign bodies, observed ninety eight percent of cases to be under 10 years of age while 75% were under 4 years of age.¹ The type of foreign body oesophagus varies with the age. The most common foreign bodies ingested are coins, crayons, and button batteries in paediatricage.³ Unchewed food, ill-fitting or broken dentures are common in adult population.⁴ Oesophageal foreign bodies are rarely encountered in neonates. The cause of foreign body in a neonate may be accidental, but homicidal attempt is also reported.² Mirza et al reported a case of a 2 day old neonate who accidentally swallowed a broken piece of suction catheter.⁵ Ramalingam reported a case of disposable rubber nipple in the oesophagus of a neonate.⁶ In our case, it was accidental ingestion, as the finger ring which was presented, was loosely fitting, and it was swallowed when the baby sucked the finger.

Commonest site for lodgement of an ingested foreign body is cricopharynx.⁴ In our case too, the foreign body was impacted just below the cricopharynx. The symptoms depend upon the type and size of foreign body. The common presentations are with vomiting, dysphagia, odynophagia and choking. Respiratory symptoms, when present are mostly due to compression of the airway by a large foreign body.¹ In our case, even though there was definite history of ingestion of foreign body which was witnessed by the parents, the baby could feed milk, and there was no

vomiting. This could be because the lumen of the ring, allowed the milk to pass through.

Cricopharyngeal and oesophageal foreign bodies are potentially hazardous and, sometimes create fatal complications such as oesophageal perforation, subcutaneous emphysema, retro-oesophageal abscess, pneumothorax and pneumomediastinum, oesophago-aortic fistula, mediastinitis and lung abscess.⁴ Unattended oesophageal foreign bodies can damage the oesophagus leading to perforations and strictures. Apart from eroding into the trachea, the object can erode into the aorta, leading to exsanguinations and death. Foreign bodies should be immediately removed on diagnosis, because they may cause direct tissue damage and oesophageal perforation by pressure and by chemical and electrical burns.²

Diagnosis of oesophageal foreign body is easier when attendants give history of ingestion. X-ray neck, Anteroposterior and lateral view, is useful for confirmation. It is wise to include Nasopharynx also in the view, as sometimes the foreign body may be pushed into the nasopharynx, when the attendants try to remove the foreign body from the mouth.⁷ If the incident is not witnessed and the ingested object is radiolucent, the diagnosis of foreign body ingestion can be very difficult. Barium swallow examination, computed tomography scans of the neck or magnetic resonance imaging may be required for diagnosis.² Negative radiological findings do not rule out the possibility of a foreign body in the cricopharynx and oesophagus. Persistence of symptoms even in the absence of positive clinical or radiological signs warrants an endoscopic examination.⁴ After removal of foreign body, the scope should be re inserted to visualize the mucosa, to look for any abnormality. This holds good especially in an adult with impacted foreign body in the oesophagus, when the aetiology is actually a malignant stricture. Also re insertion of endoscope detects the presence of multiple foreign bodies, which is likely to be missed. Medatwal et al reported an interesting case of multiple foreign bodies; coin, safety pin, screw, cotton piece, polythene piece, and four glass pieces in a 12 day old neonate.⁸ In our case, the incident took place right in front of many people in a ceremony, we did not insert the endoscope again after removing the foreign body.

Conclusion

Oesophageal foreign body in a neonate is a rare entity. History of ingestion, even in the absence of other symptoms should guide the treating physician for radiological investigation. Trans-oral oesophagoscopy using a small size bronchoscope with optical forceps, in the non-availability of a small size oesophagoscope, is an ideal management strategy for Oesophageal foreign body.

Conflict of interest: None

Funding/ Financial assistance: Nil

References

1. Manning PB, Wesley JR, Polley TJ, Coran AG. Oesophageal and tracheobronchial foreign bodies in infants and children. *Pediatr Surg Int* (1987)2:346-351.
2. Singh R, Pandit C, Gupta D, Vajifdar H. Foreign body oesophagus in a neonate: Unusual age and unusual presentation. *J Anaesthesiol Clin Pharmacol*. 2012 Apr-Jun;28(2):258–260.
3. Stack LB, Munter DW. Foreign bodies in the gastrointestinal tract. *Emerg Med Clin North Am*. 1996;14493- 521.
4. Nayak SR, Kirtane MV, Shah AK, Karnik PP. Foreign bodies in the cricopharyngeal region and oesophagus (a review of 226 cases). *J Postgrad Med* 1984;30:214.
5. Mirza B, Saleem M, Sheikh A. Broken piece of silicone suction catheter in upper alimentary tract of a neonate. *APSP J Case Rep* 2010;1:8.
6. Ramalingam Arumugam. Foreign Body in the Esophagus as a Result of Reusing a Disposable Nipple. *Arch Pediatr Adolesc Med*. 1999;153(3):312.
7. Satheesh Kumar Bhandary, Biniyam K, Vadisha Srinivas Bhat, Balakrishna P S. Common foreign body: Unusual site. *Otolaryngology–Head and Neck Surgery* 2011. XX(X)1–2.
8. Medatwal A, Gupta PP, Gulati RK. Multiple Foreign Bodies in a Neonate. *Indian Pediatrics* 2008;45:928-30.