

Content available at: <https://www.ipinnovative.com/open-access-journals>

IP Indian Journal of Anatomy and Surgery of Head, Neck and Brain

Journal homepage: <https://www.ijashnb.org/>

Case Report

Isolated extramedullary intradural thoracic epidermoid cyst: A rare case report

Zahwa Rizwan¹, Shagufta Tahir Mufti², Anuj Kumar Tripathi^{3,*}, Saurabh Patahak³,
Om Prakash Gupta³, Punit Kumar³

¹Dept. of Anaesthesia, Career Institute of Medical Sciences and Hospital (CIMS&H), Lucknow, Uttar Pradesh, India

²Dept. of Pathology, Career Institute of Medical Science and Hospital, Lucknow, Uttar Pradesh, India

³Dept. of Surgery, Career Institute of Medical Sciences and Hospital (CIMS&H), Lucknow, Uttar Pradesh, India



ARTICLE INFO

Article history:

Received 16-08-2021

Accepted 29-09-2021

Available online 22-10-2021

Keywords:

Epidermoid

Cyst

Spinal dysraphism

Extramedullary

Thoracic

ABSTRACT

Spinal epidermoid cyst is a rare entity. It may be congenital with associated spinal dysraphism such as spina bifida, dermal sinus tract and other neural tube defects or acquired due to repeated lumbar puncture and trauma. Congenital spinal epidermoid cysts without spinal dysraphism are rare. Here we are reporting a rare and interesting case of thoracic extramedullary intradural epidermoid cyst with no associated features of spinal dysraphism or history of iatrogenic trauma in a young male patient.

This is an Open Access (OA) journal, and articles are distributed under the terms of the [Creative Commons Attribution-NonCommercial-ShareAlike 4.0 License](https://creativecommons.org/licenses/by-nc-sa/4.0/), which allows others to remix, tweak, and build upon the work non-commercially, as long as appropriate credit is given and the new creations are licensed under the identical terms.

For reprints contact: reprint@ipinnovative.com

1. Introduction

Spinal epidermoid cysts are rare benign tumors comprising 1% of the all spinal tumors.¹ They comprise between 0.5% and 1% of all spinal tumors but account for up to 10% of intraspinal tumors in children.² First case of spinal epidermoid cyst was reported by Chiari in 1883.³ Penisson-Besnier et al. firstly reported an intramedullary EC diagnosed by MRI (3). Octavian M S et al reported a total of 139 cases of spinal epidermoid cysts dated from 1962 to 2019 with their case included.⁴ They reported a bimodal age distribution with females affected more than males. Beechar V et al reported a case of spinal epidermoid cyst in a 71 year old hypertensive female extending from T10-S1.⁵ This brings the total number of spinal epidermoid cysts to 141, including our case.

A literature review by Barbagallo GMV et al revealed that only eight cases of isolated spinal intraduralextramedullary epidermoid cysts had been

reported, six cases of which were in the thoracic region.⁶ Akgun B et al. reported a case of intraduralextramedullary epidermoid cyst in a 3-year-old male at L1-L2 level presenting with increasingly leg weakness.⁷ Ganapathy S et al. reported another case of spinal intraduralextramedullary epidermoid cyst in a 1-year old female child at the level of D-10, presenting to the outpatient clinic with a brownish discoloured skin patch on the back with a slight swelling observed since birth.⁸ This brings the total number of reported spinal intraduralextramedullary epidermoid cysts to 11, including ours out of which only 8 are reported in thoracic location.

Thoracic region is the commonest site of spinal epidermoid cysts, followed by the lumbar region and least commonly, the sacral and cervical regions.⁹ The presentation could be asymptomatic with incidental findings or could present with motor, bowel and bladder, sensory or pain disturbances based upon the location of the cyst. The most frequent symptom reported was pain, followed by motor deficit, sensitive deficits, and sphincter deficiencies.⁴

* Corresponding author.

E-mail address: dranujkumartripathi@gmail.com (A. K. Tripathi).

Histologically these cysts are lined by stratified squamous epithelium and due to continuous desquamation and keratine breakdown, characteristic contents of the cyst are formed. They cysts are classified as congenital when associated spinal dysraphism,¹⁰ or acquired due to repeated lumbar puncture and trauma. Congenital spinal epidermoid cysts unassociated with spinal dysraphism are very rare.^{1,8,9} Here we are presenting a rare and interesting case of isolated spinal epidermoid cyst that presented as intradural and extramedullary in thoracic location D1 with review of the relevant literature.

2. Case Summary

A 22 year male presented in casualty with complaints of pain in both lower limb and difficulty in walking since 2 months with no co-morbidities. On neurological examination, spastic weakness was present in both lower limb with no involvement of the bowel and bladder. No features suggestive of spinal dysraphism were observed. There was no evidence of spinal dysraphism, the congenital nature of the lesion could not be established. Also, there was no history of trauma and lumbar puncture. As such, the case was considered as an isolated case of spinal intradural epidermoid cyst. Contrast enhanced Magnetic resonance Imaging (MRI) of spine revealed an intradural extra medullary well defined cystic lesion at D1 level, partially compressing the spinal cord. The lesion was isointense on T1 weighted image and non-homogenous to hyperintense on T2 weighted image with no significant contrast enhancement (Figure 1). There was no radiological evidence of osseous changes such as expanded spinal canal, laminar thinning and vertebral body scalloping. On surgical intervention intradural extramedullary epidermoid cyst was found and total excision was achieved (Figure 2). Decompression of the cyst revealed cheesy material corresponding to keratin (Figure 3).

Histological examination of the specimen with extensive sampling revealed a fibrocollagenous cyst wall lined with keratinizing stratified squamous epithelium with preserved granular layer. No adnexal structures such as eccrine glands, sebaceous glands or hair follicles were seen in the wall. Cyst contents were composed of abundant keratin flakes. Post operative period was uneventful with a progressive recovery and patient was discharged on post operative day 14 and is asymptomatic on follow up.

3. Discussion

Spinal epidermoid cysts are rare benign tumor and comprise 1% of all spinal tumors.^{1,2} On review of literature only few case reports are stratified for spinal epidermoid cyst without other spinal dysraphism, trauma and lumbar puncture.¹⁻³ Review of literature in the present study revealed, that the age ranged between 1 to 71 years.

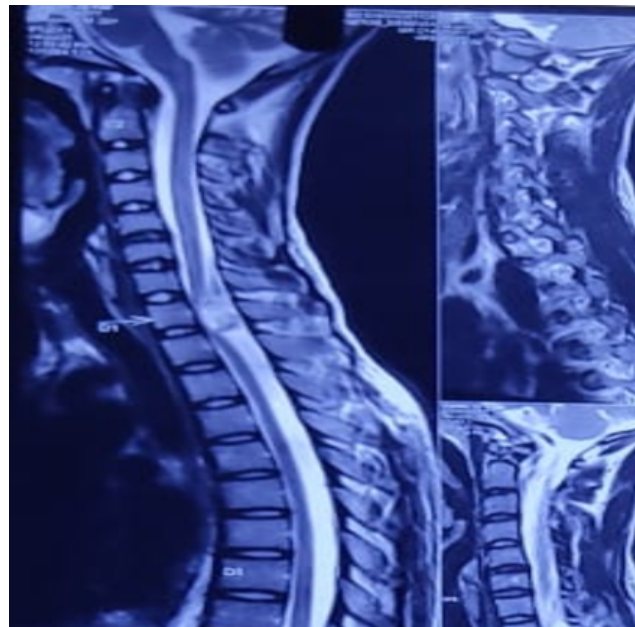


Fig. 1: Sagittal T2 weighted Magnetic resonance Imaging. Intradural Extramedullary nonhomogenous to hyperintense space occupying lesion at D1 Level partially compressing the spinal cord.

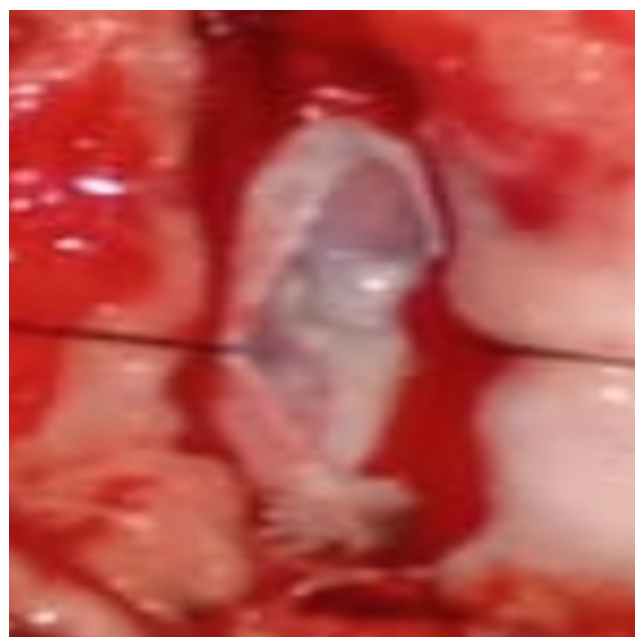


Fig. 2: Intraoperative pearl like intradural tumour

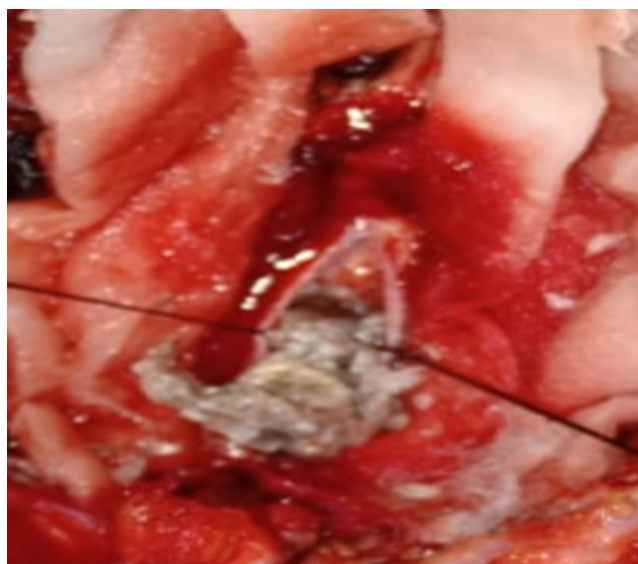


Fig. 3: Cheese like material oozing out during decompression of cyst.

In their review Octavian M S et al.⁴ reported that congenital cysts were 62.9% while acquired cysts are seen in 38.1% of patients. Congenital epidermoid cysts are usually associated with spina bifida, dermal sinus tract and other neural tube defects such as myelomeningocele, spina bifida occulta, spinal cord lipoma, scoliosis cutaneous/dermal defects.^{9,10} The possible explanation for congenital epidermoid cysts are the abnormal inclusion of ectoderm tissue in the neural tube during its closure in the intrauterine life. The most common localization was in the lumbar area and one third of the tumors were intramedullary.⁴ Acquired epidermoid cysts have been mostly reported in the region of the cauda equina (below the L1 level),¹⁰ because lumbar punctures are usually performed around the level of the iliac crests.

Histopathologically epidermoid cyst is lined by stratified squamous epithelium and cyst contents are formed due to progressive desquamation and keratin breakdown. The feature that differentiates it from dermoid cysts is the absence of skin appendages on histological examination (sebaceous glands, hair follicles, sweat glands)

Spinal ECs are difficult to diagnose on clinical symptoms alone. Plain X-rays usually show normal or nonspecific findings. Contrast MRI modality is the investigation of choice in these cases. These tumors are well defined, isointense on T1 weighted image, hyper intense on T2 weighted images with no or minimal contrast enhancement and the cyst content has signal similar to CSF.^{11,12} Generally, there is no perilesional edema. Presence of the typical signal intensity elicited on MRI helped to guide the diagnosis.

Intraoperatively, as white masses that are encapsulated and are commonly referred to as “pearly tumors.”⁵

Complete resection of the encapsulated tumor is difficult for all cases, because the cyst wall is very thin and often adhered to the arachnoid membrane, spinal cord, or nerve roots. Adherence to surrounding tissues is remnant, it may lead to recurrence of the cyst. Thereby, subtotal resection is also commonly performed.^{10,13,14} However total excision of epidermoid cyst is the main goal of surgery.¹⁵ There is high chance of neuronal damage during removal of cyst wall because sometimes cyst wall densely adheres with spinal cord and arachnoid membrane. Moreover, avoidance of cyst content spillage into subarachnoid space is critical to prevent the development of chemical meningitis and arachnoidal adhesions that may develop postoperatively.¹⁶ Octavian M S et al.⁴ in their literature review reported a good surgical outcome in most of the treated cases. In our case, we achieved total excision of epidermoid cyst owing to the non-adherent cyst walls, with almost no damage to the surrounding neuronal tissues and structures.

4. Conclusion

Thoracic intradural/extramedullary epidermoid cysts are rare benign, slow growing tumors which should be considered in the clinical differential diagnosis in this location. A possibility of the occurrence of sporadic cases despite the absence of a history of spinal dysraphism and puncture, such as in our case, should be considered. Total excision without neuronal damage is the main goal of surgery. Hence, safe maximum excision should be primarily aimed for and is considered the ultimate curative treatment, along with a long-term follow up to rule out any possible risk of recurrence.

5. Conflict of Interest

The authors declare that there are no conflicts of interest in this paper.

6. Source of Funding

None.

References

1. Liu H, Zhang JN, Zhu T. Microsurgical treatment of spinal epidermoid and dermoid cysts in the lumbosacral region. *J Clin Neurosci.* 2012;19(5):712–7.
2. Knipe H, Wein S. Spinal epidermoid cyst rID: 19659. *Radiopedia.* 2020; Available from: <https://radiopaedia.org/articles/spinal-epidermoid-cyst>.
3. Penisson-Besnier I, Guy G, Gandon Y, et al. Intramedullary epidermoid cyst evaluated by computed tomographic scan and magnetic resonance imaging: case report. *Neurosurgery.* 1989;25(6):955–9. doi:10.1097/00006123-198912000-00017.
4. Octavian-Mihai S, Alin-Vasile C, Mitrică M, Sîrbu CA. Spinal Intramedullary Epidermoid Cyst: Case Report and Updated Literature Review. *World Neurosurg.* 2020;139:39–50. doi:10.1016/j.wneu.2020.03.207.
5. Beechar VB, Zinn PO, Zinn Heck KA, Fuller GN, Akash IH, et al. Spinal Epidermoid Tumors: Case Report and Review of the Literature.

- Neurospine*. 2018;15(2):117–22.
6. Barbagallo GMV, Maione M, Raudino G, Certo F. Thoracic Intradural-Extramedullary Epidermoid Tumor: The Relevance for Resection of Classic Subarachnoid Space Microsurgical Anatomy in Modern Spinal Surgery. Technical Note and Review of the Literature. *World Neurosurg*. 2017;108:54–61.
 7. Akgun B, Ergun AC, Ozercan IH, Kok S. IntraduralExtramedullary Epidermoid Cyst at the ConusMedullaris Level with Thoracic Syringomyelia: A Case Report. *Acta Medica*. 2019;62(1):39–42.
 8. Ganapathy S, Priyamvatha K, Verma A, Baliga V. Dorsal IntraduralExtramedullary Epidermoid in a One Year Old Child - A Case Report and Review of Literature. *J Neurol Neurosurg*. 2019;9(5):555773. doi:10.19080/OAJNN.2019.09.555773.
 9. Manara R, Severino M, Mandari R, Mattisi G, and SDP. Chronic cystic lesion of the sacrum: characterisation with diffusionweighted MR imaging. *Radiol Med*. 2008;113(5):739–46.
 10. Funao H, Isogai N, Daimon K. A rare case of intradural and extramedullary epidermoid cyst after repetitive epidural anesthesia: case report and review of the literature. *World J Surg Onc*. 2017;15:131. doi:10.1186/s12957-017-1186-4.
 11. Munshi A, Talapatra K, Ramadwar M, Jalali R. Spinal epidermoid cyst with sudden onset of paraplegia. *J Cancer Res Ther*. 2009;5(4):290–2.
 12. Yen CP, Kung SS, Kwan AL, Howng SL, Wang CJ. Epidermoid cysts associated with thoracic meningocele. *ActaNeurochir (Wien)*. 2008;150(3):305–8.
 13. Scarrow AM, Levy EI, Gerszten PC, Kulich SM, Chu CT, Welch WC, et al. Epidermoid cyst of the thoracic spine: case history. *Clin Neurol Neurosurg*. 2001;103:220–2.
 14. Gonzalvo A, Hall N, McMahan JH, Fabinyi GC. Intramedullary spinal epidermoid cyst of the upper thoracic region. *J ClinNeurosci*. 2009;16(1):142–4. doi:10.1016/j.jocn.2008.04.017.
 15. Yin H, Zhang D, Wu Z, Zhou W, Xiao J. Surgery and outcomes of six patients with intradural epidermoid cysts in the lumbar spine. *World J Surg Oncol*. 2014;12:50. doi:10.1186/1477-7819-12-50.
 16. Roux A, Mercier C, Larbrisseau A. Intramedullary epidermoid cysts of the spinal cord. Case report. *J Neurosurg*. 1992;76(3):528–33. doi:10.3171/jns.1992.76.3.0528.

Author biography

Zahwa Rizwan, Resident

Shagufta Tahir Mufti, Assistant Professor

Anuj Kumar Tripathi, Associate Professor

Saurabh Patahak, Professor

Om Prakash Gupta, Professor

Punit Kumar, Resident

Cite this article: Rizwan Z, Mufti ST, Tripathi AK, Patahak S, Gupta OP, Kumar P. Isolated extramedullary intradural thoracic epidermoid cyst: A rare case report. *IP Indian J Anat Surg Head, Neck Brain* 2021;7(3):81-84.