

Content available at: <https://www.ipinnovative.com/open-access-journals>

IP Indian Journal of Anatomy and Surgery of Head, Neck and Brain

Journal homepage: <https://www.ijashnb.org/>

Original Research Article

A retrospective study to analyze treatment of post traumatic cerebro spinal fluid rhinorrhea and role of trans cranial pedicled pericranial repair in present day context

Shashivadhanan^{1,*}, Abhishek Mishra²

¹Dept. of Surgery, Military Hospital, Bathinda, Punjab, India

²Dept. of Radiologist, Military Hospital, Bathinda, Punjab, India



ARTICLE INFO

Article history:

Received 21-11-2021

Accepted 19-12-2021

Available online 16-01-2022

Keywords:

CSF Rhinorrhea

Anterior Cranial Fossa Base Repair

Trans cranial Pedicled pericranial flap Repair

ABSTRACT

Introduction: Skull base fractures are a major cause of morbidity and mortality in head injury. Anterior cranial Fossa (ACF) skull base fracture, leading to Cerebro Spinal Fluid (CSF) Rhinorrhea is one of the most commonly encountered presentation in ACF base fractures. The key to successful management of such cases lies in early diagnosis and surgical management before it leads to meningitis and avoidable mortality.

Objective: To evaluate the cases of post traumatic CSF rhinorrhea and analyze the parameters utilized to guide the management strategies. An attempt was made to come up with guidelines for its management in a tertiary care hospital.

Materials and Methods: This was a retrospective study in which all cases of traumatic CSF Rhinorrhea admitted to Tertiary care hospital were included. Patients were divided into three groups. First group was conservatively managed in which the rhinorrhea and serial imaging findings showed favourable response. In thesecond group patients were subjected to endoscopic repair by the ENT surgeon based on anatomical considerations. The third group included patients who were had failed the trial of conservative management and the site of leak did not favor endoscopic repair. The outcomes in all these groups were analyzed and conclusions drawn.

Observation: A total of 54 patients were included in the study which was conducted between Jan 2014 to 2020. 24 were successfully managed conservatively, 10 were managed with endoscopic repair and 20 were managed by bifrontal craniotomy and pedicled pericranial ACF Base repair. There was one case from the first group who developed CSF leak after one month necessitating ACF base repair. There was no recurrence reported in the cases managed endoscopically, whereas one case subjected to craniotomy had recurrence requiring lumbar drain placement. With each transcranial surgery there was a refinement in the technique further minimizing complications. We have elaborated on the surgical nuances to ensure better outcomes.

Inference: Pedicled pericranial flap ACF base repair is an elegant approach which requires an understanding of the mechanism of CSF leak from skull base fractures. This procedure can easily be mastered and when performed correctly provides best results for cases where there are multiple ACF defects, those not accessible by endoscope and also in those cases where imaging is not able to localize the exact site of defect leading to CSF rhinorrhea. Anosmia is an inevitable complication of this procedure. However, the trade off between mortality resulting from meningitis versus anosmia makes it a viable and attractive treatment option.

This is an Open Access (OA) journal, and articles are distributed under the terms of the [Creative Commons Attribution-NonCommercial-ShareAlike 4.0 License](https://creativecommons.org/licenses/by-nc-sa/4.0/), which allows others to remix, tweak, and build upon the work non-commercially, as long as appropriate credit is given and the new creations are licensed under the identical terms.

For reprints contact: reprint@ipinnovative.com

1. Introduction

Post-traumatic CSF leaks occurs in 1% to 3% of all closed traumatic brain injuries (TBI) in adults. In adults, 80% to 90% of CSF leaks result from head injuries.^{1,2} Traumatic CSF leak is reported in 10% to 30% of the skull base fractures in adults.² Anterior skull base fractures are five to six times more common than middle and posterior skull base fractures amongst all cases of skull bases fractures.^{3,4} Dural tears are common because of the firm adherence between the duramater and the skull base.^{5–7} CSF rhinorrhea may be accompanied with other symptoms, including clear nasal discharge and headache. Patients may further develop complications such as pneumocephalus, meningitis, or brain abscess.⁸ Post traumatic CSF leak can be potentially dangerous when it gets complicated with bacterial meningitis if not self-resolved.^{9,10} Meningitis is known to occur in 20 to 56% of patients and mortality may be as high as 10%.^{11–14} In few cases CSF Rhinorrhea and pneumocephalus may occur years after ACF Base fracture. This could be due to fresh trauma causing scar dehiscence.^{15–18} Early detection and immediate measures to stop CSF rhinorrhea plays an important role in preventing complications and improving outcomes. More than half of these CSF leak is presented within 48 hours of the trauma while almost all CSF leaks occur within 3 months in delayed manner.¹⁹ The most common fracture sites leading to CSF leaks following TBI are the frontal sinus (30.8%), sphenoid sinus (11.4–30.8%), ethmoid (15.4–19.1%), cribriform plate (7.7%), fronto-ethmoid (7.7%) and sphenothmoid (7.7%).^{9,20}

With the advent of endoscopy more and more cases are being successfully treated by endoscopic repair. Still there is a subset of patients who require and benefit from Trans cranial repair. This study attempts to classify patients with CSF rhinorrhea into three groups based on clinico-radiological findings and further proposes a management algorithm for definitive management.

2. Materials and Methods

This was a retrospective study carried from 2014 to 2020 in which all patients of traumatic CSF rhinorrhea reporting to tertiary care service hospital were included. Based on the clinico-radiological profile they were placed in three broad groups. Group A consisted of patients who were given a trial of conservative management. In case CSF rhinorrhea persisted beyond 7 days they were offered definitive surgery. Group B consisted of patients who were managed with Tran's nasal endoscopic repair. Group C consisted of patients who were treated with Trans cranial pedicled pericranial repair. The mechanism of injury, site of ACF base fracture, other associated lesions and

complications following treatment by all three modalities of treatment were analyzed and conclusions drawn. Based on the results from this study an algorithm has been drawn for management of Post traumatic CSF rhinorrhea.

2.1. Conservative management

The following guidelines were followed-

1. Bed Rest, Head elevation avoidance of straining, coughing sneezing with symptomatic therapy including laxatives, cough suppressants Etc.
2. CSF culture to be sent at time of presentation and Parenteral antibiotics started. In case of positive culture report; parenteral antibiotics should be continued for 2 weeks.
3. Lumbar Drain may be considered when leak persists
4. Conservative management was carried for 4 to 7 days. However, cases with large defects, other associated pathologies and enlarging pneumocephalus were offered early surgery.

2.2. Indications for surgery

1. Extensive bone defects in the cranial base, multiple fractures of the ethmoid bone and the posterior wall of the frontal sinus.
2. Leak is associated with concomitant pathologies requiring surgery. Concomitant treatments included elevation of depressed cranial vault fractures, repair of direct open head injury, and removal of space-occupying hematomas, facial fracture reduction & stabilization, external CSF drainage, decompression of the optic nerve, post-traumatic intracranial infection.
3. CSF leak is severe, recurrent, or not amenable to the endoscopic treatment
4. Persistent CSF Rhinorrhea which is not localizable by conventional imaging

2.3. Surgical technique of trans cranial pedicle peri cranial repair

1. Position: Head is placed in neutral position over silicone ring. This helps in easy maneuverability during bifrontal craniotomy and subsequently also permits sufficient extension during skull base repair.
2. While raising the bicoronal skin flap the pericranium is left intact. Following reflection of scalp flap, pericranial flap can be lifted more proximal from the incision site thereby providing a wide tension free pedicled flap for covering the ACF base. [Operative Figures 3 and 4].
3. Attempt to raise a single bone flap by carefully separating the midline superior sagittal sinus using sharp periosteal elevator.
4. Following durotomy ligate the sagittal sinus close to skull base [Operative Figure 5]

* Corresponding author.

E-mail address: drshashivadhanan@gmail.com (Shashivadhanan).

5. Avoid damage to bridging veins as much as possible, especially if they are large and dilated.
6. While retracting the brain move from lateral to medial part of ACF Base use a narrow brain spatula and decompress the cisterns in early part of surgery. Also avoid fixed brain retraction. These two maneuvers will reduce the incidence of lobar retraction injury. [Operative Figure 6].
7. The site of CSF fistula is identified keeping in view the imaging findings. The hall mark would be to find adherent arachnoid and brain parenchymal herniation into the defect.
8. For midline defect the olfactory nerve is sacrificed. This helps in lifting the bifrontal lobe away from the ACF Base thereby permitting full inspection and easy repair.
9. Flow able hemostats are a useful adjunct to occlude the defects prior to proceeding with repair.
10. While placing the carpet of pedicled pericranial flap ensure that it rolls over the ACF base margins loosely and adheres firmly to the entire ACF base. [Operative Figure 7].
11. Tacking sutures along the sphenoid ridge margins and on planum sphenoidale help in preventing slippage of graft.
12. Ensure loose but watertight duroplasty after repositioning the frontal lobe. The tamponed effect due to frontal lobe ensures firm adherence of pericranial graft over the ACF Base. [Operative Figure 8].
13. Any skull base defect more than 5 square mm in area will preferably require bone graft reinforcement before doing carpet repair.
14. Following dural closure a valsalva maneuver will help in confirming the watertight closure.
15. Cranialization of frontal sinus if exposed must be performed meticulously. Frontal bone flap is then repositioned and fixed. [Operative Figure 9].
16. During anatomical closure a subgaleal drain with moderate suction pressure ensures early wound healing.

3. Observation

A total of 54 cases were included in this study. 30 cases were given a trial of conservative management. Of these 06 had persistent CSF rhinorrhea beyond 7 days. They were thereby transferred to Group B and C (4 of those to endoscopy group i.e. Group B and 2 to Trans cranial group i.e. Group C). Hence, 24 were managed conservatively, 10 by Endoscopic repair and 20 by transcranial repair.

Evaluation of trauma mechanism showed that two-wheeler road traffic accidents was the commonest cause of trauma leading to CSF rhinorrhea (Table 1). A study of site of trauma at ACF Base revealed that cribriform plate was the commonest site of fracture and CSF rhinorrhea (Table 2).

The complications of each modality of management (Table 3) showed that endoscopically managed cases had no failures. Of total 54 cases, 8 required early surgery based on clinico-radiological presentation. (Table 4).

The Trans cranial repair although more demanding was easy to master. With each successive procedure the complications and recovery rates reduced thereby improving outcomes. In comparison with other management modalities it had certain distinct advantages and disadvantages.

3.1. Observed advantages

1. Allows complete extradural and intradural exploration of ACF Base
2. Concomitant pathologies can be treated
3. Along with maxillofacial surgeon all fractures can be addressed in the same sitting
4. Centers where endoscopic facility or expertises do not exist can very well treat all cases by this technique.

3.2. Observed disadvantages

1. Extensive procedure with operative complications of olfactory nerve injury, retraction related injury and cortical damage due to ligation of sagittal sinus or bridging veins.
2. Prolonged hospital stay
3. Potential risk of post-operative cosmetic deformity

4. Result

Our study shows that based on the presentation and radiological findings post traumatic CSF rhinorrhea can be managed conservatively, or by definitive surgery. Majority of the case respond well to conservative management (Figure 2) although endoscopic repair offers lesser morbidity its applicability is only for a select group of patients having small midline defects. Pedicle pericranial transcranial repair is a procedure which can be performed in a patient group with definite indication. The outcomes are reasonable and the morbidity is acceptable considering the fact that it results in prevention of meningitis and other serious infections of Central Nervous system. In our study except for one case which required confirmation with beta 2 transferrin, rest all were diagnosed radio logically and with CSF glucose estimation. Based on location of ACF base defect Trans cranial surgery was offered in all cases as shown in Radiographic picture [Radiograph Figures 10, 11, 12 and 13] Based on our experience we have proposed a management algorithm for management of Traumatic CSF Rhinorrhea. (Figure 1)

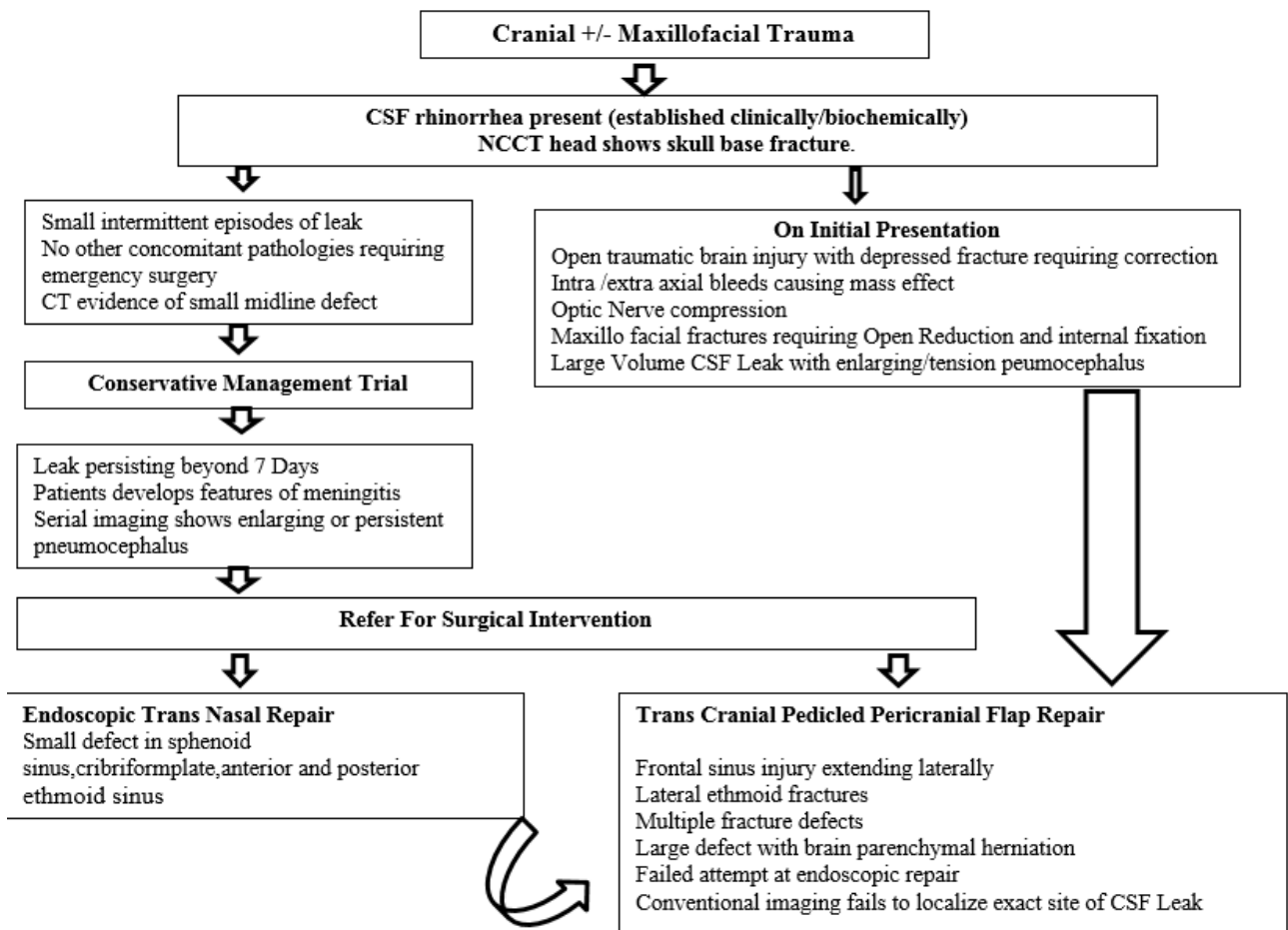


Fig. 1: Algorithm proposed for management of Post Traumatic CSF Rhinorrhea

Table 1: Mechanism of trauma leading to anterior skull base fracture with CSF Rhinorrhea

Trauma Mechanism	Numbers
Road Traffic Accident (Two wheeler)	43
Fall from height	06
Assault	02
Other	03

Table 2: Location of Anterior skull base fractures

Fracture and defect site	Numbers
Frontal Sinus	04
Cribriform Plate	08
Ethmoid	02
Sphenoid	02
Planum sphenoid	01
Mltiple site fractures	04

Table 3: omplications following management of CSF Rhinorrhea in all three groups

Management Group	Total cases enrolled	Complications
Conservative management	30	06 referred for surgical intervention following failure to control CSF leak in spite 07 days of conservative management.
Endoscopic repair	10	No complication or failure
Trans cranial repair	20	01 – frontal hematoma 02 – Post Operative head ache 01- Recurrence required lumbar drain placement

5. Discussion

British neurosurgeon Hugh Cairns, first introduced a classification scheme for CSF rhinorrhea in 1937. He

differentiated between spontaneous and postoperative CSF leak.¹⁹ In 1926, Dandy was the first to successfully repair a CSF fistula using a tensor fascia lata graft through a transcranial, intradural approach.²¹ Followings successful repair technique, various techniques for anterior

Table 4: Clinical presentation of cases subjected to early surgery (total 08)

Clinico Radiological picture at presentation	Total number of cases
Depressed frontal bone fracture	04
Intracerebralhaemorrhage causing mass effect	02
Profuse CSF leak with enlarging pneumocephalus	02
ConcomittantMaxilofacial fractures requiring open reduction & internal fixation	05
Optic Nerve compression	01

CSF RHINORRHEA

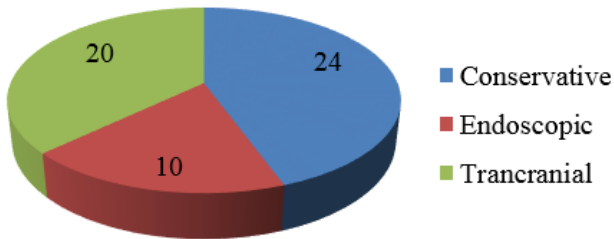


Fig. 2: Showing the distribution of 54 cases managed conservatively, Endoscopically and by Trancranial surgery

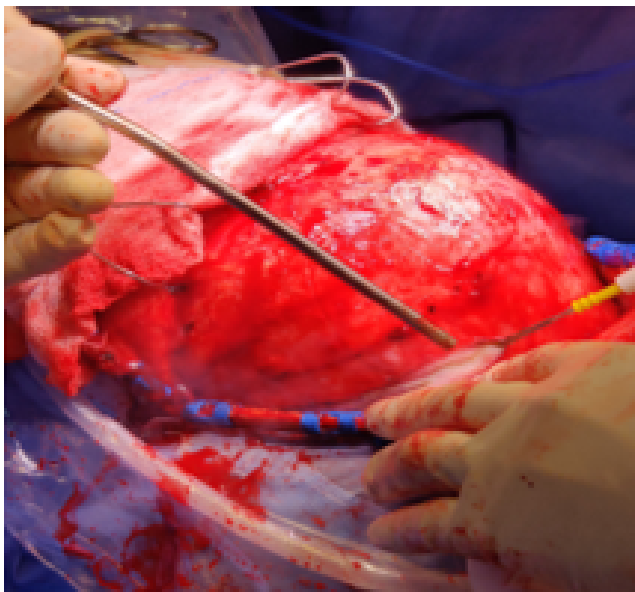


Fig. 3: Operative Harvesting of Pericranial Flap being done proximal to scalp incision so as to get enough Flap area for ACF base repair.

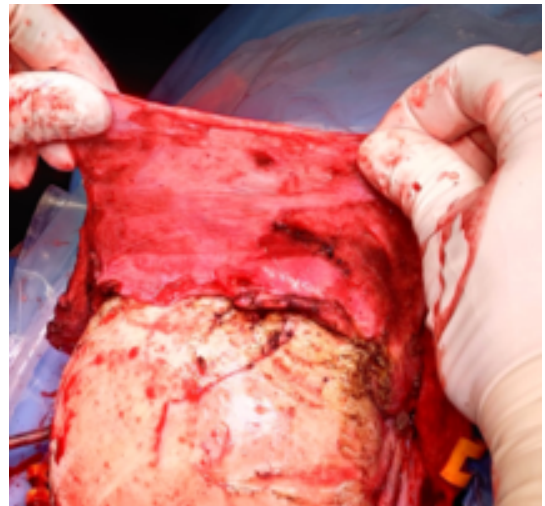


Fig. 4: Operative Pedicled Pericranial Flap lifted from the underlying frontal bone.

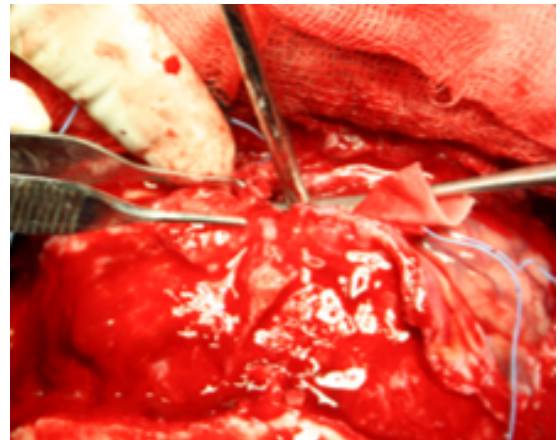


Fig. 5: Operative Durotomy with ligation of Superior Sagittal Sinus close to Skull base

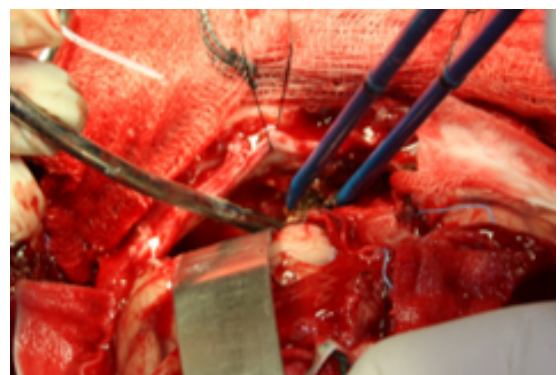


Fig. 6: Operative Dynamic frontal lobar retraction to inspect the defect and minimize lobar retraction injury.

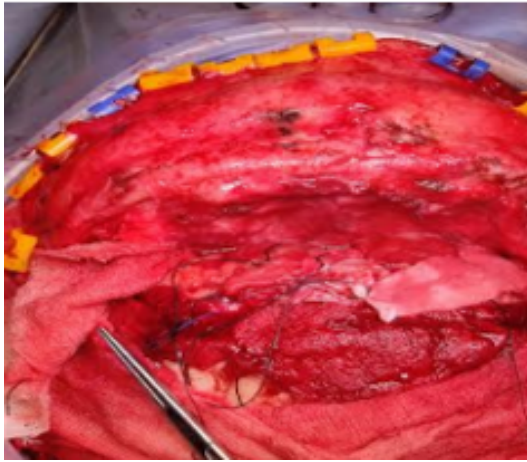


Fig. 7: Operative ACF Base covered with Pedicled Pericranial flap by rolling it over the entire ACF base.

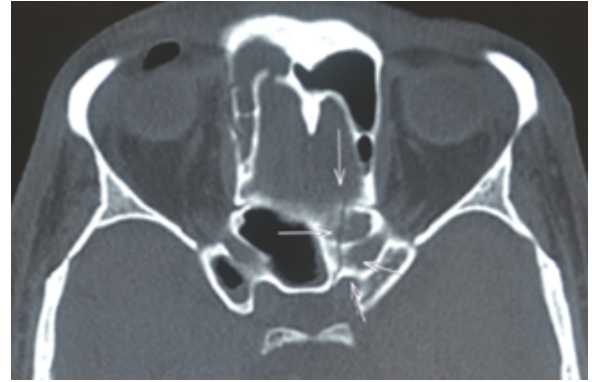


Fig. 10: Radiograph Axial CT image showing planum fracture

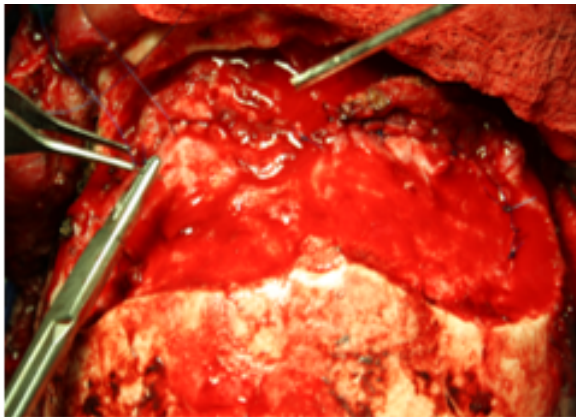


Fig. 8: Operative Water tight duroplasty

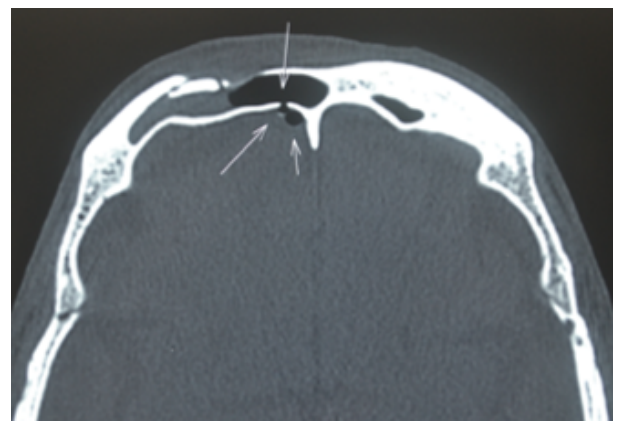


Fig. 11: Radiograph Axial CT image showing frontal sinus fracture

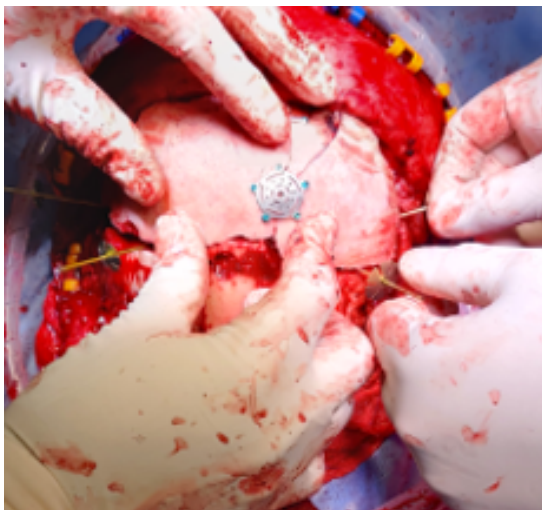

Fig. 9: Operative Free bone flap being fixed

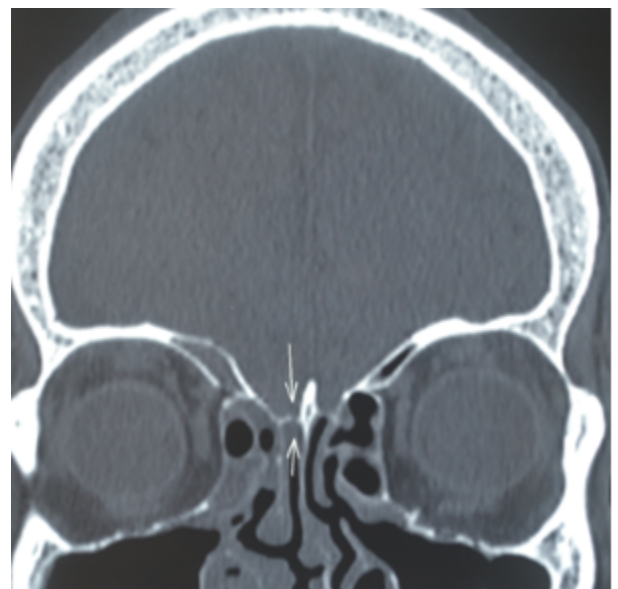

Fig. 12: Radiograph Coronal CT image showing cribriform plate fracture

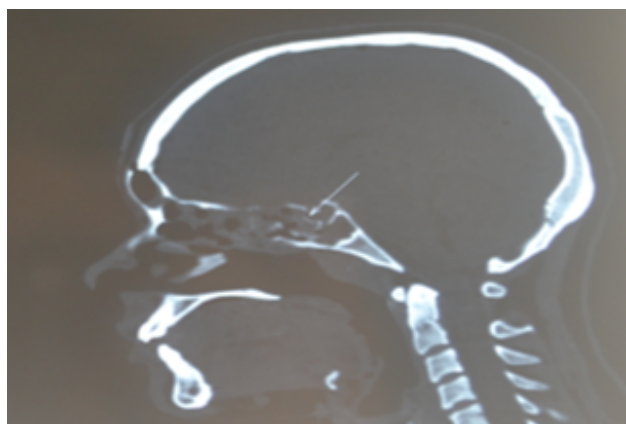


Fig. 13: Radiograph Sagittal CT image showing Pituitarysellar floor fracture

cranial fossa reconstruction after extensive craniotomy for addressing various concomitant pathologies, have been described in the literature. These range from no formal reconstruction to elaborate free flaps with microvascular anastomosis. As on date there is no gold standard technique for any given situation. Reconstruction must be tailored depending on the anatomical site and extent of dural and cranial defect. In 1981, German otolaryngologist Malte Wigand did pioneering work in the use of intraoperative endoscope for repair of spontaneous CSF rhinorrhea.²² since then rapid advances in endoscopic techniques have popularized the use of endoscopy for repair of anterior cranial fossa CSF leaks.^{9,23}

Endoscopic techniques prove advantageous in the repair of small, spontaneous, and localizable CSF fistulas because they are lesser invasive in addition to offering the advantage of reducing blood loss and operative time.²⁴ In present day, Classic surgical approaches still play a role and, in fact, prove superior in select cases where the dural defect is extensive or the CSF fistula is not localizable.²⁵ The rationale behind the need for a watertight dural closure is to effectively separate the intradural and extradural compartments to reduce the postoperative morbidity and mortality associated with persistent CSF leak. We think the advantage of our closure technique is that by using generously sized pericranial graft, it allows the brain to relax in its normal anatomical position while the natural weight of the frontal lobe may further reinforce this layered closure by tamponade. Defect size is not a limiting factor because large vascularized pericranium grafts can be easily harvested and hitched into position. More importantly, this technique does not require a significant learning curve and is easily mastered. Disadvantage of this technique is that anosmia becomes a permanent disability. Also damage to the bridging veins during ligation of superior sagittal sinus may lead to prolonged hospital stay and morbidity. Although an extensive procedure the dividends are rich and outcomes

good.

6. Conflicts of Interest

The authors declare that there are no conflicts of interest regarding the publication of this paper.

7. Source of Funding

None.

References

- Schlosser RJ, Bolger WE. Nasal cerebrospinal fluid leaks: critical review and surgical considerations. *Laryngoscope*. 2004;114(2):255–65. doi:10.1097/00005537-200402000-00015.
- Yilmazlar S, Arslan E, Kocaeli H, Dogan S, Aksoy K, Korfali E, et al. Cerebrospinal fluid leakage complicating skull base fractures: analysis of 81 cases. *Neurosurg Rev*. 2006;29(1):64–71. doi:10.1007/s10143-005-0396-3.
- Lewin W. Cerebrospinal fluid rhinorrhea in nonmissile head injuries. *Clin Neurosurg*. 1964;12(1):237–52. doi:10.1093/neurosurgery/12.CN_suppl_1.237.
- Loew F, Pertuiset B, Chaumier EE, Jaksche H. Traumatic, spontaneous and postoperative CSF rhinorrhea. *Adv Tech Stand Neurosurg*. 1984;11:169–207. doi:10.1007/978-3-7091-7015-1_6.
- Abuabara A. Cerebrospinal fluid rhinorrhoea: diagnosis and management. *Med Oral Patol Oral Cir Bucal*. 2007;12(5):397–400.
- Asano T, Ohno K, Takada Y, Suzuki R, Hirakawa K, Monma S, et al. Fractures of the floor of the anterior cranial fossa. *J Trauma*. 1995;39(4):702–6. doi:10.1097/00005373-199510000-00016.
- Calcaterra TC. Diagnosis and management of ethmoid cerebrospinal rhinorrhea. *Otolaryngol Clin North Am*. 1985;18(1):99–105.
- Kaufman BA, Tunkel AR, Pryor JC, Rg D. Meningitis in the neurosurgical patient. *Infect Dis Clin North Am*;4(4):677–701.
- Banks CA, Palmer JN, Chiu AG, O'malley BW, Woodworth BA, Kennedy DW, et al. Endoscopic closure of CSF rhinorrhea: 193 cases over 21 years. *Otolaryngol Head Neck Surg*. 2009;140(6):826–33. doi:10.1016/j.otohns.2008.12.060.
- Carter DA, Mehelas TJ, Savolaine ER, Dougherty LS. Basal skull fracture with traumatic polycranial neuropathy and occluded left carotid artery: Significance of fractures along the course of the carotid artery. *J Trauma*. 1998;44(1):230–5. doi:10.1097/00005373-199801000-00039.
- Dagi FT, George ED. Management of cerebrospinal fluid leaks, in Schmidek HH, Sweet WH (eds): *Operative Neurosurgical Techniques: Indications, Methods and Results*. Orlando, Grune and Stratton; 1988. p. 49–69.
- Brodie HA. Prophylactic antibiotics for posttraumatic cerebrospinal fluid fistulae. A meta-analysis. *Arch Otolaryngol Head Neck Surg*. 1997;123(7):749–52. doi:10.1001/archotol.1997.01900070093016.
- Klustersky J, Sadeghi M, Brihaye J. Antimicrobial prophylaxis in patients with rhinorrhea or otorrhea: A double-blind study. *Surg Neurol*. 1976;6(2):111–4.
- Villalobos T, Arango C, Kubilis P, Rathore M. Antibiotic prophylaxis after basilar skull fractures: A meta-analysis. *Clin Infect Dis*. 1998;27(2):364–9. doi:10.1086/514666.
- Scholsem M, Scholtes F, Fr derick collignon. Surgical management of anterior cranial base fracture with cerebrospinal fluid fistulae: A single Institution experience. *Neurosurgery*. 2008;62(2):463–9. doi:10.1227/01.neu.0000316014.97926.82.
- Choi D, Spann R. Traumatic cerebrospinal fluid leakage: Risk factors and the use of prophylactic antibiotics. *Br J Neurosurg*. 1996;10(6):571–5. doi:10.1080/02688699646880.
- Eljamel MS, Foy PM. Post-traumatic CSF fistulae, the case for surgical repair. *Br J Neurosurg*. 1990;4(6):479–83. doi:10.3109/02688699008993796.

18. Hubbard JL, McDonald TJ, Pearson BW, Laws ER. Spontaneous cerebrospinal fluid rhinorrhea: Evolving concepts in diagnosis and surgical management based on the Mayo Clinic experience from 1970 through 1981. *Neurosurgery*. 1985;16(3):314–21. doi:10.1227/00006123-198503000-00006.
19. Oh JW, Kim SH, Kumwhang. Traumatic Cerebrospinal Fluid Leak: Diagnosis and Management. *Korean J Neurotrauma*. 2017;13(2):63–7.
20. Reilly PL, Wormald PJ, Marshall LF. Traumatic cerebrospinal fluid fistulas. In: Winn HR, editor. Youmans and Winn neurological surgery. Edn. 7th. Philadelphia, PA: Saunders; 2016. p. 2980–7.
21. Dandy WD. Pneumocephalus (intracranial pneumocele or arocele). *Arch Surg*. 1926;12(5):949–82. doi:10.1001/archsurg.1926.01130050003001.
22. Yadav YR, Parihar V, Janakiram N. Endoscopic management of cerebrospinal fluid rhinorrhea. *Asian J Neurosurg*. 2016;11(3):183–93.
23. Bell RB, Dierks EJ, Homer L, Potter BE. Management of cerebrospinal fluid leak associated with craniomaxillofacial trauma. *J Oral Maxillofac Surg*. 2004;62(6):676–84. doi:10.1016/j.joms.2003.08.032.
24. Locatelli D, Rampa F, Acchiardi I, Bignami M, Bernardi FD, Castelnovo P, et al. Endoscopic endonasal approaches for repair of cerebrospinal fluid leaks: Nine-year experience. *Neurosurgery*. 2006;58(2):246–57.
25. Samii M, Draf W. Indication and treatment of frontobasilar rhinorrhea from the ent-surgical and neurosurgical point of view. *Laryngol Rhinol Otol (Stuttg)*. 1978;57(8):689–97.

Author biography

Shashivadhanan, Professor

Abhishek Mishra, Radiologist

Cite this article: Shashivadhanan, Mishra A. A retrospective study to analyze treatment of post traumatic cerebro spinal fluid rhinorrhea and role of trans cranial pedicled pericranial repair in present day context. *IP Indian J Anat Surg Head, Neck Brain* 2021;7(4):111-118.