

Content available at: <https://www.ipinnovative.com/open-access-journals>

IP Indian Journal of Anatomy and Surgery of Head, Neck and Brain

Journal homepage: <https://www.ijashnb.org/>

## Editorial

# Ranula of the tongue – Recent advances in management

Kaushik Bhattacharya<sup>1,\*</sup>, Neela Bhattacharya<sup>2</sup>, Aditya Shikar Bhattacharya<sup>3</sup>

<sup>1</sup>Dept. of Surgery, CAPFs Composite Hospital BSF Kadamtala, West Bengal, India

<sup>2</sup>Dept. of Surgery, Anandaloke Multispeciality Hospital, Siliguri, West Bengal, India

<sup>3</sup>Dept. of Surgery, Stanley Medical College, Chennai, Tamil Nadu, India



### ARTICLE INFO

#### Article history:

Received 25-08-2022

Accepted 12-10-2022

Available online 21-10-2022

#### Keywords:

Plunging ranula

sublingual gland

Radiotherapy

sclerotherapy

### ABSTRACT

The treatment of ranula ranges from conservative in congenital ranula to non-operative management like laser, radiotherapy, cryosurgery or sclerotherapy and finally the best and time tested surgical management with minimal or negligible recurrence. Surgical management should be recommended to all in case of plunging ranula with symptoms.

This is an Open Access (OA) journal, and articles are distributed under the terms of the [Creative Commons Attribution-NonCommercial-ShareAlike 4.0 License](https://creativecommons.org/licenses/by-nc-sa/4.0/), which allows others to remix, tweak, and build upon the work non-commercially, as long as appropriate credit is given and the new creations are licensed under the identical terms.

For reprints contact: [reprint@ipinnovative.com](mailto:reprint@ipinnovative.com)

## 1. Introduction

The term ranula is from the Latin word *rana*, meaning frog because of it resembling a frog's underbelly bulge. Hippocrates described ranulas first and he thought they were secondary to inflammation. Ambroise Paré postulated that ranulas may be the descent of brain or pituitary matter, and W. Boyd wrote that ranula is a dilatation the submandibular gland duct. Aurelius Cornelius Celsus (25BC to 50 AC) described the morphological features of a ranula in his seventh book.. Avicenna (980-1037 AC) described the feature of the ranula under the tongue as a frog shaped mass in his book "*Canon of Medicine*". Al Zahrawi (936-1013 AC), wrote in "*Al-Tasrif*" about the ranula as, "it is a tumour similar to a frog generated by pure expectoration or by expectoration mixed with black material; its signal is a whitish colour with moist expectoration and its dark mixed colour is characterized as black, rigid and with low humidity".<sup>1</sup>

Ranulas are rare mucocoeles that form in the floor of the mouth. They present through the mylohyoid muscle

dehiscence, which is located at the anterior 2/3 of the floor and usually involves the major salivary glands. Most often, the ranula originates in the body of the sublingual gland, in the sublingual gland ducts, (the ducts of Rivinus,) and infrequently from the minor salivary glands. The recommendation in cases of congenital ranula is that the patient be observed for six months, before embarking on any treatment.

## 2. Recent Advances in Ranula management

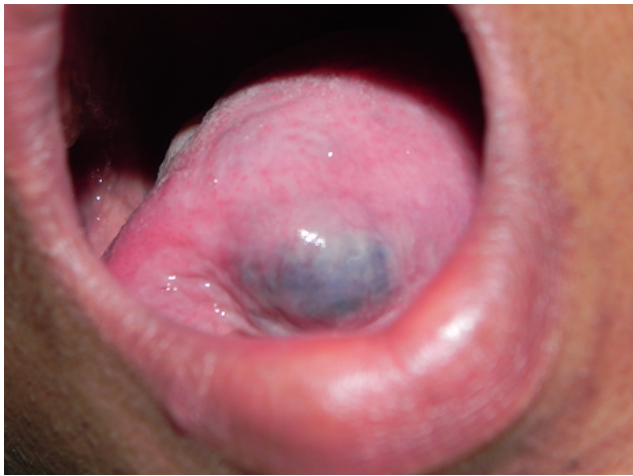In his "Journey to Bayonne" (1564), Ambroise Pare describes the case of a Spanish gentleman who "came to be touched by the late King Charles for the King's evil." He found that his patient had a large cervical abscess from which he evacuated "a great quantity of worms," and he then proceeded to remove five salivary calculi.

Surgery was the preferred treatment of Ranula traditionally. In recent times, newer non-invasive medical management like the use of lasers are gaining popularity in the management of ranula.

Historically, a variety of treatments for ranula has been suggested. They include aspiration of the cystic

\* Corresponding author.

E-mail address: [kbhattacharya10@yahoo.com](mailto:kbhattacharya10@yahoo.com) (K. Bhattacharya).



**Fig. 1:** Sublingual ranula

fluid, sclerotherapy, marsupialization, incision and drainage, ranula excision only, and excision of the sublingual gland with or without the ranula.(Figure 1)

The oldest and most widely used therapy for oral ranula is marsupialization. This is an easy procedure where the roof of the cyst is excised along the attachment of its borders to surrounding tissues. But this procedure recorded a very high recurrence rate of 61–89% within 6 weeks to 12 months of surgery.<sup>2</sup> Micro marsupialization has also been described which involves the placement of a Seton for a minimum of 1 week during which an epithelial tract forms to allow for mucus drainage between the surface and the underlying salivary glandular tissue. Sclerotherapy with Bleomycin and OK-432 have also been used successfully to ablate ranulas. For cases of plunging ranula, Carbon dioxide laser has been tried. Another non operative option and a worthwhile effective substitute was low dose radiotherapy (20–25 gray). Using a low dose and protecting the contralateral parotid gland, many dangerous side effects of radiotherapy like xerostomia can be prevented.

Recently, percutaneous aspiration of ranulas and chemical ablation of the salivary gland from which it originates, is seen as a safe and effective management with a success rate of 87.5%.<sup>3</sup> Ethanol ablation is also a safe and non-invasive treatment for ranulas and has a significantly better outcome in patients with ≤12 months of symptoms.<sup>4</sup> Liquid nitrogen cryosurgery for management of plunging ranulas may become a primary treatment modality prior to surgery in children.<sup>5</sup>

### 3. Surgical Management of Ranula – Recent Advances

The best treatment for a plunging ranula is excision of the lesion along with the involved gland (usually sublingual gland). But the complications of surgery are the recurrence of the lesion, injury to the duct of submandibular gland,

damage to the lingual nerve, which may result in a decrease in the sensation of the tongue, hematoma, infection, wound dehiscence and marginal mandibular nerve paralysis.

Excision of the sublingual gland is done via the intraoral or the transcervical route in plunging ranula. With a transcervical approach, total excision of the sublingual gland is challenging because it requires painstaking division of the mylohyoid muscle in the floor of mouth. It may be considered in review cases and when the plunging ranula is large.<sup>2</sup> Currently, the treatment of choice is intraoral excision of the gland and drainage of the associated cervical content.

A few authors recently recommended the use of loose suturing in the floor of the mouth following removal of the ranula and sublingual gland to allow free drainage of residual saliva into the floor of the mouth to avoid refilling of the potential space left after the surgery in order to prevent recurrence.<sup>6</sup>


### 4. Conflict of Interest


None.


### References

1. Bhattacharya K, Bhattacharya N. Abu Al Qasim Al Zahrawi-the Father of Operative Surgery. *Indian J Surg.* 2022;61(1):35–7.
2. Olojede A, Ogundana OM, Emeka C, Adewole RA, Emmanuel MM, Gbotolorun OM. Plunging ranula: surgical management of case series and the literature review. *Clin Case Rep.* 2017;6(1):109–14.
3. Brannan ZJ, Lubeley LJ, Sutphen SA, Murakami JW. Percutaneous treatment of ranulas: ultrasound-guided drainage with salivary gland chemical ablation. *Pediatr Radiol.* 2019;49(6):801–7.
4. Ryu KH, Lee JH, Lee JY, Chung SR, Chung MS, Kim HW. Ethanol Ablation of Ranulas: Short-Term Follow-Up Results and Clinicoradiologic Factors for Successful Outcome. *AJNR Am J Neuroradiol.* 2017;38(9):1794–8.
5. Aulakh KK, Brar RS, Azad A, Sharma S, Anand A, Jyoti B. Cryotherapy for Treatment of Mouth Mucocele. vol. 22. *Niger J Surg;* 2016. p. 130–3.
6. Daniels JS, Albakry I, Braimah RO, Samara MI. Oral ranulas: A 15-year retrospective clinico-surgical evaluation in a major referral hospital in the Southern Province of the Kingdom of Saudi Arabia. *Saudi J Otorhinolaryngol Head Neck Surg.* 2020;22(2):50–6.

### Author biography

**Kaushik Bhattacharya**, Specialist (Surgery)  <https://orcid.org/0000-0002-4825-9148>

**Neela Bhattacharya**, Project Director  <https://orcid.org/0000-0002-9414-1503>

**Aditya Shikar Bhattacharya**, Medical Student  <https://orcid.org/0000-0002-5241-5318>

**Cite this article:** Bhattacharya K, Bhattacharya N, Bhattacharya AS. Ranula of the tongue – Recent advances in management. *IP Indian J Anat Surg Head, Neck Brain* 2022;8(3):82-83.