

Content available at: <https://www.ipinnovative.com/open-access-journals>

IP Indian Journal of Anatomy and Surgery of Head, Neck and Brain

Journal homepage: <https://www.ijashnb.org/>

## Original Research Article

## An institutional analysis of the outcomes of endonasal endoscopic anterior skull base surgery

Diksha Kumari<sup>1</sup>, Amit Kumar Sharma<sup>1</sup>, Brajesh Kumar<sup>1</sup>, Jyoti Singh<sup>1</sup>, Shruti Jha<sup>1</sup>, Rakesh Kumar Singh<sup>1,\*</sup><sup>1</sup>Dept. of Otorhinolaryngology, Indira Gandhi Institute of Medical Science, Patna, Bihar, India

## ARTICLE INFO

## Article history:

Received 26-09-2022

Accepted 03-10-2022

Available online 21-10-2022

## Keywords:

Endonasal

Endoscopic

Anterior skull base

Outcome

## ABSTRACT

**Background:** Endoscopic skull base surgery is an emerging surgical technique that recolonized the resection of skull base lesions. The present study analyzed the outcome of the endoscopic endonasal anterior skull base.

**Materials and Methods:** A retrospective data review of endoscopic endonasal anterior skull base surgeries performed from 2017 to 2022. Minimum follow-up was done 6 months postoperatively.

**Results:** 63 cases of anterior skull base pathologies have been operated out of which 2 cases of meningioma, 3 cases of meningoencephalocele, 5 olfactory neuroblastoma, 18 angiofibroma extending till anterior skull base, 8 CSF rhinorrhea repair, 12 pituitary macroadenoma, 8 cerebral mucormycosis and 7 sino-nasal mass with intracranial extension have been operated. Residual disease was left in 10 cases, the rest all the masses were completely removed. The overall complication rate was 28.6 percent. Three mortalities occur a few months post-operatively of which 2 were cerebral mucormycosis and one was sino-nasal malignancy with intracranial extension.

**Conclusion:** Endoscopic endonasal anterior skull base surgeries are safe surgical procedure that provides a high degree of disease clearance and negligible complications.

This is an Open Access (OA) journal, and articles are distributed under the terms of the [Creative Commons Attribution-NonCommercial-ShareAlike 4.0 License](https://creativecommons.org/licenses/by-nc-sa/4.0/), which allows others to remix, tweak, and build upon the work non-commercially, as long as appropriate credit is given and the new creations are licensed under the identical terms.

For reprints contact: [reprint@ipinnovative.com](mailto:reprint@ipinnovative.com)

## 1. Introduction

The skull base is divided into compartments corresponding to the division of the brain into anterior, middle, and posterior cranial fossae. The anterior skull base (ASB) is formed laterally by the orbital plates of the frontal bone, medially by the cribriform plate and crista galli of the ethmoid bone, and posteriorly by the planum sphenoidale and lesser wings of the sphenoid bone.<sup>1</sup> The skull base is one of the most inaccessible anatomical regions of the human body. The anatomy of the skull base is complex with multiple neurovascular structures in a small space. It can be defined as the portion of the skull base adjacent

to the anterior cranial fossa. Anterior skull base separates the intracranial from the sino-nasal and facial regions. Surgeons need to have adequate knowledge of endoscopic nasal anatomy before embarking on treating lesions of these complex regions.

The basic principle of anterior skull base surgery is to provide adequate exposure to enable three-dimensional resection of skull base tumors. Anterior skull base surgery has evolved greatly with a better understanding of anatomy, pathology, imaging, and surgical technique.<sup>2,3</sup> Resection of skull base neoplasms may be accomplished via traditional open, endoscopic, or combined surgical approaches. The endoscopic endonasal approach has become the standard of care because it provides minimally invasive access to a large portion of the skull base, including anterior

\* Corresponding author.

E-mail address: [rkent5@gmail.com](mailto:rkent5@gmail.com) (R. K. Singh).

and middle cranial fossae and sellae and suprasellar and para-sellar regions, and it has been associated with lower surgical morbidity and shorter length of hospitalization.<sup>1,3</sup> The proximity to vital structures prevents intensification for treatment either by surgery or radiotherapy, without unduly increasing morbidity. Endoscopic skull base surgery is revolutionizing skull base surgery. In the past, transfacial and transcranial open surgical approaches were utilized, which can alter craniofacial development. With the advent of endoscopic skull base surgery, minimally invasive techniques can be utilized, which have similar efficacy and safety as traditional approaches. As endoscopic techniques advance and surgeons become more familiar with techniques, the morbidity associated with skull base surgery may decrease.<sup>4,5</sup> The invention of the nasal endoscopic system & the related instruments revolutionised the approach.

## 2. Materials and Methods

A retrospective data review of 63 patients who underwent endoscopic endonasal anterior skull base surgeries performed from 2017 to 2022. Minimum follow-up was done 6 months postoperatively. Patients who presented to the ENT OPD of the premier tertiary care center with complaints such as headaches, nasal obstruction, blurred vision, dizziness, seizure, facial pain, and epistaxis were thoroughly examined and were subjected to radiological examinations at the Radiology department of our institution. After confirming the diagnosis and carrying out relevant investigations patients were properly planned for the procedure.

### 2.1. Inclusion criteria

Patients were willing to take part and give written informed consent, Patients attending the department of ENT irrespective of sex in adults of all age groups, with a confirmed diagnosis of various anterior skull base pathologies such as meningioma, pituitary macroadenoma, meningoencephalocele, angiofibroma, etc.

### 2.2. Exclusion criteria

1. Very large sized tumor.
2. Tumors extending beyond the limits of endoscopic surgery.
3. Critically ill patients.

### 2.3. Methodology

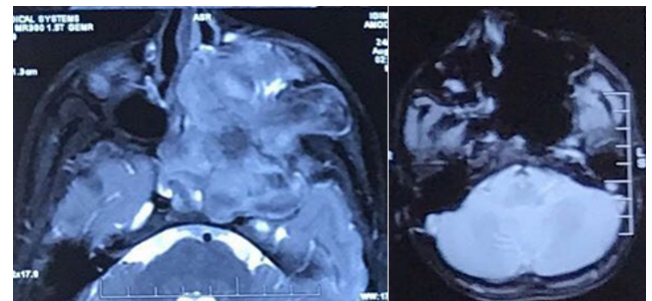
Patients who planned to undergo surgeries after considering all the inclusion and exclusion were subjected to relevant investigations. Under general anesthesia using a Storz 0°, 30° and 70° endoscope debridement of the mass/tumour was done. Intraoperatively Haddad's flap was harvested and was

used for the reconstruction of the skull base defect being created. All the surgeries were done by a single experienced surgeon in the same institution.

After surgery, the patients were followed up regularly for 6 months, and a few patients till one year were looked for residual disease and complications. Complications such as CSF Leaks, Anosmia, Epistaxis, Subdural hematomas, Visual Disturbances, Chronic rhinosinusitis (CRS), Meningitis, Hypopituitarism, and Olfactory Dysfunctions were considered.

**Table 1:** Showed the distribution of anterior skull base lesions.

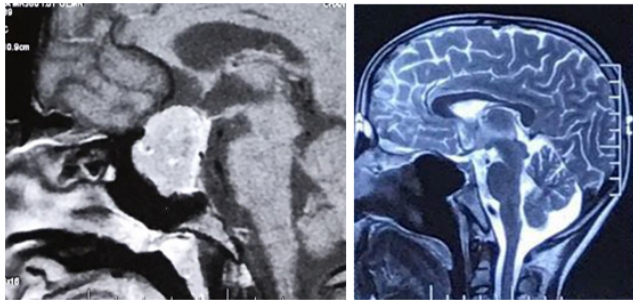
S. No.	Type of Lesions	Number of cases	Percentage
1	Meningioma	2	3.1
2	Meningo-encephalocele	3	4.8
3	Pituitary macroadenoma	12	19
4	CSF Rhinorrhea	8	12.8
5	Olfactory neuroblastoma	5	8
6	Sinonasal malignancy with intracranial extension	7	11
7	Angiofibroma with intracranial extension	18	28.6
8	Cerebral mucormycosis	8	12.8
9	Total	63	100



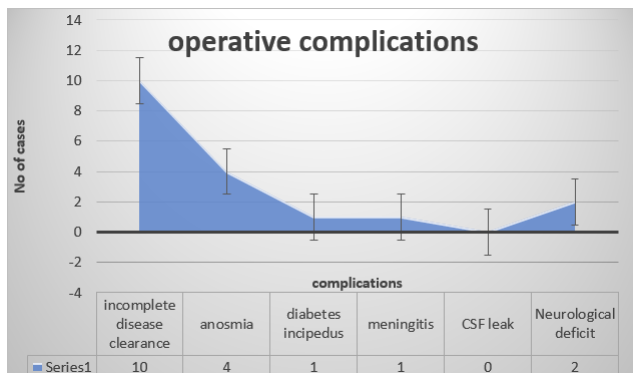
**Fig. 1:** Pre-operative angiofibroma extending to orbit, middle cranial fossa and post-operative tumour clearance.

## 3. Results

A retrospective review yielded that till April 2022, 63 cases of anterior skull base pathologies have been operated out of which 2 cases of meningioma, 3 cases of meningoencephalocele, 5 olfactory neuroblastoma, 18 angiofibroma extending till anterior skull base, (Figure 1) 8 CSF rhinorrhea repair, 12 pituitary macroadenoma, (Figure 2) 8 cerebral mucormycosis and 7 sino-nasal mass



**Fig. 2:** Pre-operative and post-operative pictures of pituitary macroadenoma



**Fig. 3:** Showed the complications encountered during endonasal endoscopic skull base surgery

with intracranial extension have been operated. (Table 1) The overall complication rate was 28.6 percent of which the most common was residual disease which was left in 10 cases. (Figure 3) The other complications were anosmia which occurred in 4 cases of either sino-nasal malignancies or cerebral mucormycosis. The permanent visual defect occurred in two cases of Pituitary macroadenomas which were presented a month before the surgical procedure. The transient diabetes insipidus and meningitis occurred in one case each of those was successfully managed conservatively. Most of the residual disease occurred in either sino-nasal malignancies (two) or cerebral mucormycosis (three). In two cases large pituitary macroadenomas were incompletely removed in which the supra cellular lesion was removed by open approaches. The residual disease was left in two cases of angiofibroma with intracranial extension which was removed in the second staged surgery. The mortalities occurred one due to sino-nasal malignancies and two due to cerebral mucormycosis. We encountered no CSF leak in our series.

#### 4. Discussion

Anterior skull base tumors are diverse groups of diseases with different tumour biology, treatment approaches, and clinical behaviour. The proximity to vital structures

prevents intensification for treatment either by surgery or radiotherapy, without unduly increasing morbidity. Surgery remains the important modality of treatment of anterior skull base tumors. The goals of anterior skull base surgery have remained constant. These goals include 1. Resection of the tumour with three-dimensional negative margins. 2. Preservation of important structures and their function. 3. Reconstruction of defect to maintain function and aesthesis.<sup>4-6</sup> Although skull base surgery historically has rarely been performed in patients 70 years or older in the past owing to concern for relatively higher operative risk and poor outcomes, it is becoming increasingly common. The endoscopic endonasal approach has become the standard of care because it provides minimally invasive access to a large portion of the skull base, including anterior and middle cranial fossae and sellar and suprasellar and parasellar regions, and it has been associated with lower surgical morbidity and shorter length of hospitalization.<sup>1,3</sup> There are various approaches to the anterior skull base namely: transfrontal, transcribriform, transplanum, transsellar, transclival, transodontoid. Various pathologies encountered are olfactory groove meningioma, olfactory neuroblastoma, meningioma, giant pituitary adenomas, craniopharyngiomas, rathke left cyst, etc.

The traditional skull base approach is transellar, which allows access to the sella of the sphenoid sinus and suprasellar region. This approach can be used for lesions in the middle cranial fossae such as pituitary tumors and craniopharyngiomas. The transellar approach involves lateralization or removal of the middle turbinate of bilateral nasal cavities to allow the nasal endoscopes to be introduced. Wide sphenoidotomies are performed extending from the lamina papyracea laterally to the planum tuberculum rostrally and the clivus caudally. This allows for visualization and access to the internal carotid arteries, optic nerves, planum sphenoidale, clivus, and medial cavernous sinus. If there is a significant suprasellar extension of a lesion, the floor of the sphenoid sinus can be drilled back to the clivus.<sup>7-9</sup> Neoplasms that most commonly occupy the orbital apex and can be treated by the transnasal endoscopic approach (TEA) include cavernous hemangioma, schwannoma, and fibrous dysplasia.<sup>5</sup> Petrous apex lesions may remain undetected for extended periods because patients often complain of vague or indistinct symptoms that delay diagnosis. Headaches, atypical facial pain, mixed hearing loss, vertigo, eustachian tube dysfunction, and middle ear effusion may be the initial manifestations of an extensive petrous apex lesion. The TEA has been effectively used in treating expansile benign petrous apex lesions like cholesteatoma, cholesterol granuloma, and primary mucocele.<sup>5</sup> Intraoperatively, closure of the skull base defect has to be done, among vascularised flaps, those raised locally in the nasal cavity from the nasal septum or nasal

turbinates on the supplying sphenopalatine artery (SPA) are the most common. Pedicled flaps raised on external head and neck vessels other than intranasal ones are applied in situations when the SPA is damaged due to a tumor or previous treatment (surgical procedure or radiotherapy). The following flaps can be used: tunneled temporoparietal fascia flap, endoscopic-assisted pericranial flap, palatal flap, occipital flap, facial artery buccinator flap, and others.<sup>7–10</sup>

As EEA uses the sino-nasal tract as the surgical corridor to the skull base, sino-nasal trauma is a primary source of postoperative morbidity in many patients. Though most sino-nasal morbidities are transient and resolve within several months, symptoms can persist for longer with more complex surgeries.<sup>6,11,12</sup> The complication which occurs due to endonasal surgery can be classified on the basis of the time duration after which they occur. Early complications are those which occur between 1 week to 6 months and they include mainly: CSF Leaks, epistaxis, subdural hematomas, and visual disturbances. Late complications are those which occur after 6 months and include: Chronic rhinosinusitis (CRS), meningitis, hypopituitarism, and olfactory dysfunctions. The localization and character of a pathology determine the place and size of a dural defect, partially the intensity of CSF leakage as well as the level of difficulty of the skull base reconstruction. The literature review has shown that pituitary adenomas are the most common lesions, due to which EEA operations are performed.<sup>13</sup>

In the present study, the overall complication rate was 28.6 percent of which the most common was residual disease left in 10 cases. (Figure 1) The other complications were anosmia that occurred in 4 cases of either sino-nasal malignancies or cerebral mucormycosis. We encountered no CSF leak in our series.

Borg A (2016) reviewed the complications during the past 65 years and concluded that the average overall worldwide complication rate was 17.1% ranging from 0% to 68%.<sup>14</sup> In the present study, the moderate complication rate was due to the presence of a significant number of cerebral mucormycosis and sino-nasal malignancies with intracranial extension. We encountered no CSF leak post-operatively while Borg A recorded 8.9% of CSF leaks as major complications. In our series, a better understanding of the repair of the skull base defect may be the reason for the absence of CSF leak as a complication of anterior skull base surgery. Taghvaei M et al. (2022) Al reported a mortality rate of 2.0%<sup>15</sup> while it was up to 10% in Borg A study. The mortalities rate in our series was 4.8 % those occurred one due to sino-nasal malignancies and two due to cerebral mucormycosis.

## 5. Conclusion

Skull base surgery is nowadays the most fascinating and exciting surgery worldwide. In India, very few centers can

achieve the goal as per their optimum wishes. In Bihar, a few surgeons are performing excellent skull base surgery. The results are encouraging and show that we can move ahead along with the others.

## 6. Source of Funding

None.

## 7. Conflict of Interest

None.

## Acknowledgments

We would like to thank Prof. Dr. Manish Mandal, Medical Superintendent for their support to conduct this study.


## References

1. Francies O, Makalanda L, Paraskevopolous D, Adams A. Imaging review of the anterior skull base. *Acta Radiol Open*. 2018;7(5):2058460118776487.
2. Kuriakose MA, Trivedi NP, Kekatpure V. Anterior skull base surgery. *Indian J Surg Oncol*. 2010;1(2):133–45.
3. Stephenson ED, Lee SE, Adams K, Farquhar DR, Farzal Z, Ebert CS, et al. Outcomes of Open vs Endoscopic Skull Base Surgery in Patients 70 Years or Older. *JAMA Otolaryngol Head Neck Surg*. 2018;144(10):923–8.
4. Wu T, Chandy Z, Ferece E. Endoscopic Skull Base Surgery in the Pediatric Population. *Curr Treat Options Allergy*. 2021;8(1):274–84.
5. Sandu K, Monnier K, Pasche P. Anatomical landmarks for transnasal endoscopic skull base surgery. *Eur Arch Otorhinolaryngol*. 2012;269(1):171–8.
6. Oyama K, Tahara S, Hirohata T, Ishii Y, Prevedello DM, Carrau RL, et al. Surgical Anatomy for the Endoscopic Endonasal Approach to the Ventrolateral Skull Base. *Neurol Med Chir*. 2017;15(10):534–41.
7. Wardas P, Tymowski M, Seweryn AP, Markowski J, Ładziński P. Hadad-Bassagasteguy flap in skull base reconstruction - current reconstructive techniques and evaluation of criteria used for qualification for harvesting the flap. *Wideochir Inne Tech Maloinwazyjne*. 2018;14(2):340–7.
8. Wang F, Zhou T, Wei S. Endoscopic endonasal transsphenoidal surgery of 1,166 pituitary adenomas. *Surg Endosc*. 2015;29(6):1270–80.
9. Cappabianca P, Cavallo LM, Colao A, De Caro DB, Esposito M, Cirillo F. Endoscopic endonasal transsphenoidal approach: outcome analysis of 100 consecutive procedures. *Minim Invasive Neurosurg*. 2002;45(4):193–200.
10. Gardner PA, Kassam AB, Thomas A, Snyderman CH, Carrau RL, Mintz AH, et al. Endoscopic endonasal resection of anterior cranial base meningiomas. *Neurosurg*. 2008;63(1):36–52.
11. Arai H, Sato K, Nakanishi H, Miyajima M, Hishii M. Transcranial transsphenoidal approach for tuberculoma sellae meningiomas. *Acta Neurochir*. 2000;142(7):751–6.
12. Kassam AB, Gardner P, Snyderman C, Mintz A, Carrau R. Expanded endonasal approach: fully endoscopic, completely transnasal approach to the middle third of the clivus, petrous bone, middle cranial fossa, and infratemporal fossa. *Neurosurg Focus*. 2005;15(1):6–6.
13. Solari D, Alessandro MD, Esposito F, Michelangelo MD, De Angelis M. Anatomy and surgery of the endoscopic endonasal approach to the skull base. *Transl Med UniSa*. 2012;2:36–46.
14. Borg A, Kirkman MA, Choi D. Endoscopic endonasal anterior skull base surgery: a systematic review of complications during the past 65 years. *World Neurosurg*. 2016;95:383–91.

15. Taghvaei M, Fallah S, Sadaghiani S, Sadrhosseini SM, Tabari A, Fathi M. Surgical complications of endoscopic approach to skull base: analysis of 584 consecutive patients. *Eur Arch Otorhinolaryngol.* 2022;279(6):3189–99.

**Jyoti Singh**, Junior Resident

**Shruti Jha**, Junior Resident

**Rakesh Kumar Singh**, Professor and Head  <https://orcid.org/0000-0002-8411-2194>

## Author biography

**Diksha Kumari**, Junior Resident

**Amit Kumar Sharma**, Assistant Professor

**Brajesh Kumar**, Assistant Professor  <https://orcid.org/0000-0002-1540-2454>

**Cite this article:** Kumari D, Sharma AK, Kumar B, Singh J, Jha S, Singh RK. An institutional analysis of the outcomes of endonasal endoscopic anterior skull base surgery. *IP Indian J Anat Surg Head, Neck Brain* 2022;8(3):84-88.