

Content available at: <https://www.ipinnovative.com/open-access-journals>

IP Indian Journal of Anatomy and Surgery of Head, Neck and Brain

Journal homepage: <https://www.ijashnb.org/>

## Case Report

# Agglomeration of extensor pollicis brevis slips: Tear or anatomical variation

Ankit Singh <sup>1,\*</sup><sup>1</sup>Dept. of Orthopaedics, Max Smart Hospital, New Delhi

### ARTICLE INFO

#### Article history:

Received 18-07-2022

Accepted 03-10-2022

Available online 21-10-2022

#### Keywords:

Abductor pollicis longus

Extensor pollicis brevis

Ultrasound

### ABSTRACT

First extensor tendon compartment is composed of Extensor pollicis brevis (EPB) and Abductor pollicis longus (APL) and lack of knowledge of anatomical variation in conventional textbooks regarding these tendons lead to misdiagnosis of underlying condition. In our case, similar sized tendon slips of EPB with synovial sheath thickening was reported in Ultrasound (USG) as intra-substance tear and thus the inaccurate surgical plan was decided delaying the treatment and patient's loss from work. Exploration of tendons lead to the findings of accessory slip of EPB and just pulley release of the same lead to faster restoration of daily activities without pain thus combating the surgical expense in resource deprived patient.

This is an Open Access (OA) journal, and articles are distributed under the terms of the [Creative Commons Attribution-NonCommercial-ShareAlike 4.0 License](https://creativecommons.org/licenses/by-nc-sa/4.0/), which allows others to remix, tweak, and build upon the work non-commercially, as long as appropriate credit is given and the new creations are licensed under the identical terms.

For reprints contact: [reprint@ipinnovative.com](mailto:reprint@ipinnovative.com)

## 1. Introduction

Extensor pollicis brevis (EPB) and Abductor pollicis longus (APL) forms the tendons of 1st dorsal compartment. Conventional literature designate the origin of EPB as the posterior aspect of the radius and the surrounding interosseous membrane, distal to the APL attachment and inserts into the base of the proximal phalanx of the thumb.<sup>1</sup> Its main function is to extend the MCP joint and have a minor role in thumb's adduction.<sup>2</sup>

EPB tendon anatomy showed variation opposed to the conventional studies and varies even between the two hands of the same person.<sup>3</sup> According to certain publications, the operator's lack of knowledge of anatomical variations in the location of EPB during the surgical intervention directly contributes to a significant share of clinical malpractice claims within the surgical specialties. Consequently, it is important to understand the variability of the EPB.<sup>4</sup>

### 1.1. Presentation

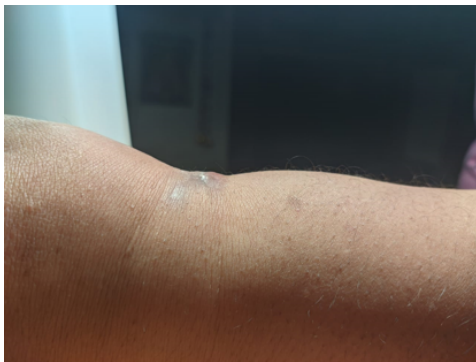A 36-year-old female labourer by occupation presented with a long history of pain over the radial aspect of left wrist partially relieved on taking pain relieving medications recurring with its stoppage and rest. All these problems began 9 months back and had continued and progressed in frequency and intensity. She visited several orthopedists and was finally diagnosed with stenosing tenosynovitis of first dorsal compartment of wrist. She underwent the treatment: rest, orthotic brace, NSAIDs for around 6 weeks and symptoms recurred. She was further advised ultrasound and MRI for the same which reported extensor pollicis brevis longitudinal tendon tear and the same was affirmed by several radiologists. She was recommended tendon repair for the same and the necessity of prolonged period of rest post repair for tendon healing. The surgical cost for the above mentioned surgery and subsequent immobilisation rendered her being skeptical for the treatment. Patient then presented to us with the same complaints and on physical examination, mild swelling was seen over wrist (Figure 1) and Finkelstein test was positive with painfully restricted thumb extension. Repeat ultrasounds were performed and

\* Corresponding author.

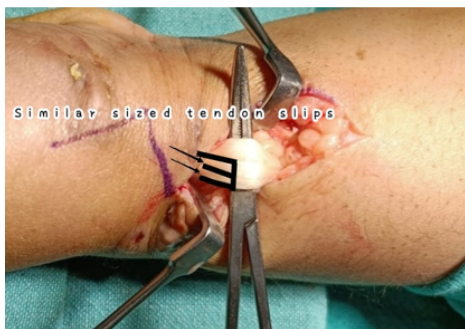E-mail address: [ankitrobin2915@gmail.com](mailto:ankitrobin2915@gmail.com) (A. Singh).

suggested intra-substance tendon tear (Figure 4) as earlier. Patient was posted for DC 1 pulley release and exploration of tear and subsequent repair.

On surgical exploration under (Wide awake local anaesthesia no tourniquet) WALANT, APL and EPB tendons were seen and DC 1 pulley release was performed. On careful examination, two similar sized slips of EPB (Figure 2) was found with the additional medial slip (Figure 3) surrounded by thickened synovial sheath which was then incised and tendon gliding seen freely on command. The longitudinal central furrow between two slips corresponded to what seemed tendon tear on latest USG.



**Fig. 1:** Swelling over the left wrist

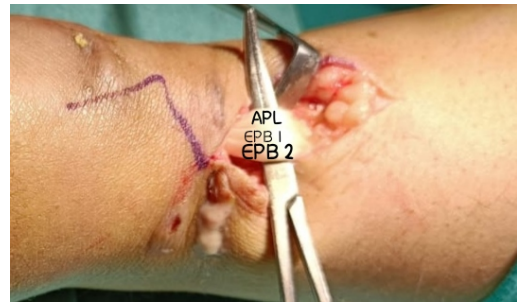

**Fig. 2:** Multiplicity of EPB tendon slips

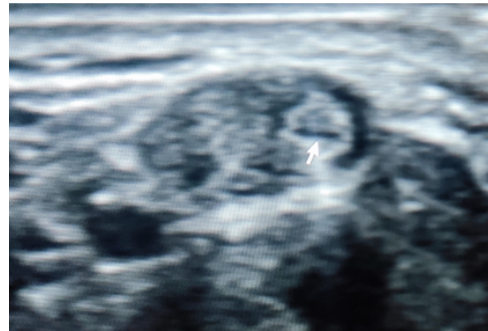
Patient was advised immediate range of motion exercises and returned back to her work. On subsequent follow ups, patient remained pain free.

## 2. Discussion

APL tendon have been shown to have multiple slips and often encountered as the cause of dequervain's tenosynovitis.<sup>5,6</sup> EPB on the other hand have been seldom shown in texts to have multiple slips until study by Lyall.<sup>7</sup> That significant variation exists in tendon and muscle belly



**Fig. 3:** Additional medial EPB slip (EPB 2)



**Fig. 4:** EPB split as seen on USG (indicated as white arrow)

of EPB. MRI usually helps not only in diagnosis but also prognosis of dequervain's tenosynovitis.<sup>8</sup> Ultrasound is usually the modality of choice in dequervain's in clinical practice<sup>9</sup> and in this case the presence of similar sized tendon slips of EPB and central furrow between them alongside oedema due to synovial thickening presented as longitudinal short segment tear in EPB tendon in repeated ultrasounds and MRI. The misdiagnosis of this accessory slip rendered the delay in diagnosis and patient's time away from profession. The accessory slip (medially to original tendon) was of similar size as that of main EPB and the interval between the two was reported as longitudinal tear of EPB and the surgical plan of tendon repair was decided. The surgical plan and post-op rehabilitation plan led to the patient visiting several surgeons and the readiness of the said surgery. Knowledge of multiple slips of EPB is essential to the accurate diagnosis and prevention of surgical malpractice claims.

## 3. Conclusion

In our case report, similar sized EPB tendon slips led to misdiagnosis of tendon tear and hence the delay in diagnosis and management plan. The thickened synovial sheath of accessory tendon should be released too to prevent recurrence. Furthermore EPB tendon anatomical variation should be kept in mind in addition to APL tendon variation.

#### 4. Source of Funding

None.


#### 5. Conflict of Interest

None.

#### References

1. Snell RS. Upper limb. In: Snell RS, editor. *Skeletal Radiol* . 2012;48(11):334–433.
2. Kulshreshtha R, Patel S, Arya AP, Hall S, Compson JP. Variations of the extensor pollicis brevis tendon and its insertion: a study of 44 cadaveric hands. *J Hand Surg Eur*. 2007;32(5):550–3.
3. Dawson S, Barton N. Anatomical variations of the extensor pollicis brevis. *J Hand Surg Br*. 1986;11(3):378–81.
4. Ogeng'o J. Clinical significance of anatomical variations. *Anat J Africa*. 2013;2(1):57–60.
5. Hazani R, Engineer N, Cooney D, Wilhelmi B. Anatomic landmarks for the first dorsal compartment. *Eplasty*. 2008;8:53.
6. Siddiq MAB. de Quervains's tenosynovitis with accessory abductor pollicis longus tendon and 'Wartenberg syndrome'-A Case report. *Curr Rheumatol Rev*. 2022;18.
7. Lyall S, Iwuagwu H, C F. The extensor pollicis brevis: a review of its anatomy and variations. *Eplasty*. 2013;13.
8. Goyal A, Srivastava DN, Ansari T. MRI in De Quervain Tenosynovitis: Is Making the Diagnosis Sufficient? *AJR Am J Roentgenol*. 2018;210(3):29469625–29469625.
9. McBain B, Rio E, Cook J, Grabinski R, Docking S. Diagnostic accuracy of imaging modalities in the detection of clinically diagnosed de Quervain's syndrome: a systematic review. *Skel Radiol*. 2019;48(11):1715–21.

#### Author biography

Ankit Singh, Fellow  <https://orcid.org/0000-0002-1972-095X>

**Cite this article:** Singh A. Agglomeration of extensor pollicis brevis slips: Tear or anatomical variation. *IP Indian J Anat Surg Head, Neck Brain* 2022;8(3):109-111.