

Intraoral Schwannoma (Neurilemmoma): A Case Report

Sanyog Pathak¹, Anand S. Tegginamani^{2,*}, Wanjari Ghate Sonalika³, Vanishree H.S⁴

¹Dept. of Oral and Maxillofacial Surgery, ³Dept. of Oral Pathology,
Hitkarni Dental College & Hospital, Jabalpur, MP

²Dept. of Oral Pathology, ⁴Dept. of Pediatric Dentistry, Faculty of Dentistry,
SEGI University Kota Damansara, Malaysia

***Corresponding Author**

E-mail: anandop2005@rediffmail.com

Abstract

Neurilemmoma also known as schwannoma is benign nerve sheath tumor rarely occurring in the oral cavity. Intraoral occurrence of schwannomas is rare with an incidence of about only 1%. The sites of occurrence are usually the tongue, palate, floor of mouth, buccal mucosa, and mandible in descending order of incidence. It presents as encapsulated, slow growing, solitary, smooth-surfaced, and usually asymptomatic.

Key words: Antoni type A, Benign tumor, Neurilemmoma, soft palate, Verocay bodies

Introduction

It was first described by Verocay in 1910. It is relatively an uncommon neural neoplasm with unknown etiology, schwannoma, also called neurilemmoma, neurinoma, and perineural fibroblastoma, is a solitary, benign, encapsulated, and slow growing tumor, arising from neural sheath's Schwann cells of the peripheral, cranial (except for the optic and olfactory), spinal, and autonomic nerves, the nomenclature of these cells is attributed to the famous German physiologist and cofounder of the cell theory, Theodor Schwann, Verocay first described them as neurinoma in 1908. The literature search revealed 16,906 reports containing the word schwannoma. However, 1117 articles have been published on this benign lesion in the "head and neck" region, and search containing the word "intraoral schwannoma" showed only 29 cases. Although these benign tumors may affect any site of the body, in the head and neck region, the incidence is around 25-48%. Intraoral occurrence of schwannomas is rare with an incidence of about only 1%. The sites of occurrence are usually the tongue, palate, floor of mouth, buccal mucosa, and mandible in descending order of incidence.^[1]

Case Report

21 year-old female reported with chief complaint of a painless, slow growing swelling on right side of her lower face, of two year's duration. The swelling was well circumscribed on palpation with slight mobility. It measured about 3X2 cm, with no erythematous surface change on extra oral and intraoral side. Intraorally it was in relation to right mental foramen region but no associated paresthesia or discharge was found [Fig. 1]. On palpation, the swelling was found to be firm. The lymph nodes were non palpable and the patient did not give any relevant medical history. OPG and intraoral periapical view revealed nothing abnormal [Fig. 2]. On the basis of above mentioned findings an excisional biopsy was planned for this benign appearing lesion. After proper anesthesia a vestibular incision was given from lower right lateral incisor till second molar region. During dissection lesion was found to be between nerve fibers of mental nerve with in a thin sheath of fascia. Excision of the tumor was carried in to separating it from the mental nerve which was holding it nicely [Fig. 3]. Later, the wound was closed watertight and sample was sent for histopathology. No post-operative paresthesia or numbness was found. Lesion revealed it to be a neurilemmoma. We are still following the case with no complications so far.

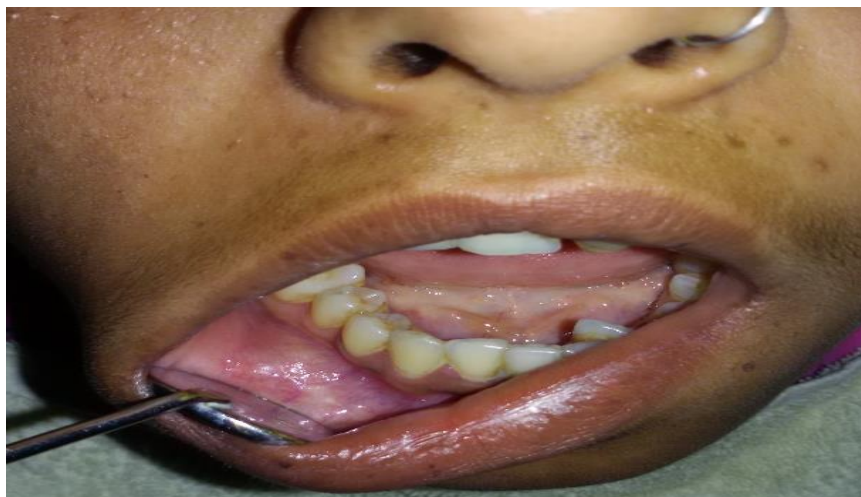

Fig. 1: Intraoral examination not associated with any discharge or change the texture of the overlying tissue

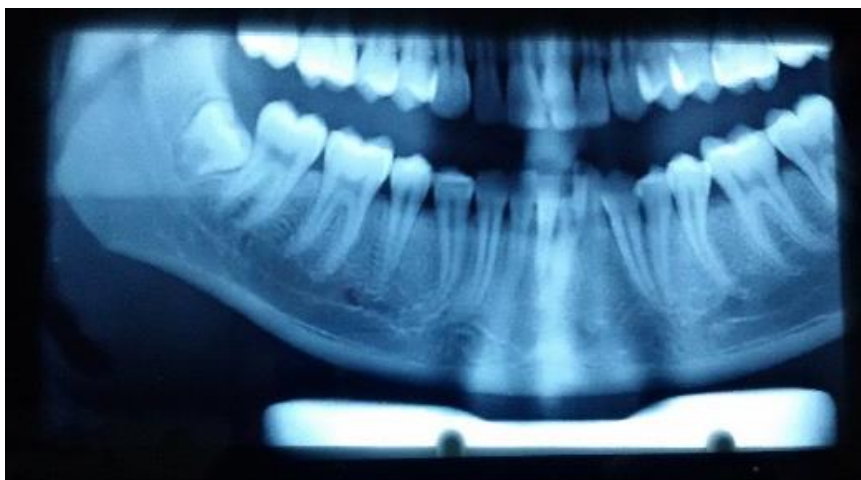

Fig. 2: No abnormality detected with OPG examination

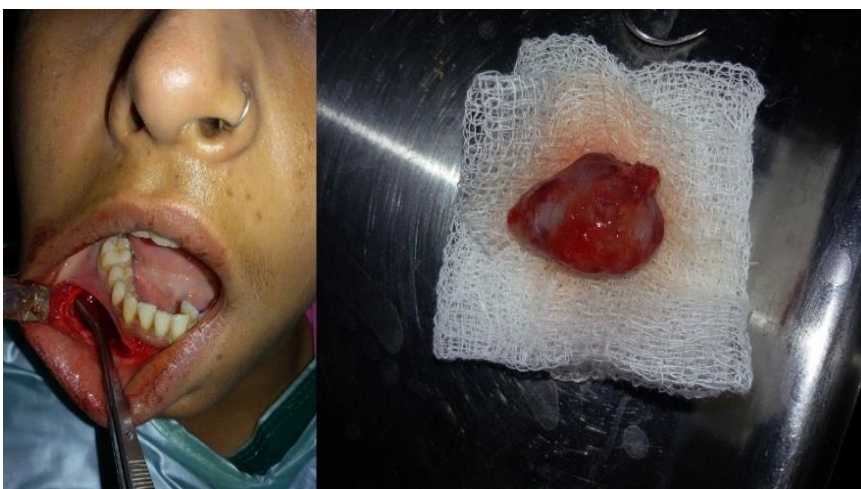

Fig. 3: Excision of the tumour was carried in to separating it from the mental nerve

Discussion

The exact cause of the extensive Schwann cell proliferation is unknown. Schwannomas are benign encapsulated nerve sheath neoplasm composed of Schwann cells. Wright and Jackson reported 146 cases of schwannoma of the oral cavity soft tissue. Of those, 52% occurred in the tongue, 19.86% in the buccal or vestibular mucosa, 8.9% in the soft palate, and the remainder 19.24% in the gingivae and lip. Embryologically, Schwann cells arise during the fourth week of development from a specialized population of ectomesenchymal cells derived from neural crest. These cells serve as thin barrier around each extracranial nerve fiber of motor and sensory nerves and wrap larger fibers with myelin sheath to enhance nerve conductance. Schwannomas commonly arise from spinal nerve roots and intracranial nerves of the face, neck, extremities, mediastinum, and pelvis. Most commonly affected nerve is the VIII cranial nerve.^[2]

This tumor may present itself at any age, but is more frequent between second and fourth decade of life, with no predilection for gender or race. The preoperative diagnosis is quite difficult because this is an infrequent tumor and is not usually suspected in the oral cavity. Histopathological evaluations is the key to diagnosis of this tumor as FNAC gives negative results on microscopy.^[3]

Pain and neurological symptoms are rare unless the tumor becomes large; hence, they are usually incidental findings. However, patient may complain of mild to moderate paraesthesia. Pain may occur when the lesion involves the adjacent nerves. Mandible is the most common bone affected followed by sacrum. These lesions are relatively rare in the maxilla. The inferior dental nerve is the most common nerve associated with intraosseous neurilemmoma owing to the size, location, length, and course.^[4] In the present case also it was asymptomatic, in the mandibular vestibule adjacent to the mental foramen, no evidence of pathology or changes were seen with the Orthopantomogram (OPG). [Fig. 2]

Mandible is the most common bone affected followed by sacrum. These lesions are relatively rare in the maxilla. The inferior dental nerve is the most common nerve associated with intraosseous neurilemmoma owing to the size, location, length, and course, the most typical presentation is that of an asymptomatic swelling of the posterior mandible.

The nonspecific radiographic appearance, consisting of a well-defined unilocular radiolucency, may suggest a benign odontogenic cyst or tumor, but widening of the mandibular canal observed in intramandibular schwannoma may prompt the addition of “a neoplasm of peripheral nervous system origin” to the differential diagnosis. Ultimately, a histopathologic examination is required for a definitive diagnosis.^[4]

In 1920, Nils Ragnar Eugene Antoni, a Swedish neurologist described two distinct patterns of cellular architecture in schwannoma. Antoni type A – hypercellular, shows increased number of spindle shaped cells with verocay bodies and bizarre looking nuclei and Antoni type B – hypocellular areas with spindle shaped cells, elongated nuclei, scanty cytoplasm, oedematous stroma with few dilated blood vessels.^[5] With present case the microscopic features were similar to those of their more common counterparts H& E stained section showed two basic patterns: hypercellular (Antoni A) and hypocellular (Antoni B) areas. In Antoni A areas of schwannoma cells that are compactly arranged form focally palisading structures (Verocay bodies) [Fig. 4].

The tumor is excised easily if encapsulated, whereas the non-encapsulated masses require normal tissue margin to avoid relapse. In our present case, the tumour was easily excised in to with ease probably because of the encapsulation. If the nerve origin is visualized, every attempt should be made to preserve the nerve function. The clinical differential diagnosis should include traumatic neuroma, neurofibroma, mucosal neuroma, hemangioma, fibroma, lipoma and salivary gland tumors.^[5]

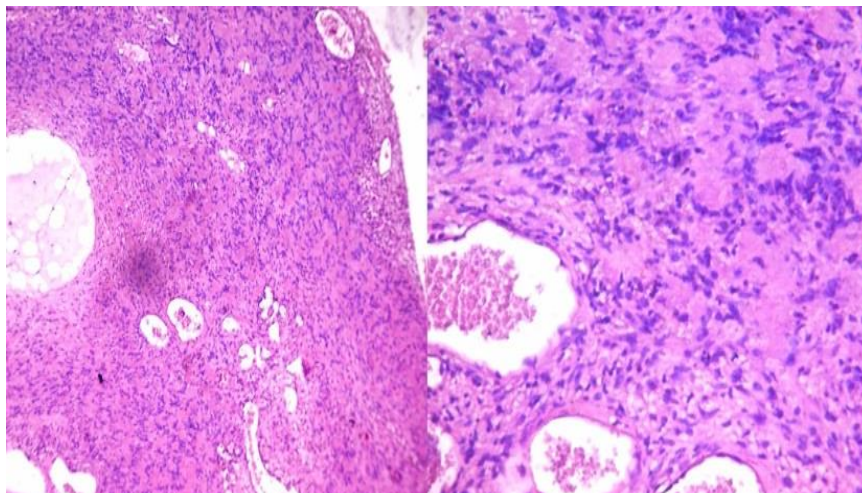


Fig. 4: H& E stained section showed two basic patterns: hypercellular (Antoni A) and hypocellular (Antoni B). In Antoni A areas of schwannoma cells that are compactly arranged form focally palisading structures (Verocay bodies)

Conclusion

A true intraoral neurilemmoma is difficult to diagnose in early stages due to absence of pain or symptoms, and even more difficult when no evidence of pathology or changes are seen with the radiographical examination, however, a biopsy is necessary to make the final diagnosis because of the non-specificity of the findings of the tumor. Neurilemmoma is a slow-growing benign lesion with minimal possibility of reported malignant transformation.^[4,6]

Conflict of Interest: None

Source of Support: Nil

References

1. Yaga US, Mengji AK, Besta R, Gollamudi N. Rare case of palatal schwannoma: Case report and review of literature. *J Indian Acad Oral Med Radiol* 2015;27:484-7.
2. Ajit Singh Rathore, Deepti Srivastava, Nidhi Narwal, and Devi Charan Shetty Neurilemmoma of Retromolar Region in the Oral Cavity Case Reports in Dentistry 2015 ID 320830, 4 pages.
3. Nibhoria S, Tiwana KK, Phutela R, Kaur J. Schwannoma of Tongue: A Rare Case Presentation with Review of Literature. *Int J Sci Stud* 2015;3(3):147-149.
4. Raakesh N, Sasikumar P, Manojkumar V, Govind GK. Progressively Enlarging Inferior Alveolar Nerve Canal Radiolucency - Schwannoma? A Rare Intraosseous Lesion. *IJSS Case Reports & Reviews* 2015;2(2):10-12.
5. Sivasankari.L and Selvam D.K., Schwannoma of soft palate. *International Journal of Recent Scientific Research* 2015; 6(7):5550-5552.
6. Minowa K, Sakakibara S, Yoshikawa K, Ohmori K, Kitagawa Y, Inoue N, Totsuka N, Nakamura M. CT and MRI findings of intraosseous schwannoma of the mandible: a case report *Dentomaxillofacial Radiology* 2007;36:113–116.