

Content available at: <https://www.ipinnovative.com/open-access-journals>

IP Indian Journal of Anatomy and Surgery of Head, Neck and Brain

Journal homepage: <https://www.ijashnb.org/>

Original Research Article

Analysis of anatomy of head and neck: A study through empirical part-I

V Rama Raju^{1,*}

¹CMR College of Engineering & Technology, Affili.: Jawaharlal Nehru Technological University JNTU, Hyderabad, Telangana, India



ARTICLE INFO

Article history:

Received 05-11-2022

Accepted 05-12-2022

Available online 20-02-2023

Keywords:

Cervicalspine

Cervicofascia

Anatomy

ABSTRACT

This study introduces new theory into the anatomical-structure, the head and neck, and followed by the neck. The harm or injury (damage) to the cervical benevolent ganglia might trigger “Horner-syndrome”, which is ipsi lateral ptosis, miosis, as well as “facial—anhidrosis”. Loss (damage, injury, destruction, etc.) to these anatomical-structures might cause to “first-bite-syndrome (FBS)”, with which the FB of nutrition/food is excruciating as a result in consequence of ‘autonomic-dysfunction’ attributable to traumatic-injuries within the (“deep parotid space DPS”) also exceptional cervix-ganglia (of the neck of the uterus). So, patient required to be anxious regarding variability of “phrenic-nerve” at any time. In case of C3,C4, and/or C5 adaxial/ventral branches (rami) are cracked, then that may hinder through the diaphragm properly functioning. sternocleidomastoid muscle The torticollis happens as sterno cleido mastoid (SCM) muscle condenses or contracts (muscle contractions) intermittently, triggering a changing of open-neck parallel (reverse) to a omolous muscle-cross or edge which will happen in biological provided the “SCM” is injured, and which can leads to “fibrosis” plus buttering of “muscle-fibers”. Which also happens because of improved “muscle-tone”, and/or dystonic-muscle-spasms or cramps, stemming as of emotive anxiety pressure tension-stress, and or unexpected actions (movements) or activities. However, while assessing the traumatic-injuries or damages, so it’s important to exclude/or prevent some carotid observing and separating within open-neck.

This is an Open Access (OA) journal, and articles are distributed under the terms of the [Creative Commons Attribution-NonCommercial-ShareAlike 4.0 License](https://creativecommons.org/licenses/by-nc-sa/4.0/), which allows others to remix, tweak, and build upon the work non-commercially, as long as appropriate credit is given and the new creations are licensed under the identical terms.

For reprints contact: reprint@ipinnovative.com

1. Introduction

Human shank, i.e., neckline or neck is the connection amongst the complete head as well as the remainder of the area-of-body(AoB). It is situated in the middle of the jawbone/mandible as well as “clavicle”, linking the crown immediately to the upper-body, trunk (torso), and also consists of several in deed many important anatomical-structures which consists approximately maximum multifaceted plus complex anatomical-structure within the torso plus it is also contained many organ-tissues, organ-components also structural-tissues through indispensable

edifice-structure plus purpose and functioning for standard and usual physiological-functioning. Anatomical-structures included surrounded by the open-head neck are in control and accountable for inhaling, talking, preaching, drinking, eating, the control of metabolic-digestion, provision sustenance, as well as linking of the human-brain also “cervical-spine”, cardiac-circulatory(cardiovascular respiratory) as well as “lymphatic-influx” and finally discharge/outflow as of the páté-cranium (the head).¹

2. Anatomical—Structure and Driving

The human-neck, the open-neck can be imagined especially just as a pathway (or a connecting-link) in the middle of the brain followed by remaining part of the complete-

* Corresponding author.

E-mail address: drvenkateshwararr@gmail.com (V. R. Raju).

body which is a house of the proksisml (situated nearer to the center of the body or the point of attachment, the proximal-end of flexor aspect-of-forearm.") throat gulletic-esophagus, wind-pipe-trachea, thyroid-secretory organ, as well as 'para thyroid-glands'. Which accommodates the channel-tubes designed for the flow-of-blood to the head-brain followed by the head-open-neck, strengthens the heads-brain and also drives it suitably, plus communicates human-nervous systems (HNS) and also central nervous systems (CNS) waveforms/signals as of the head-brain towards the whole remaining parts of the body. Therefore, the human-neck is a complicated segment of the whole torso-body in conjunction through the several indeed many distinct sections or planes as well as fragments.²⁻⁴ See the cross-sectional/neck depicted in the diagram.

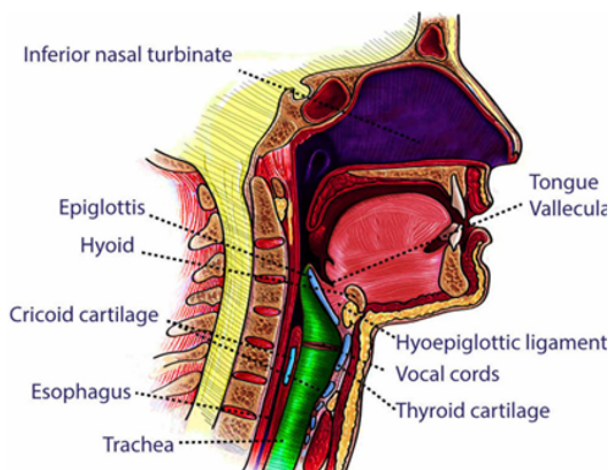


Fig. 1: The cross-sectional/neck depicted

Source: <https://www.ncbi.nlm.nih.gov/books/NBK557555/figure/article-78984.image.f2/?report=objectonly>

Our human neck differentiates hooked on two-fold binary threesomes (a three-way relationship-triangles), namely, frontal, rear (posterior), in conjunction with these separated obsessed by further threesomes plus anatomical-structural-areas and also its regions.^{4,5} The frontal threesome is encircled lowerly through the sternal-mark/or notch as well as clavicle, tangentially or horizontally(laterally) by the SCM, plus medial through throat(trachea), thyroid, followed by cricoid tendons(cartilages).² The latter, i.e., posterior threesome is surrounded posterior through the trapezius-muscle muscle, musculus-trapezius frontal through the SCM, as well as mediocre (lower) through clavicle.^{3,6}

The frontal threesome is segmented in to the 4 smaller sections (the threesome as well), namely, the sub mental, sub mandibular, carotid, followed by powerful-brawny (muscular) threesome trios.⁷⁻⁹

The 'deep cervical-fascia' sub divides in to the shallow layer of deep-cervical-fascia, the middle layer-of-deep

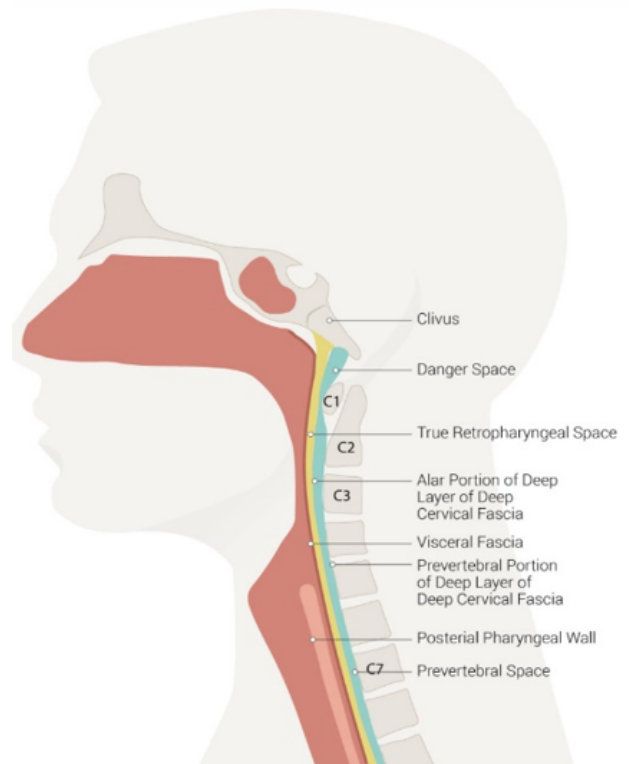


Fig. 2: 'Spaces-of-neck', 'danger-space', the 'clivus', the 'true-retro pharyngeal-space', 'alar-portion' of deep-layer of deep-cervical fascia, 'visceral-fascia', etc.⁴

Source: <https://www.mdpi.com/2227-9067/9/5/618>

cervical-fascia, followed by deep-layer of deep-cervic-fascia.¹⁰

1. The shallow layer-of-deep cervix-fascia, or devoting-layer, rests in the middle of the tone-muscles of the head-neck followed by shallow cervic-fascia, surrounding the SCM muscles also 'trapezi-muscles'. It connects inferior to 'scapula', 'clavic', as well as manu brium.^{10,11}

3. Embryology

Human lever grows, and progresses twenty one 21 days to a month' maturation as an expanding diverti culum of increasing 'endo dermal-cells' as of the "ventral-wall" of the fore gut in reaction to the waveforms/signals as of adjoining developing cardiac-muscle/heart. In the month last week, the two bud-blooms may be established within the "hepatatic diverti culum" – the cranial-bloom develops and turn into the liver plus hilar bilious(biliary)-tract, however the caudal-bloom(bud) builds and becomes in to the exceptional bud—bloom which shapes "gallbladder" and also "cystic—duct" as well as the "lesser-bud" which shapes in to adaxial(ventral) pancreas".¹²

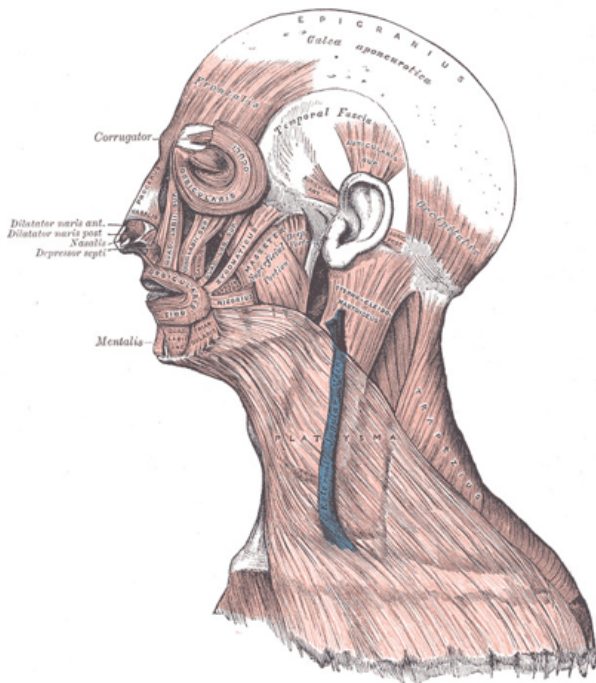


Fig. 3: Face-of-head, plus, muscles-of-neck.

Source: https://eyewiki.aao.org/Facial_Anatomy_-_Muscles

Primarily, the “liver-bud” is detached as of “mesenchyme” of “septum-transversum” by crypt cellular-membrane.¹ Soon, on the other hand, the cellular-membrane(tissue) is gone, and the “E-cadher-in” expression will be controlled put-down through in “hepatic liverwort-cells”, and thus these cells de cover and (lamine) protect as of the “bloom-bud” as well as attacks septum-trans-versum by way of “cords-of-hepato blasts—“bi potential’-cells” which distinguish in to the “hepato-cytes” followed by the “chol-angiocytes”. While they enter in to “septum-transversum-mesenchyme”, as well as “hepato-blasts” mingle through the “endo-thelial-cells”, the communication which seems crucial and also significant in support of “hepatic-hepatatic- “morpho-genesis”.¹³

The “hepatic-variation is extremely reliant (dependent-relative) over the waveforms-signals as of cardio genic “meso-derm” plus the “septum-trans versum-mesenchyme”, that generate the “fibro blast growth-factor referred to as FGF)” as well as jawbone morphological genetical proteins”, correspondingly. However, the prevention of hepato cytic diversity is so complicated therefore consist of many indeed numerous record-issues and records on different phases of periods of growth.¹⁴

Numerous significant neuro vascular as well as musculo skeletal forms within the neckline (embryo)nucleus plausibly originate as of the guttural cloisters, that are consequences over the horizontal sections of the crown of the “embryo”. Circa, ~6 (six) “pharyngeal—arches”, namely, they are, pharyngeal-arche#1, pharyngeal-arche#2,

pharyngeal-arche#3, pharyngeal-arche#4, pharyngeal-arche#5, and pharyngeal-arche#6. However, the fifth pharyngeal-arche#5 vanishes virtually i.e., almost practically and instantly following its formation.

Every indeed all the pharyngeal-arches becomes splitted through the ecto dermal pharynge hollows as well as the endo dermal pharynge-bags. All the arches indeed comprises the endo derms, meso derms, ecto derms, as well as neural/neuronal “growth-cells”.^{15,16}

1. Pharyngeal-arche#1 progresses in the frontal (anterior) abdomen (tummy-belly) of the “digastric-muscle(DM)”, “mylohyoid-muscle(MM)”, “mandible-muscle(MAM)”, followed by the “mylohyoid-limb section of tri-geminal-nerve”.
2. Pharyngeal-arche#2 develops into the cervical branch of the facial nerve, posterior belly of the digastric muscle, platysma muscle, stylohyoid muscle, and the lesser horn of the hyoid bone.
3. Pharyngeal-arche#3 progresses in to superior trumpet (horn) of the hyoid-bone/(hyoid-muscle), (stylo-pharyngeus muscle-SPM), glosso-pharyngeal-nerve(GPN), common-carotid-artery(CCA), followed by proximal-part of the inner (interior) “carotid-arteryCA”.¹⁷
4. Pharyngeal-arche#4 (pouch4) grows in to “thyroid-cartilageTC”, pharynge-constrictor- muscle (PCM), crico-thyroid-muscle(CTM), “levator-veli palatine-muscle(LPM), followed by exceptional laryngeal-muscle-nerve(SLM)¹⁸.
5. Pharyngeal-arche#6 progresses in to the cricoid-cartilage-muscle (CCM), “intrinsic- muscle(IM) of larynx-part, as well as chronic and persistent “larynge-muscle-nerve(LMN)”.¹⁹
6. Pharyngeal-pouch#3 develops into the inferior parathyroids, while pharyngeal-pouch4 develops into the superior parathyroids and the ultimobranchial body. The ultimo-branchial body eventually becomes the parafollicular cells of the thyroid^{20–22}

The pharynge-arches, bulges, as well as trenches – the channels expand in to the more additional anatomical—structures within the complete human-head also however, which are far and beyond.

4. Conclusions

The study in this diagnostic-clinical research work introduced a new theory into the anatomical-structure, the head and neck, and followed by the neck. The harm or injury (damage) to the cervical benevolent ganglia might trigger “Horner-syndrome”, which is ipsi lateral ptosis, miosis, as well as “facial—anhidrosis”. Loss (damage, injury, destruction, etc.) to these anatomical-structures might cause to “first-bite-syndrome (FBS)”, with which the FB of nutrition/food is excruciating as a result in

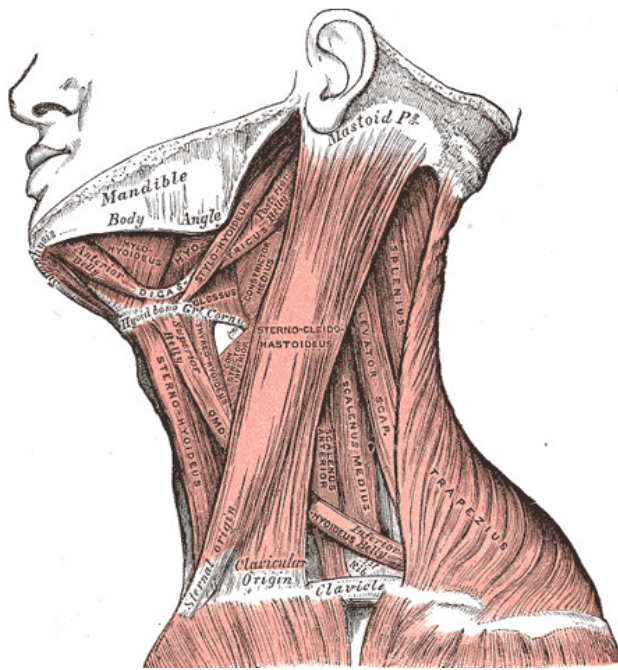


Fig. 4: Various-muscle of neck.

Source: <https://emedicine.medscape.com/article/1520111-overview>

consequence of ‘autonomic-dysfunction’ attributable to traumatic-injuries within the (“deep parotid space DPS”) also exceptional cervix-ganglia (of the neck of the uterus). So, patient required to be anxious regarding variability of “phrenic-nerve” at any time. In case of C3,C4, and/or C5 adaxial/ventral branches (rami) are cracked, then that may hinder through the diaphragm properly functioning. sternocleidomastoid muscle The torticollis happens as sternocleidomastoid (SCM) muscle condenses or contracts (muscle contractions) intermittently, triggering a changing of open-neck parallel (reverse) to a omolous muscle-cross or edge which will happen in biological provided the “SCM” is injured, and which can leads to “fibrosis” plus buttering of “muscle-fibers”. Which also happens because of improved “muscle-tone”, and/or dystonic-muscle-spasms or cramps, stemming as of emotive anxiety pressure tension-stress, and or unexpected actions (movements) or activities. However, while assessing the traumatic-injuries or damages, so it’s important to exclude/or prevent some carotid observing and separating within open-neck.

5. Source of Funding

None.

6. Conflict of Interest

None.

References

- Roesch KZ, Tadi P. Anatomy, Head and Neck, Neck. Treasure Island (FL): StatPearls Publishing; 2022. Available from: <https://www.ncbi.nlm.nih.gov/books/NBK542313/>.
- Kohan EJ, Wirth WA. Anatomy of the neck. *Clin Plastic Surg.* 2014;41(1):1–6.
- Shadfar S, Perkins SW. Anatomy and physiology of the aging neck. *Facial Plast Surg Clin North Am.* 2014;22(2):161–70. doi:10.1016/j.fsc.2014.01.009.
- Frisdal A, Trainor PA. Development and evolution of the pharyngeal apparatus. *Wiley Interdiscip Rev Dev Biol.* 2014;3(6):403–18. doi:10.1002/wdev.147.
- Garner DH, Kortz M, Baker S. Anatomy, Head and Neck, Carotid Sheath. vol. 2. StatPearls Publishing; Treasure Island (FL); 2022. p. 12–22.
- Ihnatsenka B, Boezaart AP. Applied sonoanatomy of the posterior triangle of the neck. *Int J Shoulder Surg.* 2010;4(3):63–74. doi:10.4103/0973-6042.76963.
- Ha EJ, Baek JH, Lee JH, Kim JK, Shong YK. Clinical significance of vagus nerve variation in radiofrequency ablation of thyroid nodules. *Eur Radiol.* 2011;21(10):2151–7.
- Masuoka H, Miyauchi A, Yabuta T, Fukushima M, Miya A. Innervation of the cricothyroid muscle by the recurrent laryngeal nerve. *Head Neck.* 2016;38(1):441–5.
- Lee JH, Cheng KL, Choi YJ, Baek JH. High-resolution Imaging of Neural Anatomy and Pathology of the Neck. *Korean J Radiol.* 2017;18(1):180–93.
- Guidera AK, Stringer MD, Dawes PJD, Fong A. Head and neck fascia and compartments: no space for spaces. *Head Neck.* 2014;36(7):1058–68. doi:10.1002/hed.23442.
- Hwang K. Anatomy of the Platysma Muscle. *J Craniofac Surg.* 2017;28(2):539–42. doi:10.1097/SCS.00000000000003318.
- Bordoni B, Varacallo M. Anatomy, Head and Neck, Sternocleidomastoid Muscle. vol. 1. StatPearls [Internet]. Treasure Island (FL): StatPearls Publishing; 2022.
- Ourieff J, Scheckel B, Agarwal A. Anatomy, Back, Trapezius. vol. 3. StatPearls Publishing; Treasure Island (FL); 2022. p. 31–41.
- Tan BK. Anatomic variations in head and neck reconstruction. *Semin Plast Surg.* 2010;24(2):155–70.
- Warshafsky D, Goldenberg D, Kanekar SG. Imaging anatomy of deep neck spaces. *Otolaryngol Clin North Am.* 2012;45(6):1203–21.
- Falyar CR, Shaffer K, Perera RA. Localization of the brachial plexus: Sonography versus anatomic landmarks. *J Clin Ultrasound.* 2016;44(7):411–5. doi:10.1002/jcu.22354.
- Cappiello J, Piazza C, Nicolai P. The spinal accessory nerve in head and neck surgery. *Curr Opin Otolaryngol Head Neck Surg.* 2007;15(2):107–11. doi:10.1097/MOO.0b013e3280523ac5.
- Kim DH, Cho YJ, Tiel RL, Kline DG. Surgical outcomes of 111 spinal accessory nerve injuries. *Neurosurgery.* 2003;53(5):1102–12. doi:10.1227/01.neu.0000089058.82201.3d.
- Allen E, Minutello K, Murcek BW. Anatomy, Head and Neck, Larynx Recurrent Laryngeal Nerve. vol. 2. StatPearls Publishing; Treasure Island (FL); 2022. p. 25–35.
- Chiba M, Hirokami H, Takahashi T. Clinical Features of Idiopathic Parotid Pain Triggered by the First Bite in Japanese Patients with Type 2 Diabetes: A Case Study of Nine Patients. *Pain Res Treat.* 2018;p. 7861451. doi:10.1155/2018/7861451.
- Cunha B, Tadi P, Bragg BN. Torticollis. vol. 12. StatPearls Publication, Treasure Island (FL); 2022. p. 129–9.
- Richard M. Embryology, Anatomy, Histology, and Developmental Anomalies of the Liver. vol. 71. Sleisenger and Fordtran’s Gastrointestinal and Liver Disease; 2010. p. 2022. Available from: https://www.researchgate.net/publication/289249020_Embryology_Anatomy_Histology_and_Developmental_Anomalies_of_the_Liver. doi:10.1016/B978-1-4160-6189-2.00071-8.

Author biography**V Rama Raju**, Professor

Cite this article: Raju VR. Analysis of anatomy of head and neck: A study through empirical part-I. *IP Indian J Anat Surg Head, Neck Brain* 2022;8(4):124-128.