



## Original Research Article

# Effects of oral prednisolone and fluticasone nasal spray in the management of chronic rhinosinusitis with polyposis: A prospective observational study

Sriharsha Vijay Jonnalagadda<sup>1,\*</sup>, Ashwin Ashok Jaiswal<sup>1</sup>, Neeta Sharma<sup>1</sup>, Prachi Mene<sup>1</sup>

<sup>1</sup>Dept. of ENT & Head Neck Surgery, J.L.N. Hospital and Research Centre, Bhilai, Chhattisgarh, India



## ARTICLE INFO

## Article history:

Received 25-02-2023

Accepted 25-03-2023

Available online 20-05-2023

## Keywords:

Chronic rhinosinusitis

Combined therapy

Fluticasone propionate nasal spray

Oral prednisolone

Nasal Polyps

## ABSTRACT

**Aim:** To study the effects of combination therapy with oral prednisolone and topical fluticasone propionate nasal spray in patients with Chronic Rhinosinusitis with Nasal Polyposis (CRSwNP). To study the improvement in symptom scores, Endoscopic and CT scores before and after treatment with combination therapy.

**Materials and Methods:** This prospective observational study was conducted on 50 patients attending the Outpatient Department of Otorhinolaryngology, J.L.N Hospital and Research Centre, Bhilai (Chhattisgarh), India over a period of 6 months from February 2020 to July 2020. Patients with symptoms of CRSwNP persisting for more than 12 weeks were thoroughly examined clinically along with Nasal endoscopy and Computed Tomography scan of Nose and Paranasal sinuses (CT PNS) and pre-treatment Visual Analog Scale (VAS), Lund & Mackay Scores for Endoscopic and CT findings were noted. Patients were treated with combination therapy of oral prednisolone and fluticasone propionate nasal spray and post treatment scores were noted using similar scales during the follow up visits and the results were statistically analysed.

**Results:** Total mean age of patients suffering from CRSwNP in our study was  $47.3 \pm 12.58$ . Males were affected more by CRSwNP than females (76% vs 24%). At the end of 3 months from baseline 48 patients (96%) showed a reduction in nasal discharge, 47 patients (94%) showed a reduction in nasal obstruction, 25 patients (50%) showed improvement in facial pain and 17 patients (34%) showed improvement in hyposmia. Overall post treatment Visual Analog Symptom (VAS) score improved in 42 patients (84%), Nasal endoscopy (Lund - Mackay scoring) improved in 43 patients (86%) and Radiological CT PNS & Nose (Lund - Mackay Scoring) improved in 33 patients (66%).

**Conclusion:** We found that combined therapy with oral prednisolone and fluticasone propionate nasal spray for 3 weeks is very effective in reducing the symptoms of chronic rhinosinusitis along with decrease in nasal secretions, edema and polyp size.

This is an Open Access (OA) journal, and articles are distributed under the terms of the [Creative Commons Attribution-NonCommercial-ShareAlike 4.0 License](https://creativecommons.org/licenses/by-nc-sa/4.0/), which allows others to remix, tweak, and build upon the work non-commercially, as long as appropriate credit is given and the new creations are licensed under the identical terms.

For reprints contact: [reprint@ipinnovative.com](mailto:reprint@ipinnovative.com)

## 1. Introduction

Chronic Rhinosinusitis (CRS) is one of the most common chronic disorders in the developed world causing significant morbidity, stress and impaired performance at school and workplace. CRS has been divided into two subtypes based on the presence of nasal polyps: CRS with nasal polyps

(CRSwNP) and CRS without nasal polyps (CRSsNP). Diagnosis of CRSwNP requires both subjective and objective evidence of chronic inflammation of sinuses with symptoms of nasal obstruction, nasal discharge, facial pain, hyposmia for greater than 12 weeks and evidence of polypoidal changes on Nasal Endoscopy and mucosal thickening on CT scan of nose and paranasal sinuses (CT PNS).<sup>1</sup>

\* Corresponding author.

E-mail address: [dr.jsriharsha@gmail.com](mailto:dr.jsriharsha@gmail.com) (S. V. Jonnalagadda).

Nasal endoscopy is convenient and easily available objective apparatus in the evaluation of patients with symptoms of CRS. The anatomic variations, mucosal changes in middle meatus and osteomeatal complex (OMC), purulence, polyps visualized on endoscopic assessment has a solid positive relationship with CRS.<sup>2</sup> In patients with constrained visualization on endoscopy due to polyps, deviated nasal septum, blockage of OMC and hidden air spaces like posterior ethmoids, ethmoid bulla and sphenoid sinus, CT PNS acts as a gold standard in discerning the disease.<sup>3</sup>

In spite of high prevalence rate and morbidity related with CRSwNP, there are no proper evidence-based guidelines for medical professionals to initiate and maintain the therapy. CRSwNP has an increased symptomatic burden and a high rate of relapse after treatment.<sup>4</sup> Monotherapy with intranasal corticosteroids can help in reducing the symptoms in the long run and have the benefit of decreasing the systemic side effects due to limited local action, but can cause regular relapses because of the inability to actively penetrate the OMC and restore physiologic drainage of sinuses.<sup>5</sup> Though surgical procedure relieves the blockage of OMC temporarily, it is not completely curative and serves fundamentally to improve the penetration of topical steroid treatment. "Medical polypectomy" refers to usage of a short course of oral steroids, which can improve the long-term viability and efficacy of topical treatment.<sup>6</sup>

The main hypothesis of this study is that combination therapy with oral prednisolone and fluticasone propionate nasal spray is effective not only in reducing the size of polyp but also helps in improvement of nasal symptoms without sustained adverse effects.

## 2. Materials and Methods

### 2.1. Study design

Prospective Observational Study

### 2.2. Study period

1<sup>st</sup> February 2020 to July 30<sup>th</sup> (6 months)

### 2.3. Sampling design

Patients attending the Outpatient Department of Otorhinolaryngology, J.L.N Hospital and Research Centre, Bhilai (Chhattisgarh), India.

### 2.4. Estimated sample size

Calculated from previous study - Rino K, Chettri MN, Moirentem NS, Zoramthari R, Thongam KD, Singh MM. Effects of oral prednisolone and fluticasone nasal spray in the management of nasal polypi. J Med Soc. 2016;30(3):135-140<sup>7</sup>

P= Incidence of reduction in nasal obstruction score after treatment = 98.5%

Taking P=0.985 and 1.96= z value for 5% confidence level  
e= Allowable error =5%

Cochran formula for observational study

$$\text{Minimum Sample Size} = N =$$

$$\frac{1:962\_p\_ (1-p)}{e^2} =$$

$$(3 : 8416\_0 : 985\_0 : 015) = (0 : 05)2 = 23$$

Minimum sample size = 23.

To increase the reliability and power of the study we increased the sample size to 50.

### 2.5. Inclusion criteria

Patients >18 years willing to take part and give written informed consent. Patients with complains of nasal discharge, nasal obstruction, facial pain and decreased sense of smell for more than 12 weeks. Patients with presence of bilateral moderate to large nasal polyps on nasal endoscopy.

### 2.6. Exclusion criteria

Patients not giving consent for our study. Patients who have received medical treatment in last 4 months. Patients who have undergone surgery in last 6 months. Patients with contraindications and hypersensitivity to steroids. Female patients who are pregnant, lactating or planning to become pregnant. Patients with co-morbidities like Hypertension, Diabetes mellitus, Asthma, Tuberculosis, Epilepsy.

### 2.7. Methodology

Ethical clearance to conduct the research has been sought and obtained from The Institute Ethics Committee, All India Institute of Medical Sciences (AIIMS), Raipur (Chhattisgarh) as per national ethical guidelines with the proposal number (AIIMSRPR/IEC/JLNH- 41/2020/418). A detailed history was taken from patients attending the Outpatient Department of Otorhinolaryngology, J.L.N Hospital and Research Centre, Bhilai. Patients with symptoms of CRS persisting for more than 12 weeks were thoroughly examined clinically along with Nasal endoscopy and CT-PNS. Nasal Endoscopy was done using Striker 1188 HD Camera with 0° Karl Storz Hopkins II Rigid Endoscope, Wolf Scope & Striker X 8000 light source and Striker Vision Pro LED display under topical anesthesia using 4% Xylocaine. CT- PNS coronal sections with 3mm slice thickness was done using 128 slices CT Scanner – Sceneria by Hitachi Medical Systems.

Individual pre-treatment scores were noted in terms of symptoms using Visual Analog Scale (VAS) and by using Lund & Mackay Scoring system for Endoscopic and CT findings. All the confirmed cases were treated with oral

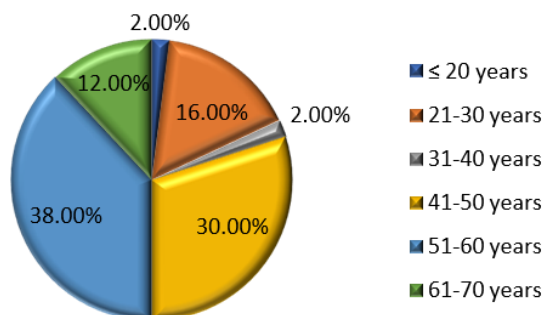
prednisolone 1mg/kg in divided and tapering doses along with fluticasone propionate nasal spray 200mcg 2 sprays twice daily for 3 weeks and post-treatment scores were noted using similar scales during the follow up visits at 3 weeks, 2 months and 3 months from baseline. The present study included results from pre and post treatment (VAS) Symptom scoring, Lund & Mackay Endoscopic scoring and CT scan scoring starting at baseline and at the end of 3 months.

### 2.8. Statistical analysis

Continuous data was summarized as Mean  $\pm$  SD (standard deviation) with Wilcoxon signed rank test while discrete (categorical) data in number and percentage. Data recorded using Statistics software SPSS 16.0 and randomization by computer generated random numbers. Statistical significance included  $P < 0.05$  as significant and  $P < 0.01$  as highly significant.

### 3. Observation and Results

The highest incidence of the disease was observed in the age group 51-60 years (38%). The youngest patient was 20 years old and the oldest patient was 67 years [Graph 1]. Out of 50 patients 38 patients were males and 12 patients were females with male to female ratio of 3.1: 1.



Graph 1: Age distribution

### 3.1. Nasal symptoms

Nasal obstruction (100%) and nasal discharge (100%) followed by facial pain (54%) and hyposmia (40%) were the most common symptoms. Other minor symptoms were headache in (46%) patients followed by fatigue in (4%) patients and earache in (2%) patients. None of the patients had fever, halitosis, dental pain or cough.

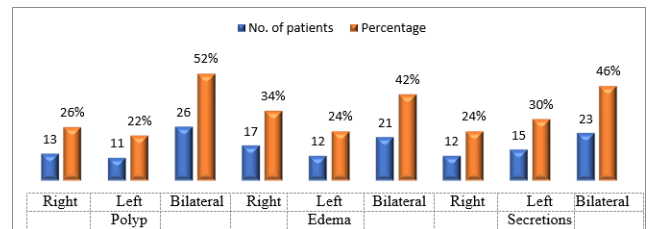
There was a statistically significant improvement in nasal obstruction, nasal discharge, hyposmia and facial pain from baseline before treatment and at the end of 3 months after treatment with  $p < 0.001$  and Z score  $- 3.60$  as observed in

Table 1.

Post treatment 47 patients (94%) showed improvement in nasal obstruction while 3 patients (6%) showed no improvement. 48 patients (96%) showed improvement in nasal discharge while 2 patients (4%) showed no improvement. Facial pain was reduced in 25 patients (50%) while 2 patients (4%) showed no improvement. 17 patients (34%) showed improvement in hyposmia while 3 patients (6%) showed no improvement. Post treatment improvement in minor symptoms was seen in 21 patients (42%) with headache followed by 1 patient (2%) with fatigue and 1 patient (2%) with earache. There was no improvement in 2 patients (4%) with headache, 1 patient (2%) with fatigue and 1 patient (2%) with earache.

### 3.2. Nasal endoscopy

Pre-treatment on nasal endoscopy 26 patients (52%) had bilateral polyps, 13 patients (26%) had right sided polyps and 11 patients (22%) had left sided polyps. 21 patients (42%) had bilateral edema, 17 patients (34%) had right sided edema and 12 patients (24%) had left sided edema. 23 patients (46%) had bilateral secretions, 12 patients (24%) had right sided secretions and 15 patients (30%) had left sided secretions [Graph 2].



Graph 2: Distribution of polyp, edema and secretions on nasal endoscopy

Post treatment Nasal endoscopy (Lund - Mackay scoring) is statistically significant with improvement on the right side in 36 patients (72%) with mean  $1.95 \pm 0.94$  and Z- score  $-5.33$ ;  $p < 0.001$  and on left side in 33 patients (66%) with mean  $1.81 \pm 0.84$  and Z-score  $-5.06$ ;  $p < 0.001$  as seen in Table 2.

### 3.3. CT-PNS & NOSE

Pre-treatment bilateral maxillary sinuses (64%) were involved the most followed by bilateral anterior ethmoids (58%), bilateral posterior ethmoids (40%), bilateral frontal sinuses (24%) and bilateral sphenoid sinuses (8%). Bilateral osteo-meatal complex blockage was (30%) [Graph 3].

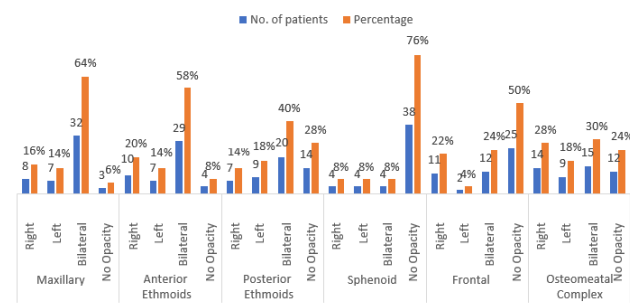
On the right side, frontal sinuses (22%) were involved the highest followed by, anterior ethmoids (20%), maxillary sinus (16%), posterior ethmoids (14%) and sphenoid sinus (8%). Right osteo-meatal complex blockage was (28%)

**Table 1:** Pre-treatment & post-treatment difference between nasal symptom score ranks with wilcoxon signed ranks test

Symptom	Symptom before and after treatment	N	Mean rank	Sum of ranks	Wilcoxon signed ranks		
					Z	Asymptotic significant (2-tailed)	P
Nasal obstruction	Negative ranks	47a	20.5	820	-5.57	0.0001	<0.001
	Positive ranks	0b	0.00	0.00			
	Ties	3c					
Nasal discharge	Negative ranks	48a	16.5	528	-5.00	0.0001	<0.001
	Positive ranks	0b	0.00	0.00			
	Ties	2c					
Facial Pain	Negative ranks	25a	13.0	325	-4.42	0.0001	<0.001
	Positive ranks	0b	0.00	0.00			
	Ties	2c					
Hyposmia	Negative ranks	17a	9.0	153	-3.60	0.0001	<0.001
	Positive ranks	0b	0.00	0.00			
	Ties	3c					

**Table 2:** Pre-treatment and post-treatment mean, standard deviation and Wilcoxon signed ranks test for lund-mackay nasal endoscopic scoring

Endoscopy	Mean		Symptom before and after treatment	N	Mean rank	Sum of ranks	Wilcoxon signed ranks				
	Pre	Post					SD Pre	SD Post	Z	Asymptotic significant (2-tailed)	P
RT	3.92	1.95	1.03-0.94	Negative ranks	36 <sup>a</sup>	18.5	666	-	5.33	0.0001	<0.001
				Positive ranks	0b	0.00	0.00				
				Ties	3c						
LT	3.92	1.81	1.16-0.84	Negative ranks	33 <sup>a</sup>	17.0	561	-	5.06	0.0001	<0.001
				Positive ranks	0 <sup>b</sup>						
				Ties	4 <sup>c</sup>						



**Graph 3:** Distribution of opacities of sinuses on CT PNS and nose

On the left side, posterior ethmoids (18%) were involved the highest followed by maxillary sinus (14%) and anterior ethmoids (14%) which had equal involvement, sphenoid sinus (8%) and frontal sinus (4%). Left osteo-meatal complex blockage was (18%)

Opacities were absent in sphenoid sinus in 38 patients (76%) which was the highest followed by frontal sinus in 25 patients (50%), posterior ethmoids (28%), anterior ethmoids (8%) and maxillary sinuses (6%). In osteo-meatal complex opacities were absent in (24%).

Post treatment Radiological CT PNS & Nose (Lund - Mackay scoring) is statistically significant with improvement on the right side in 32 patients (64%) with mean  $3.97 \pm 2.05$  and Z- score  $-5.00$ ;  $p < 0.001$  and on left side in 33 patients (66%) with mean  $3.72 \pm 1.85$  and Z-score  $-5.07$ ;  $p < 0.001$  as seen in Table 3.

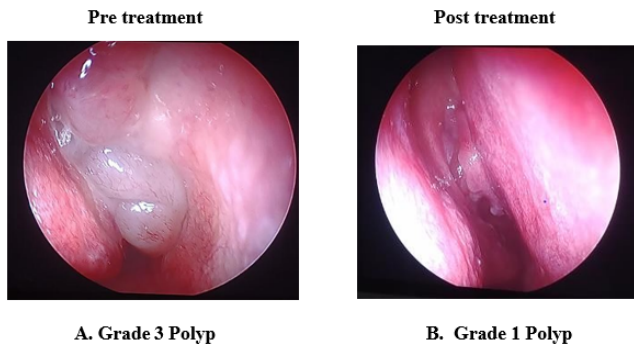
Overall post treatment Visual Analog Symptom (VAS) score improved in 42 patients (84%), Nasal endoscopy (Lund - Mackay scoring) improved in 43 patients (86%) and Radiological CT PNS & Nose (Lund - Mackay Scoring) improved in 33 patients (66%) as seen in Graph 4.

#### 4. Discussion

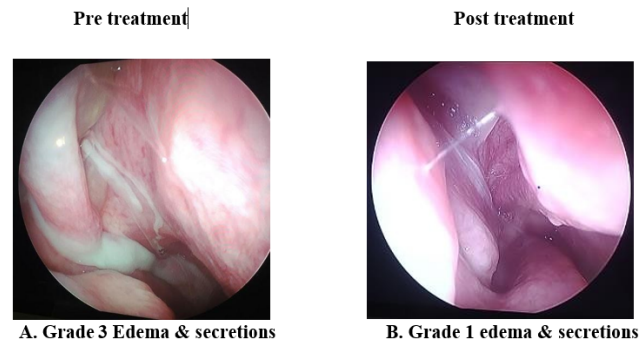
Chronic Rhinosinusitis with nasal polyposis is one of the common disorders which is responsible for frequent hospital visits. It is diagnosed and treated by various medical specialities including otorhinolaryngology, internal medicine and allergy resulting in high- practice variability. Early diagnosis and timely intervention are important to reduce morbidity and burden of the disease. There are many studies which have studied the etiology, surgical management, sensitivity/specificity of endoscopy and CT scan for diagnosis or symptomatology alone but there

**Table 3:** Pre-treatment and post-treatment mean, standard deviation and wilcoxon signed ranks test for lund – mackay ct paranasal sinus and nose scoring

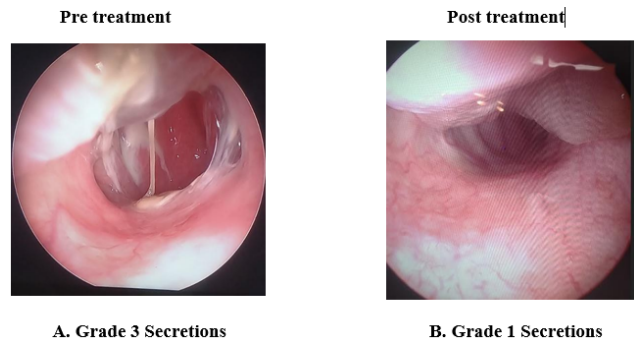
CT PNS& NOSE	Mean	SD	Symptom before and after treatment	N	Mean rank	Sum of ranks	Wilcoxon signed ranks		
	Pre-Post	Pre- Post					Z	Asymptotic significant P	
RT	5.56- 3.97	2.54- 2.05	Negative ranks	32a	16.5	528	-	0.0001	<0.001 (2-tailed)
			Positive ranks	0b	0.00	0.00	5.00		
			Ties	11c					
LT	5.25- 3.72	2.46- 1.85	Negative ranks	33a	17.0	561	-	0.0001	<0.001
			Positive ranks	0b	0.00	0.00	5.07		
			Ties	10c					



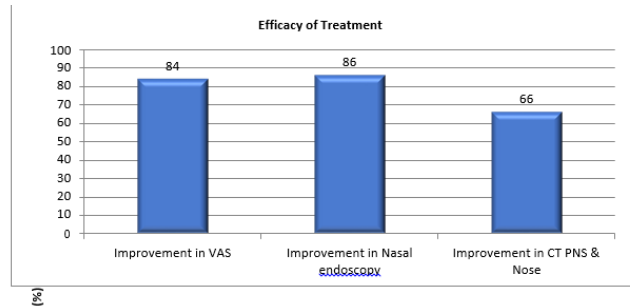
**Fig. 1:** A & 1B: Lund& mackay nasal polyp endoscopy scoring



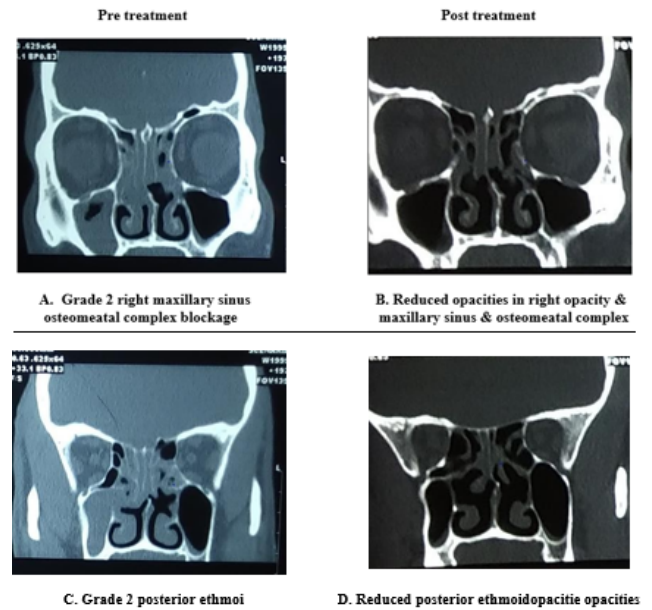
**Fig. 2:** A & 2B: Lund & mackay nasal edema endoscopy scoring



**Fig. 3:** A & 3B: lund & mackay nasal secretions endoscopy scoring



**Graph 4:** Efficacy of treatment in the overall improvement of visual analog symptom score, lund – mackay nasal endoscopy score and lund – mackay computed tomography score



**Fig. 4:** A, B, C & D: Lund and mackay scoring of CT paranasal sinuses and nose

are no sufficient prospective studies on Indian population correlating the effects of combination therapy with oral Prednisolone and topical Fluticasone nasal spray in patients with CRSwNP.

Different age groups are affected by Chronic Rhinosinusitis. In our study the mean age of patients was 47.3 years (range: 20 - 67 years) with 38 male patients and 12 female patients which is similar to a study done by Wabnitz et al<sup>7</sup> where the mean age of patients was 44.5 years. In a study done by Ling FT and Kountakis,<sup>8</sup> 49.4 years was the mean age of patients with male to female ratio of 1.1: 1. In a study done by Nayak et al<sup>9</sup> the highest incidence and majority of the patients (n= 46, 78%) were in 3<sup>rd</sup> decade which is in contrast to our study where the highest incidence of disease and majority of patients (n=19, 38%) were in 5<sup>th</sup> decade.

In our study the most common symptoms were nasal discharge (n=50,100%), nasal obstruction (n=50,100%), facial pain (n=27,54%) headache (n=23,46%) hyposmia/anosmia (n=20,40%), fatigue (n=2,4%) and earache(n=1,2%) which is similar to a study done by Lilly-Tariah<sup>10</sup> where the most common symptoms were nasal discharge 100%, nasal obstruction 97.4%, headache 54.8% and anosmia 54.8%. In a study conducted by Pokharel M et al<sup>11</sup> the symptoms were in contrast to our study which had nasal discharge (25.3%), nasal obstruction (85.1%), headache (80.5%), hyposmia (8%) halitosis (5.7%) and facial pain (2.3%) of patients. In a study conducted by Lohiya et al<sup>12</sup> on 100 patients had nasal obstruction in 95% patients, nasal discharge in 66% patients, facial pain in 60% patients and hyposmia in 54% patients. In a study conducted by Rathor and Bhattacharjee on 34 patients, 24(70.6%) patients had nasal discharge, 30(88.2%) had nasal obstruction, 27 (79.4%) had hyposmia and 28 (82.4%) had headache.<sup>13</sup>

In our study after combined therapy with oral and topical steroids there was improvement in 47 patients (94%) in nasal obstruction, 48 patients (96%) in nasal discharge, 25 patients (50%) in facial pain and 17 patients (34%) in hyposmia with an overall improvement in VAS score in 42 patients (84%). The results of our study were similar to a study conducted by Rino K et al<sup>7</sup> where there was an improvement in nasal obstruction (98.5%), nasal discharge (83.6%), hyposmia (89.6%) and facial pain (68.7%) after treatment. In a study conducted by Vaidyanathan et al<sup>6</sup> on 60 patients to know the efficacy and safety of oral steroid therapy for 2 weeks followed by 26 weeks of topical steroid therapy on CRSwNP 25 patients (83%) had an improvement in hyposmia. Pirochchai et al<sup>14</sup> in their study reviewed various treatment options in CRSwNP and CRSsNP and found that a short-term use of oral corticosteroids combined with topical corticosteroids improved the symptoms in both groups. A study conducted by Bonfils et al<sup>15</sup> on 100 patients receiving combination therapy and follow up for three years

showed improvement in nasal obstruction and hyposmia in 85% patients. Dijkstra in 2004 studied 162 patients using Fluticasone propionate nasal spray for 52 weeks shows there is overall improvement in visual analogue score and less polyp recurrence.<sup>16</sup> Rowe Jones in 2005 used fluticasone spray on 109 patients for 5yrs shows significant improvement in overall VAS and less recurrent rate.<sup>17</sup>

In our study 26 patients (52%) had bilateral polyps and 24 patients (48%) had unilateral polyps on nasal endoscopy and CT PNS showed that maxillary sinuses were the most common sinuses affected with 47 patients (94%) followed by anterior ethmoids with 46 patients (92%), posterior ethmoids with 36 patients (72%), frontal sinuses with 25 patients (50%) and the least common sinus involved was sphenoid sinus with 12 patients (24%). In a study conducted by Baruah et al<sup>18</sup> on 201 patients with CRSwNP, unilateral polyps were observed in 45 patients and bilateral polyps were observed in 79 patients on nasal endoscopy and on CT PNS 44the most commonly involved sinus in 161 patients (80%) was maxillary sinus followed by 75 patients (37.3%) with anterior ethmoids, 58 patients (28.8%) with posterior ethmoids, 23 % with frontal sinus and 16.4% with sphenoid sinus opacifications. In a study by Lloyd et al<sup>19</sup> the most common sinus involved was maxillary sinus (83%) followed by anterior ethmoid (63%) whereas in the study by Zojaji et al<sup>20</sup> the least affected sinuses were the frontal (20%) and sphenoid sinuses (25%) respectively. In our study the osteomeatal complex was blocked in 38 patients (76%) whereas in a study by Neto et al<sup>21</sup> osteomeatal complex was blocked in 65% patients and Bolger et al<sup>22</sup> have observed the variations of osteomeatal complex blockage with a frequency of 64.9%.

In our study post treatment Nasal endoscopy (Lund - Mackay scoring) improved in 43 patients (86%) and CT PNS & Nose (Lund - Mackay scoring) improved in 33 patients (66%). Lal et al<sup>23</sup> in their study on 145 patients with combined steroids for 4 weeks reported resolution of symptoms and endoscopic scores in 74 patients (51.03%) during the 2 months follow up period. Subramanian et al<sup>24</sup> in their retrospective study on 40 patients on analysis of treatment outcomes for chronic sinusitis found that 36 patients (90%) patients had improvement in symptoms and CT scores after 6-8 weeks of combination therapy which was similar to findings of our study. In a study conducted by Alobid et al.<sup>25</sup> on 78 patients to evaluate the effects of short course of oral steroids for 2 weeks and long-term topical steroids for 12 weeks, 24 weeks and 48 weeks follow up concluded that there was a reduction in nasal symptoms and polyp size and improvement in nasal endoscopy scores.

## 5. Conclusion

Combined treatment with oral prednisolone and topical fluticasone propionate nasal spray for 3 weeks is effective in improving nasal symptoms and decreasing polyp size in

Chronic rhino sinusitis with Nasal Polyposis (CRSwNP) without sustained adverse effects. Nasal endoscopy is convenient, legitimate and easily available instrument for evaluating patients with CRSwNP. CT scan of PNS & Nose acts as a gold standard in discerning the disease in patients with constrained or poor visualization on endoscopy, because of polyps, deviated nasal septum, blockage of osteomeatal complex.

## 6. Source of Funding

None.

## 7. Conflict of Interest

The authors declare no relevant conflicts of interest.

## References

1. Chaaban MR, Walsh EM, Woodworth BA. Epidemiology and differential diagnosis of nasal polyps. *Am J Rhinol Allergy*. 2013;27(6):473–81.
2. Kolethekkat AA, Paul RR, Kurien M, Kumar S, Abri A, Thomas R. Diagnosis of adult chronic rhinosinusitis: can nasal endoscopy predict intranasal disease. *Oman Med J*. 2013;28(6):427–58.
3. Lohiya SS, Patel SV, Pawde AM, Bokare BD, Sakhare PT. Comparative Study of Diagnostic Nasal Endoscopy and CT Paranasal Sinuses in Diagnosing Chronic Rhinosinusitis. *Indian J Otolaryngol Head Neck Surg*. 2016;68(2):224–33.
4. Banerji A, Piccirillo JF, Thawley SE, Levitt RG, Schechtman KB, Krampfer MA. Chronic rhinosinusitis patients with polyps or polypoid mucosa have a greater burden of illness. *Am J Rhinol*. 2007;21(1):19–26.
5. Jankowski R, Klossek JM, Attali V, Coste A, Serrano E. Long-term study of fluticasone propionate aqueous nasal spray in acute and maintenance therapy of nasal polyposis. *Allergy*. 2009;64(6):944–50.
6. Vaidyanathan S, Barnes M, Williamson P, Hopkinson P, Donnan PT, Lipworth B. Treatment of chronic rhinosinusitis with nasal polyposis with oral steroids followed by topical steroids: a randomized trial. *Ann Intern Med*. 2011;154(5):293–302.
7. Rino K, Chettri MN, Moirentem NS, Zoramthari R, Thongam KD, Singh MM. Effects of oral prednisolone and fluticasone nasal spray in the management of nasal polypi. *J Med Soc*. 2016;30(3):135–40.
8. Ling FT, Kountakis SE. Important clinical symptoms in patients undergoing functional endoscopic sinus surgery for chronic rhinosinusitis. *Laryngoscope*. 2007;117(6):1090–3.
9. Nayak S, Kirtane MV, Ingle MV. Functional endoscopic sinus surgery—II (A preliminary study). *J Postgrad Med*. 1991;37(1):31–5.
10. Lilly-Tariah OD. Pattern of clinical features of chronic simple rhinosinusitis in Port Harcourt. *Niger J Clin Pract*. 2006;9(2):142–8.
11. Pokharel M, Karki S, Shrestha BL, Shrestha I, Amatya RC. Correlations between symptoms, nasal endoscopy computed tomography and surgical findings in patients with chronic rhinosinusitis. *Kathmandu Univ Med J (KUMJ)*. 2013;11(43):201–6.
12. Lohiya SS, Patel SV, Pawde AM, Bokare BD, Sakhare PT. Comparative Study of Diagnostic Nasal Endoscopy and CT Paranasal Sinuses in Diagnosing Chronic Rhinosinusitis. *Indian J Otolaryngol Head Neck Surg*. 2016;68(2):224–33.
13. Rathor A, Bhattacharjee A. Clinical-radiological correlation and role of computed tomography staging in chronic rhinosinusitis. *World J Otorhinolaryngol Head Neck Surg*. 2017;3(3):169–75.
14. Pirochchai P, Kasemsiri P, Laohasiriwong S, Thanaviratnanich S. Chronic rhinosinusitis and emerging treatment options. *Int J Gen Med*. 2013;6:453–64. doi:10.2147/IJGM.S29977.
15. Dijkstra MD, Ebbens FA, Poublon RM, Fokkens WJ. Fluticasone propionate aqueous nasal spray does not influence the recurrence rate of chronic rhinosinusitis and nasal polyps 1 year after functional endoscopic sinus surgery. *Clin Exp Allergy*. 2004;34(9):1395–400.
16. Bonfils P, Norès JM, Halimi P, Avan P. Corticosteroid treatment in nasal polyposis with a three-year follow-up period. *Laryngoscope*. 2003;113(4):683–90.
17. Medcalf RJ, Durham M, Richards SR, Mackay DH. Functional endoscopic sinus surgery: 5 year follow up and results of a prospective, randomised, stratified, double-blind, placebo-controlled study of postoperative fluticasone propionate aqueous nasal spray. *Rhinology*. 2005;43(1):2–10.
18. Baruah S, Vyas P, Srivastava A. CT scan vs nasal endoscopy findings in the diagnosis of chronic rhinosinusitis: our experience. *Int J Otorhinolaryngol Head Neck Surg*. 2019;5(3):739–45.
19. Lloyd GA. CT of the paranasal sinuses: study of a control series in relation to endoscopic sinus surgery. *J Laryngol Otol*. 1990;104(6):477–81.
20. Zojaji R, Mirzadeh M, Naghibi S. Comparative evaluation of preoperative CT scan and intraoperative endoscopic sinus surgery findings in patients with chronic rhinosinusitis. *Iran J Radiol*. 2008;5(2):77–82.
21. Neto S, Martins P, Souza AS, Baracat E, Nanni L. The role of osteomeatal complex anatomical variants in chronic rhinosinusitis. *Radiol Bras*. 2004;39:227–59.
22. Bolger WE, Butzin CA, Parsons DS. Paranasal sinus bony anatomic variations and mucosal abnormalities: CT analysis for endoscopic sinus surgery. *Laryngoscope*. 1991;101(1):56–64.
23. Lal D, Scianna JM, Stankiewicz JA. Efficacy of targeted medical therapy in chronic rhinosinusitis, and predictors of failure. *Am J Rhinol Allergy*. 2009;23(4):396–400.
24. Subramanian HN, Schechtman KB, Hamilos DL. A retrospective analysis of treatment outcomes and time to relapse after intensive medical treatment for chronic sinusitis. *Am J Rhinol*. 2002;16(6):303–315.
25. Alomid I, Benitez P, Pujols L, Maldonado M, Bernal-Sprekelsen M, Morello A. Severe nasal polyposis and its impact on quality of life. The effect of a short course of oral steroids followed by long-term intranasal steroid treatment. *Rhinology*. 2006;44(1):8–13.

## Author biography

**Sriharsha Vijay Jonnalagadda**, DNB Resident MBBS, DLO, DNB (ENT)

**Ashwin Ashok Jaiswal**, Consultant MBBS, DLO, DNB (ENT)

**Neeta Sharma**, Joint Director MBBS, DLO, DNB (ENT)

**Prachi Mene**, Consultant MBBS, DNB (ENT)

**Cite this article:** Jonnalagadda SV, Jaiswal AA, Sharma N, Mene P. Effects of oral prednisolone and fluticasone nasal spray in the management of chronic rhinosinusitis with polyposis: A prospective observational study. *IP Indian J Anat Surg Head, Neck Brain* 2023;9(1):8-14.