

Content available at: <https://www.ipinnovative.com/open-access-journals>

IP Indian Journal of Anatomy and Surgery of Head, Neck and Brain

Journal homepage: <https://www.ijashnb.org/>

## Case Report

# Mammary analogue secretory carcinoma (MASC) of parotid gland- A case report

Pratiksha Pawar<sup>1,\*</sup>, Shubhanshi Kangloo<sup>1</sup>, Ameya Bihani<sup>1</sup>, Kunal Gupta<sup>1</sup>,  
Chetna Bora Surana<sup>2</sup>

<sup>1</sup>Dept. of Head and Neck Oncosurgery, SRJ-CBCC Cancer Hospital, Indore, Madhya Pradesh, India

<sup>2</sup>Dept. of Pathology, SRJ-CBCC Cancer Hospital, Indore, Madhya Pradesh, India



### ARTICLE INFO

#### Article history:

Received 08-05-2023

Accepted 11-07-2023

Available online 08-08-2023

#### Keywords:

MASC

Mammary Analogue Secretory

Carcinoma

S100

Mammaglobin

ETV6NTRK3

### ABSTRACT

Mammary analogue secretory carcinoma is a rare salivary gland carcinoma which shares morphologic and immunohistochemical features with the secretory carcinoma of breast and was first proposed by Skalova in 2010 with translocation of (q13; q25), t (12; 15), subsequently giving ETV6-NTRK3 gene rearrangement. Usually, it is a benign tumor that affects the parotid gland, with slight predilection for males. The present article report a case of secretory carcinoma of right parotid gland with special emphasis on histological feature and immunohistochemistry for diagnostic purpose and its management. Differential diagnosis includes AcicC, ADC-NOS and MEC. In a review by Chiosa et al (2012) in 337 cases of salivary gland malignancy included AcicC, ADC-NOS, MEC, LGCC, non-ITAC, signet ring adenocarcinoma, PLGA and most common malignancy reclassified as MASC were AcicC (11/89), ADC-NOS (14/37), MEC (1/165). Management for MASC includes surgical excision of the lesion (either superficial or total parotidectomy) for local, less aggressive disease like for low-grade malignant salivary gland neoplasms. For more invasive, metastatic disease and positive margins- neck dissection, radiotherapy and chemotherapy are reserved. There is no standard multidisciplinary treatment protocol established due to scarcity of this disease.

This is an Open Access (OA) journal, and articles are distributed under the terms of the [Creative Commons Attribution-NonCommercial-ShareAlike 4.0 License](https://creativecommons.org/licenses/by-nc-sa/4.0/), which allows others to remix, tweak, and build upon the work non-commercially, as long as appropriate credit is given and the new creations are licensed under the identical terms.

For reprints contact: [reprint@ipinnovative.com](mailto:reprint@ipinnovative.com)

## 1. Introduction

Mammary analogue secretory carcinoma is a rare salivary gland carcinoma which shares morphologic and immunohistochemical features with the secretory carcinoma of breast and was first proposed by Skalova in 2010 with translocation of (q13; q25), t (12; 15), subsequently giving ETV6-NTRK3 gene rearrangement.<sup>1</sup> Usually it is a benign tumor that affects the parotid gland, with slight predilection for males.<sup>2</sup> MASC is referred to as secretory carcinoma after WHO of Head and Neck Tumours changed it in the 4th edition in 2017 to standardised the nomenclature for these tumours occurring at different organ sites. The present article report a case of secretory

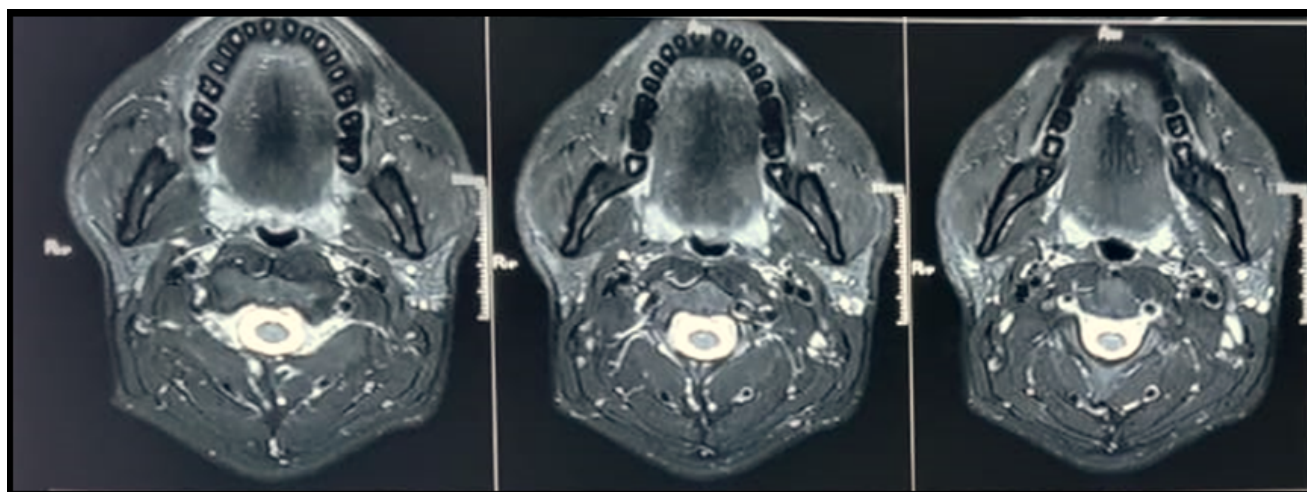
carcinoma of right parotid gland with special emphasis on histological feature and immunohistochemistry for diagnostic purpose and its management.

## 2. Case Report

A 27-year-old male reported with a chief complaint of swelling in right preauricular region with no past medical history. He gave history of getting treated that is enucleation for the same 15 days back. Physical examination demonstrated a 1× 1.5 cm, firm, fixed, non-tender swelling on the right angle of the mandible with a scar of approximately 1.5-2 cm. There was no other palpable lymphadenopathy present on the neck and his facial nerve function was intact.

\* Corresponding author.

E-mail address: [drpratikshapawar@gmail.com](mailto:drpratikshapawar@gmail.com) (P. Pawar).



**Fig. 1:** MRI scan axial cuts showing heterogeneously enhancing soft tissue lesion in the superficial lobe of right parotid tissue.

**Table 1:**

	<b>Mammary analogue secretory carcinoma (MASC)</b>	<b>Acinic cell carcinoma (AciCC)</b>	<b>Low-grade mucoepidermoid carcinoma (MEC)</b>
Histology	<ul style="list-style-type: none"> <li>• Cystic, papillary and solid architecture</li> <li>• Bland, low-grade nuclei</li> <li>• Vacuolated eosinophilic cytoplasm</li> <li>• Intracytoplasmic and intraluminal mucin</li> <li>• Colloid-like secretions</li> </ul>	<ul style="list-style-type: none"> <li>• solid, microcystic, papillary, or follicular architecture</li> <li>• cytoplasmic PAS-positive, diastase-resistant zymogen granules</li> <li>• frequent lymphoid infiltrate</li> <li>• usually mucin negative</li> </ul>	<ul style="list-style-type: none"> <li>• variably cystic and solid architecture</li> <li>• mucous, intermediate, and epidermoid cells</li> <li>• inflammation and fibrosis common</li> </ul>
Positive staining of tumor cells	S-100 Mammoglobin	Amylase S-100 DOG-1	P63 Cytokeratins
Negative staining of tumor cells	P63	P63	S100
Genetics	ETV6-NTRK3	None	CRTC1-

MRI head and neck showed a discrete heterogeneously enhanced soft tissue in parotid substance predominantly along superficial lobe of right parotid gland which measures approximately 1.3 x 1.1 x 1.6 cm in size containing few debris (Figure 1). The lesion appears to be subtle indenting to posterior fibre of masseter since it is located anteroinferiorly in the right superficial parotid gland. Few subcentimeter oval shaped lymph nodes are seen in bilateral submandibular and jugulodigastric and few superficial chain of cervical. No significant infrahyoid lymphadenopathy is noted. There was previous history of epileptic attacks on imaging which reveals a sharp marinated CSF attenuating cystic lesion in right half of dorsum of midbrain, which measures approximately 1.6 x 1.2 x 1.6 cm in size producing mild mass-effect and perifocal edema and causing subtle effacement of right half of ambient as well as perimesencephalic cistern.

We performed partial superficial parotidectomy and level II lymph node dissection. Histopathological examination showed sections of capsulated neoplasm with microcystic

pattern of tumor cells where cells have eosinophilic vacuolated cytoplasm with round nuclei and vesicular chromatin. Focal partial capsular invasion was noted. Peripheral rim of native parotid parenchyma was present all around. This suggested of Mammary Analogue Secretory Carcinoma. On immunohistochemistry studies the tumor cells were positive for S100, Mammaloglobin (focal positive), MUCA and negative for DOG1. Ki67 proliferation index was 10%. This confirmed for the diagnosis of MASC.

### 3. Discussion

MASC is usually a solitary and well circumscribed mass often encapsulated, gray or brown in colour with rubbery texture.<sup>3</sup> It is a slow growing painless nodule, which is mostly detected incidentally on physical examination. Few features involve skin infiltration, cervical lymphadenopathy, ulceration or facial nerve involvement and even pain.<sup>4</sup>

Earlier MASC was classified as ‘zymogen-poor’ AcicC (acinic cell carcinoma) due its overlapping histological features till Skalova et al in 2010 first described histological and immunohistochemical findings in a series of 16 MASC patients with ETV6-NTRK3 gene rearrangement which was not found in conventional salivary AcicC and this differentiated MASC from later.<sup>1</sup>

Major histologic and cytopathological features of MASC with AcicC and MEC are given in Table 1.

Bissinger et al (2017) described three cases of MASC that displayed strong positivity for CK7 and focal positivity for CK 5/6 and moderate to strong positivity for S100, mammaglobin (in all cases) and muc-4 (additional in two cases). Whereas CK14, estrogen and progesterone receptors, p53, her2/neu, PSA (prostate- specific antigen) and androgen receptor were negative. Translocation of ETV6-NTRK3 gene fusion with t(12;15)(p13;q25) was found in upto 60% of tumor cell nuclei by FISH (Fluorescent In Situ Hybridization) analysis.<sup>1,5-9</sup>

Differential diagnosis includes AcicC, ADC-NOS and MEC. In a review by Chiosa et al (2012) in 337 cases of salivary gland malignancy included AcicC, ADC-NOS, MEC, LGCC (low grade salivary duct carcinoma), non-ITAC (non-intestinal type adenocarcinoma), signet ring adenocarcinoma, PLGA (polymorphous low grade adenocarcinoma) and most common malignancy reclassified as MASC were AcicC (11/89), ADC-NOS (14/37), MEC (1/165).<sup>10</sup>

Most recently, new diagnostic features were also reported. Irregularity in nuclear membrane was found recently as a new diagnostic criterion other than translocation of genes and solid/cystic component of tumor.<sup>9</sup> There are different imaging modalities used for diagnosis including ultrasound (US), CT and MRI.<sup>2,7,9,11,12</sup> In ultrasound imaging it appears to be hypoechoic or hyperintense on T1 phase of MRI. In a case study hormonal receptor status as “triple negative” -ER/PR/HER-2.<sup>7</sup> But hormonal receptors were not investigated in all cases and indication for reporting this is also not clear.

MASC is considered more aggressive as compared to AcicC in some studies, due to bigger number of positive lymph nodes during nodal dissection with high rate of recurrence. But due to a smaller number of cases this has not been proven with statistical significance. Also, MASC does not have standard grading system for pathology due to recent discovered neoplasm.<sup>2,6,7,13</sup>

Management for MASC includes surgical excision of the lesion (either superficial or total parotidectomy) for local, less aggressive disease like for low-grade malignant salivary gland neoplasms. For more invasive, metastatic disease and positive margins- neck dissection, radiotherapy and chemotherapy are reserved. There is no standard multidisciplinary treatment protocol established due to scarcity of this disease.<sup>2,6,7,10,14</sup> Although, almost all patients reported in cases underwent complete excision,

neck dissections for it was considered as patients may have lymph nodes or high grade transformation.<sup>1,2,5-7</sup> Suzuki reported a case of MASC tumor with metastatic lymph nodes and unknown primary origin for which radical neck dissection was done without adjuvant treatment and patient was asymptomatic for 9 months.<sup>11</sup>

Entrectinib (tyrosine kinases inhibitor of TRKA/B/C), genetic targeted therapy has potential towards MASC. Drilon et al. reported a case study of female patient of MASC with NTRK3-rearrangement (previously diagnosed as AcicC). She was treated with pan-Trk inhibitor entrectinib and responded initially with symptom and tumour bulk resolution but developed resistance to TrkC inhibition due to mutation of NTRK3G623R. Despite this, targeted pharmacological intervention was introduced for this malignancy.<sup>6,13-15</sup> Recently, STARTRK (Studies of Tumor Alterations Responsive to Targeting Receptor Kinases)-2 is an ongoing Phase 2 study.<sup>15</sup>

#### 4. Conflicts of Interest

None.

#### 5. Source of Funding


None.

#### References

- Skalova A, Vanecek T, Sima R. Mammary analogue secretory carcinoma of salivary glands, containing the ETV6- NTRK3 fusion gene: a hitherto undescribed salivary gland tumor entity. *Am J Surg Pathol.* 2010;34(5):599–608. doi:10.1097/PAS.0b013e3181d9efcc.
- Sethi R, Kosinski E, Remenschneider A. Mammary analogue secretory carcinoma: Update on a New Diagnosis of Salivary Gland Malignancy. *Laryngoscope.* 2014;124(1):188–95.
- Bishop JA, Yonescu R, Batista DA, Westra WH, Ali SZ. Cytopathologic features of mammary analogue secretory carcinoma. *Cancer Cytopathol.* 2012;121(5):228–33. doi:10.1002/cncy.21245.
- Bissinger O, Götz C, Kolkata A. Mammary Analogue Secretory Carcinoma of Salivary Glands: Diagnostic Pitfall with Distinct Immunohistochemical Profile and Molecular Features. *Sage J.* 2017;9(3):89–92.
- Bishop JA, Yonescu R, Batista D, Eisele DW, Westra WH. Most nonparotid “acinic cell carcinomas” represent mammary analog secretory carcinomas. *Am J Surg Pathol.* 2013;37(7):1053–7. doi:10.1097/PAS.0b013e3182841554.
- Damjanov I, Skenderi F, Vranic S. Mammary Analogue Secretory Carcinoma(MASC) of the salivary gland: a new tumor entity. *Bosn J Basic Med Sci.* 2016;16(3):237–8. doi:10.17305/bjbm.2016.1321.
- Albus J, Batanian J, Wenig BM, Vidal CI. A unique case of a cutaneous lesionresembling mammary analog secretory carcinoma: a case report and reviewof the literature. *Am J Dermatopathol.* 2015;37(4):41–4. doi:10.1097/DAD.000000000000098.
- Chiose SI, Griffith C, Assaad A, Seethala RR. Clinicopathologicalcharacterization of mammary analogue secretory carcinoma of salivaryglands. *Histopathology.* 2012;61(3):387–94. doi:10.1111/j.1365-2559.2012.04232.x.
- Gonzalez MF, Akhtar I, Manucha V. Additional diagnostic features ofmammary analogue secretory carcinoma on cytology. *Cytopathology.* 2018;29(1):100–3. doi:10.1111/cyt.12465.
- Chiose SI, Griffith C, Assaad A, Seethala RR. The profile of acinic cell carcinoma after recognition of mammary analog

- secretory carcinoma. *Am J Surg Pathol*. 2012;36(3):343–50. doi:10.1097/PAS.0b013e318242a5b0.
11. Suzuki K, Yagi M, Kanda A, Kobayashi Y, Konishi M, Miyasaka C, et al. Mammary analogue secretory carcinoma presenting as a cervicallymph node metastasis of unknown primary site: a case report. *Case Rep Oncol*. 2017;10(1):192–8.
  12. Serrano-Arévalo ML, Mosqueda-Taylor A, Domínguez-Malagón H, Michal M. Mammary analogue secretory carcinoma (MASC) of salivary gland in four Mexican patients. *Med Oral Patol Oral Cir Bucal*. 2015;20(1):23–9. doi:10.4317/medoral.19874.
  13. Stevens TM, Parekh V. Mammary analogue secretory carcinoma. *Arch Pathol Lab Med*. 2016;140(9):997–1001. doi:10.5858/arpa.2015-0075-RS.
  14. Drilon A, Li G, Dogan S, Gounder M, Shen R, Arcila M, et al. What hides behind the MASC: clinical response and acquired resistance to entrectinib after ETV6-NTRK3 identification in a mammary analogue secretory carcinoma (MASC). *Ann Oncol*. 2016;27(5):920–6.
  15. Drilon A, Sankhala KK, Liu SV, Cho BC, Blakely C, Chee CE, et al. Abstract CT060: STARTRK-2: a global phase 2, open-label, basket study of entrectinib in patients with locally advanced or metastatic solid tumor harboring TRK, ROS1, or ALK gene fusions. *Cancer Res*. 2017;77:60–60.

## Author biography

**Pratiksha Pawar**, Fellow  <https://orcid.org/0000-0001-8885-741X>

**Shubhanshi Kangloo**, Fellow  <https://orcid.org/0000-0002-4468-8244>

**Ameya Bihani**, Consultant  <https://orcid.org/0000-0002-3799-389X>

**Kunal Gupta**, Consultant  <https://orcid.org/0000-0002-8255-8950>

**Chetna Bora Surana**, Consultant  <https://orcid.org/0009-0001-3747-3624>

**Cite this article:** Pawar P, Kangloo S, Bihani A, Gupta K, Surana CB. Mammary analogue secretory carcinoma (MASC) of parotid gland- A case report. *IP Indian J Anat Surg Head, Neck Brain* 2023;9(2):72-75.