

Content available at: <https://www.ipinnovative.com/open-access-journals>

IP Indian Journal of Anatomy and Surgery of Head, Neck and Brain

Journal homepage: <https://www.ijashnb.org/>

Original Research Article

A retrospective study of cerebellopontine angle tumours: A single institutional study

B S Faraz Ahmed¹, Shashivadhanan Sundaravadhanan^{1,*}, Neerav Porwal¹, Manish Sharma¹, Mannu Tiwari¹¹Dept. of Neurosurgery, Armed Forces Medical College Pune, Maharashtra, India

ARTICLE INFO

Article history:

Received 10-09-2023

Accepted 18-10-2023

Available online 30-10-2023

Keywords:

Cerebellopontine angle tumors

Acoustic schwannoma

vestibular schwannoma

meningioma

Retrosigmoid approach

ABSTRACT

Introduction: Cerebellopontine angle (CPA) tumors are rare intracranial neoplasms that arise in the region between the cerebellum and the pons.¹ These tumors can be challenging to treat due to their complex anatomy and proximity to critical neurovascular structures. Surgical intervention is often necessary to achieve a favorable outcome.

Aims and Objectives: The primary objectives of this retrospective study are to analyze the clinical and radiological characteristics of cerebellopontine angle tumors, identify pathological types, assess surgical resectability, and evaluate postoperative outcomes.

Materials and Methods: The study enrolled 14 patients who underwent surgical intervention for cerebellopontine angle tumors at Armed forces medical college, Pune. A retrospective analysis was performed, considering demographic data, clinical presentations, imaging characteristics and surgical outcomes.

Results: Vestibular schwannoma was the predominant tumor type with majority of tumors manifesting between third to fifth decades. Clinical manifestation included SNHL, cerebellar dysfunction, headache and sensory trigeminal dysfunction. A substantial proportion (86%) presented with no useful hearing preoperatively. Surgical outcomes indicated varying degrees of success, with total resection achieved in a subset of cases. Notably, anatomical preservation of the facial nerve was accomplished in a significant proportion of patients. Postoperative assessments, using the House Brackmann system, revealed positive facial nerve function outcomes in a substantial percentage. Complications included cerebrospinal fluid leak (14%), meningitis (7%) and lower cranial nerve paresis (7%).

Conclusion: In conclusion, surgical intervention plays a crucial role in the management of cerebellopontine tumors. The choice of surgical approach should be individualized based on tumor characteristics and patient factors, with the goal of achieving maximum tumor resection while minimizing complications. Further research and advancements in surgical techniques are needed to optimize outcomes for patients with cerebellopontine tumors.

This is an Open Access (OA) journal, and articles are distributed under the terms of the [Creative Commons Attribution-NonCommercial-ShareAlike 4.0 License](https://creativecommons.org/licenses/by-nc-sa/4.0/), which allows others to remix, tweak, and build upon the work non-commercially, as long as appropriate credit is given and the new creations are licensed under the identical terms.

For reprints contact: reprint@ipinnovative.com

1. Introduction

The cerebellopontine angle, a triangular space defined by the anteromedially pons, posteromedially cerebellum,

and lateral demarcation by the petrous part of the temporal bone.² Despite the predominantly benign nature of cerebellopontine angle tumors, the complex anatomy and the critical neurovascular structures traversing this space present a formidable challenge for neurosurgeons venturing into its surgical domain.

* Corresponding author.

E-mail address: drshashivadhanan@gmail.com (S. Sundaravadhanan).

Vestibular schwannomas emerge as the predominant cohort, constituting approximately 80% of cerebellopontine angle tumors. Beyond this, the spectrum encompasses meningiomas, epidermoids, arachnoid cysts, and rarer entities such as trigeminal schwannomas, facial nerve schwannomas, exophytic brainstem gliomas, secondaries, and choroid plexus papillomas.³ Surgical intervention stands as the cornerstone for managing these tumors, excluding cases with smaller dimensions (<2.5 cm), where radiosurgery might offer a viable alternative.²

The evolution of diagnostic imaging has played a pivotal role in the paradigm shift of cerebellopontine angle tumor management. Improved imaging capabilities enable the detection of smaller tumors at earlier stages, enhancing the potential for hearing preservation.⁴⁻⁶ This transformative journey in surgical strategy spans from historical practices of simple intratumoral decompression to contemporary approaches involving complete or near-complete microsurgical excision.⁷ Notably, this trajectory underscores a growing emphasis on preserving facial nerve function and maintaining hearing integrity, reflecting the nuanced evolution in the surgical landscape of cerebellopontine angle tumor

2. Aims and Objectives

1. Examine the demographic and clinical profiles of patients with cerebellopontine tumours.
2. Utilize advanced imaging to analyze the radiological characteristics including tumour size and location.
3. Investigate the pathological types of cerebellopontine angle tumours and correlate findings with clinical and radiological data.
4. Assess the feasibility of surgical resection and analyze outcomes, emphasizing facial nerve and hearing preservation.
5. Evaluate the postoperative outcomes, including facial nerve function, hearing preservation and complications.

3. Materials and Methods

This study was conducted within the Department of Neurosurgery at Armed forces medical college, Pune, focusing on a subset of 14 patients diagnosed with cerebellopontine angle tumors who underwent surgical intervention during the period from January 2022 to January 2023. The research design adopted for this study is retrospective.

3.1. Patient selection

Inclusion criteria encompassed patients with cerebellopontine angle tumors who underwent surgical procedures within January 2022 to January 2023.

3.2. Data collection

1. Patients were comprehensively evaluated concerning demographic details, including age and gender.
2. Clinical presentation details were documented to capture the diverse symptomatology associated with cerebellopontine angle tumors.
3. Imaging characteristics, obtained through advanced diagnostic modalities, were systematically recorded to facilitate a nuanced radiological analysis.
4. The feasibility of surgical resection was assessed, considering factors influencing the decision-making process.

4. Facial Nerve Function Assessment

1. Facial nerve function was meticulously graded using the House-Brackmann score pre-operatively, at the time of discharge, and during follow-up.
2. This objective grading system facilitated a quantitative assessment of facial nerve outcomes across various stages of the treatment continuum.⁸

4.1. Hearing evaluation

1. Pre-operative pure tone audiometry was employed to quantify the degree of hearing loss, employing the criterion of hearing loss <50 decibels for defining useful hearing.
2. Postoperative hearing assessments were selectively conducted in patients exhibiting useful hearing pre-operatively, providing insights into the impact of surgical interventions on auditory outcomes.

4.2. Surgical approach

All surgical interventions were executed through sub-occipital retro-mastoid craniectomy, employing established microsurgical techniques to ensure consistency in the operative approach

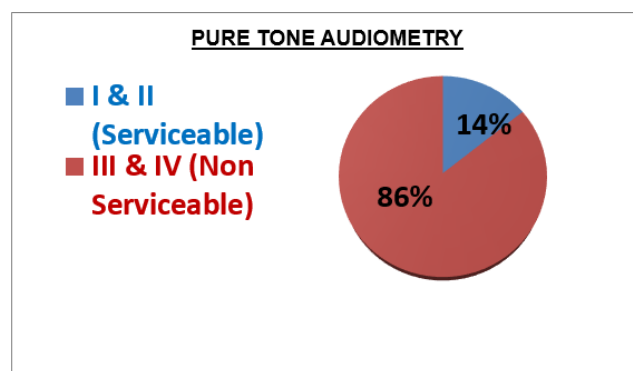


Fig. 1: Distribution of cases according to pure tone audiometry

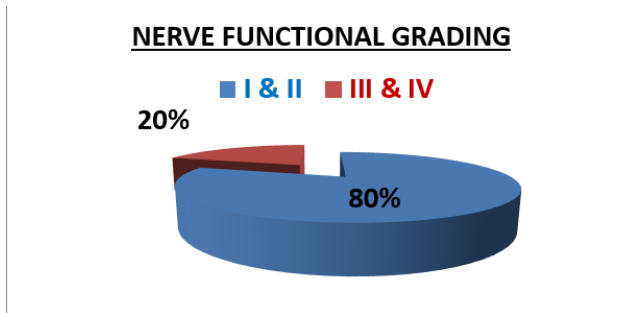


Fig. 2: Distribution of cases according to facial nerve functional grading

5. Results

In our study, vestibular schwannomas comprised a substantial majority, constituting 78.5% of cerebellopontine angle tumors within the cohort of 14 patients. The remaining cases included meningiomas (14.2%) and epidermoids (7%) Table 4. Notably, females exhibited a predilection for these tumors, accounting for 57.1% of the cases Table 1.

The age distribution revealed that 76% of vestibular schwannomas manifested in the third, fourth, and fifth decades. The primary presenting complaints encompassed sensorineural hearing loss, cerebellar dysfunction, headache, and sensory trigeminal dysfunction. Preoperatively, a significant proportion of cerebellopontine angle tumor patients experienced a lack of useful hearing (<50 decibels) Figure 1.

Large and giant tumors predominated, constituting 85% of cases Table 2. Some patients exhibited a transient deterioration in facial grade immediately postoperatively, which subsequently improved by the time of discharge and follow-up Figure 2.

Preoperative ventriculoperitoneal shunt placement was necessary in 21% of cerebellopontine angle tumor cases due to associated hydrocephalus Table 3. Total resection rates varied, with 63% achieved in vestibular schwannomas and a 50% in meningiomas. Subtotal resection, influenced by tumor adherence to the brainstem and facial nerve, characterized the remaining cases.

Complications included CSF leak from the wound site in 14% of cases, managed conservatively with lumbar drain and medication Table 5. Meningitis occurred in 7% of cases, all of which responded positively to appropriate antibiotic therapy. Lower cranial nerve paresis manifested in 7% of patients, necessitating management with nasogastric tube feeding Table 5. Two patients required temporary tracheostomy for the management of secretions and low conscious level.

Table 1: Distribution of cases according to sex

Sex	Vestibular Schwannoma	Meningioma	Epidermoid	Total	Sex
Female	5	2	1	8	Female
Male	6	0	0	6	Male

Table 2: Distribution of cases according to size of tumour

Size	No. of Patients	(%)
Medium (10-25mm)	2	14%
Large (26-40mm)	10	72%
Giant (> 40mm)	2	14%

Table 3: Distribution of cases according to surgical procedure

Surgical Procedure	No. of Patients	(%)
VP Shunt + Tumor surgery	3	21%
Direct Tumor surgery	11	79%

Table 4: Distribution of cases according to histopathology

Histopathology	No. of Patients	(%)
Vestibular schwannoma	11	78.5%
Meningioma	2	14.2%
Epidermoid	1	7.1%

6. Discussion

The management landscape of cerebellopontine angle tumors, particularly vestibular schwannomas, has witnessed substantial evolution over the years. Pioneering efforts by Cushing and Walter Dandy significantly reduced mortality rates, marking critical milestones in the early stages of surgical intervention. The transformative impact of the operating microscope, introduced by House, Rand, and Kurze in the 1960s, coupled with advancements in anesthesia and microsurgical techniques, has shifted the surgical paradigm from a focus on complete tumor excision to the preservation of facial and cochlear nerve functions.^{8,9}

In our study, a majority of patients (85%) presented with large and giant-sized tumors, necessitating a nuanced approach to surgical intervention. The prevalence of preoperative ventriculoperitoneal shunt requirement was 21%, a figure notably lower than the 66% reported in a study by Rama Murthi et al.¹⁰ and the 8.5% reported by VK Jain et al.¹¹ Complete tumor excision was achieved in 63% of our cases, contrasting with VK Jain et al.'s higher reported rate of 96.5%.¹⁰ Anatomical preservation of the facial nerve was successful in 74% in our study, aligning with preservation rates reported by Samii and Matthias (93%),⁵ although Jain VK et al. reported a slightly lower rate of 84.3%.¹¹

Preoperatively, 14% of our patients had useful hearing, with postoperative preservation achieved in 60% of these cases. This preservation rate compares favorably with studies reporting hearing preservation in the range of 23.6% to 29.6%.^{6,10-12} The incidence of cerebrospinal fluid leak in

Table 5: Distribution of cases according to complications

Complication	Vestibular Schwannoma (n=11)	Meningioma (n=2)	Epidermoid (n=1)	Total No. of Patients (n=14)	(%)
CSF Leak	2	0	0	2	14%
Meningitis	1	0	0	1	7%
Hematoma	0	0	0	0	0%
Nerve Palsy	1	0	0	1	7%

our study was 14%, managed conservatively, falling within the reported average range of 0-30%.¹³ While facial and vestibulocochlear nerve injuries are prominent risks during surgery, our study highlights the importance of recognizing potential lower cranial nerve injuries, occurring in 7% of cases. Judicious use of nasogastric tube feeding and planned tracheostomy proved effective in mitigating postoperative respiratory complications.

The sub-occipital retromastoid approach in the lateral position emerged as the consistent surgical technique employed in all cases.⁹ This discussion underscores the complexities and nuances involved in managing cerebellopontine angle tumors, emphasizing the importance of continuous refinement in surgical strategies to optimize patient outcomes.

7. Conclusion

In conclusion, our study of cerebellopontine angle tumors, provides valuable insights into the intricacies of this neurosurgical domain. Vestibular schwannomas emerged as the predominant tumor type, underscoring the evolving surgical landscape that emphasizes not only complete excision but also the preservation of facial and cochlear nerve functions.⁷ The clinical and radiological analyses shed light on the demographic distribution, presenting symptoms, and the prevalence of large or giant-sized tumors.¹⁴

The surgical outcomes revealed varying degrees of success, with notable achievements in facial nerve preservation and hearing outcomes.⁶ Despite the challenges posed by large-sized tumors, the anatomical preservation of the facial nerve was achieved in a substantial proportion of cases.¹⁵ The study also highlighted the importance of judicious pre-operative management, including the use of ventriculoperitoneal shunts in cases of associated hydrocephalus.¹⁴

Complications, including cerebrospinal fluid leaks, meningitis, and lower cranial nerve paresis, were managed effectively. Importantly, the mortality rate was limited, underscoring the overall safety and success of the surgical interventions.¹²

Our findings contribute to the evolving body of knowledge in cerebellopontine angle tumor management and provide a foundation for refining surgical strategies in this specialized field. The emphasis on preserving neurological functions, coupled with an understanding of

the specific challenges posed by tumor size, adds valuable insights to the existing literature. Further research with larger cohorts is warranted to corroborate and expand upon the trends observed in this focused study.

8. Source of Funding

None.

9. Conflict of Interest


None.

References

- House JW, Brackman DE. Facial Nerve Grading System Otolaryngol. *Head Neck Surg.* 1985;93(2):146–53.
- Jackler RK, Pitts LH. Acoustic neuroma. *Neurosurg Clin N Am.* 1990;1:199–233.
- Cushing H. Tumors of the nervus acusticus and the syndrome of cerebellopontine angle. 7th ed. and others, editor. Harvey Cushing M.d. Philadelphia And London: W. B. Saunders Company.; 1917. p. 241–2.
- Silverstein H, Daniel M, Norrell A. Hearing preservation after acoustic neuroma surgery with intraoperative direct eighth cranial nerve monitoring: Part II. A Classification of results. *Otolaryngol Head Neck Surg.* 1986;95(3):285–91.
- Samii M, Matthias C. Management of 1000 vestibular schwannomas: Clinical presentation. *Neurosurgery.* 1997;40(1):1–10.
- Fischer G, Fischer C, Rémond J. Hearing preservation in acoustic neurinoma surgery. *J Neurosurg.* 1992;76:910–7.
- Harner SG, Ebersold MI. Management of acoustic neuromas (1978-1983). *J Neurosurg.* 1985;63(2):175–84.
- Rand RW, Kurze T. Facial nerve preservation by posterior fossa transmeatal microdissection in total removal of acoustic neuroma. *J Neurol Neurosurg Psychiatry.* 1965;28(4):311–7.
- Ebersold MI, Harner SG. Current results of the retromastoid approach to acoustic neurinoma. *J Neurosurg.* 1992;76(6):901–10.
- Ramamurthi B. The continuing challenge of acoustic neurinomas (1949-1993). *Br J Neurosurg.* 1995;9(3):361–6.
- Vijendra K, Jain N. Surgery of vestibular schwannomas: an institutional experience. *Neurol India.* 2005;53(1):41–8.
- Somers T, Offeciers FE, Schattman I. Results of 100 vestibular schwannoma operations. *Acta Otorhinolaryngol Belg.* 2003;57(2):155–66.
- Brennan JW, Rowed DW, Nedzelski JM, Chen JM. Cerebrospinal fluid leak after acoustic neuroma surgery: Influence of tumor size and surgical approach on incidence and response to treatment. *J Neurosurg.* 2001;94(2):217–40.
- Jung S, Kang SS, Kim TS, Kim HJ, Jeong SK, Kim SC. Current surgical results of retrosigmoid approach in extralarge vestibular schwannomas. *Surg Neurol.* 2000;53(4):370–7.
- Grey PL, Moffat DA, Palmer CR, Hardy DG, Baguley DM. Factors which influence the facial nerve outcome in vestibular schwannoma surgery. *Clin Otolaryngol Allied Sci.* 1996;21(5):409–22.

Author biography

B S Faraz Ahmed, Senior Resident  <https://orcid.org/0000-0003-3068-4012>

Shashivadhanan Sundaravadhanan, HOD and Professor  <https://orcid.org/0000-0002-1202-1218>

Neerav Porwal, Associate Professor

Manish Sharma, Professor  <https://orcid.org/0000-0003-2325-9691>

Mannu Tiwari, Senior Resident  <https://orcid.org/0000-0003-3421-3787>

Cite this article: Faraz Ahmed BS, Sundaravadhanan S, Porwal N, Sharma M, Tiwari M. A retrospective study of cerebellopontine angle tumours: A single institutional study. *IP Indian J Anat Surg Head, Neck Brain* 2023;9(3):91-95.