

Content available at: <https://www.ipinnovative.com/open-access-journals>

IP Indian Journal of Anatomy and Surgery of Head, Neck and Brain

Journal homepage: <https://www.ijashnb.org/>

Case Report

Giant interhemispheric arachnoid cyst – A rare case report

S. Venkatesan¹, S. Balaji^{1,*}¹Dept. of Neurosurgery, Meenakshi Mission Hospital, Madurai, Tamilnadu, India

ARTICLE INFO

Article history:

Received 21-07-2023

Accepted 25-08-2023

Available online 30-10-2023

Keywords:

Cystoperitoneal shunt

Endoscopy

Interhemispheric arachnoid cyst

Macrocrania

ABSTRACT

IHACs (interhemispheric arachnoid cysts) are a rare kind of congenital arachnoid cyst that account for 5% of all occurrences. The best surgical treatment for symptomatic IHAC is still debatable, and there are no clear standards. At the time of presentation, the median age was 13 months. Macrocrania with rapidly increasing head size, seizures, infantile spasms, and developmental delay were the most common clinical manifestations. Endoscopic cyst fenestration and shunt surgery are both safe treatments for IHAC. We present an 11-month-old male infant born to non consanguineous parents who has had a steady rise in head size since 6 months of age and delayed mile stones. A magnetic resonance image of the brain revealed a massive interhemispheric arachnoid cyst, as well as corpus callosum agenesis and hypoplasia in both frontal lobes. Baby underwent endoscopic cyst fenestration and cystoperitoneal shunt.

This is an Open Access (OA) journal, and articles are distributed under the terms of the [Creative Commons Attribution-NonCommercial-ShareAlike 4.0 License](https://creativecommons.org/licenses/by-nc-sa/4.0/), which allows others to remix, tweak, and build upon the work non-commercially, as long as appropriate credit is given and the new creations are licensed under the identical terms.

For reprints contact: reprint@ipinnovative.com

1. Introduction

Interhemispheric arachnoid cysts (IHACs) are uncommon congenital lesions that contain cerebrospinal fluid (CSF) and are surrounded by arachnoid membranes in the interhemispheric fissure. Arachnoid cysts (AC) account for around 1% of all intracranial lesions.^{1–3} The most common location of supratentorial AC is the middle cranial fossa and IHACs are extremely rare accounting for 5% of all cases.^{4,5} The majority of IHAC are asymptomatic and discovered incidentally; however, big lesions might cause symptoms due to mass influence on adjacent brain tissue. IHAC typically occurs in the midline, near the lateral ventricle and cisterns. The symptom profile is determined by the location of the cysts. The majority of these cysts cause macrocephaly, developmental delay, and seizures.^{6–9} Asymptomatic IHAC can be followed, but symptomatic IHAC require surgical management.^{10,11} The optimal surgical therapy of these cystic lesions is

contentious and debatable. Craniotomy with microsurgical cyst fenestration, neuroendoscopic fenestration, or shunt implantation are surgical possibilities.^{2,7,8,12,13} Cyst fenestration means opening the cyst either into a ventricle (cystoventriculostomy [CV]) or cistern (cystocisternostomy [CC]) or both.^{1,9,13} In literature, there exist only a few small isolated case reports and small case series on IHAC and till date, there are no clear management guidelines.

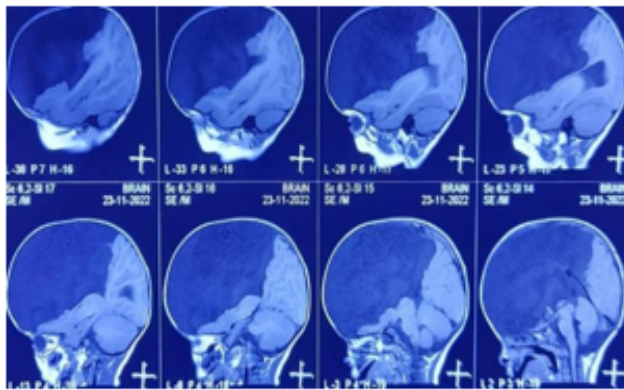
2. Case Description

A 11 months old male child first born to parents of non Consanguineous marriage brought with history of progressive increase in head size since 6 months of age and history of delayed mile stones (Head control attained at 6 months of age). Antenatal history was uneventful. Natal history revealed full term normal vaginal delivery, baby cried immediately and immunized till date. MRI brain was done showed huge interhemispheric arachnoid cyst with agenesis of corpus callosum and hypoplasia of both frontal lobes. Baby underwent endoscopic cyst fenestration and

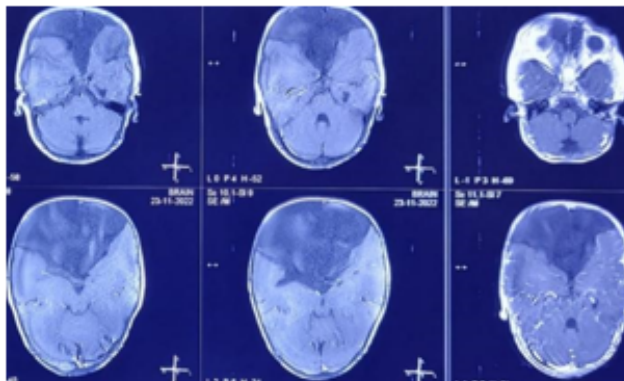
* Corresponding author.

E-mail address: narayanasmrithi@gmail.com (S. Balaji).

cystoperitoneal shunt. Post operative period was uneventful and discharged.



a



b

Fig. 1: MRI brain sagittal and axial showing huge interhemispheric arachnoid cyst with agenesis of corpus callosum

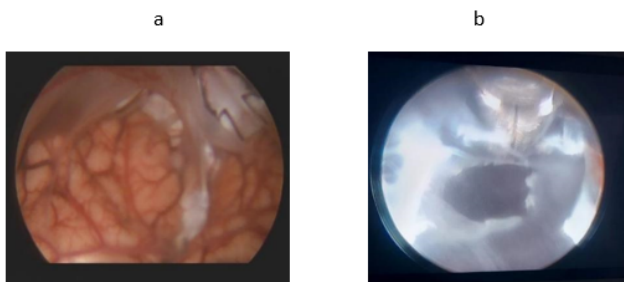


Fig. 2: (a) Endoscopic view showing hypoplasia of both frontal lobes (b) Endoscopic fenestration of arachnoid cyst

3. Discussion

ACs are rare congenital lesions which account for about 1% of all intracranial lesions in the paediatric population, and IHAC is the rarest type of AC^{1,4,10,11} and accounting

for 5% of all AC with male predominance. Only when patients appeared with symptoms and radiological tests were performed were they diagnosed. The optimal surgical therapy of symptomatic and big asymptomatic IHAC found accidentally is debatable in the literature. Large cysts with mass effect, macrocephaly, and intractable seizures appear to be a cause for surgical surgery. Patients who are asymptomatic require long-term radiological and clinical monitoring.^{6–8,14} Detailed neuropsychological evaluation could not be performed due to the young age of patients at presentation.

The two developmental malformations that need to be differentiated from IHAC are lobar holoprosencephaly and porencephalic cysts.^{4,15,16} Lobar holoprosencephaly occurs as a result of midline fusion of cerebral parenchyma with lateral ventricles, resulting in a single ventricle. Porencephalic cysts are intra-axial, readily communicate with the ventricle, and have no mass impact. IHAC is usually accompanied with cortical malformations, gyral abnormalities, and corpus callosum agenesis. Mechanical pressure is thought to interfere with the formation of the corpus callosum in IHAC.^{15–18} IHAC causes distortion of CSF pathways and produce symptoms when the cyst enlarges and cause mass effect on adjacent brain parenchyma.

IHAC has been historically classified using Barkovich classification system.¹⁷ Type 1 cysts are those in which there is a ventricular communication, whereas Type 2 cysts are those in which there is no communication. Type 2 IHAC associated with corpus callosum agenesis is further grouped as 2a if there is no abnormality other than agenesis of corpus callosum. IHAC associated with Aicardi syndrome and subcortical heterotopia are grouped as Type 2b, 2c, respectively. Mori further classified these cysts as either intra- or extra-axial depending on their location associated ventricular communication and corpus callosum agenesis.¹⁵ Extra-axial cysts were further classified and subdivided as unilateral, bilateral, and parasagittal. All the cysts in the current series were extra-axial type according to Mori classification. The distinction between extra-axial and intra-axial can be easily made on MRI. The presence or absence of ventricular communication is important for planning surgical treatment. Intra-axial cysts communicate with the ventricles and are associated with holoprosencephaly, diencephalic, porencephalic cysts, and other complex brain malformations.^{16,18}

The surgical intervention and surgical corridor chosen are determined by the location of the IHAC and its relationship to the ventricles and neighboring cisterns. Three surgical approaches have been described: craniotomy, endoscope, and shunt. Some writers have recommended total cyst membrane excision, but because to the proximity of the neurovascular systems, this is rarely done. With advances in neuroendoscopy technology, craniotomy-based

techniques are being mainly superseded by minimally invasive endoscopic surgery. Endoscopic surgery is also technically difficult and dangerous due to the distortion of operative anatomy, hence many neurosurgeons choose simpler shunt treatments. The surgical results of the current series are comparable to other published series on IHAC.^{6,13,14} On follow-up MRI, the cyst size decreased in all individuals. There were no severe shunt or endoscopic surgery-related problems in any of the patients in the current series until the final follow-up. The authors believe that there is always the possibility of shunt blockage and malfunction, which would necessitate revision surgery at a later point. There is no difference in quality of life after microsurgical, endoscopic, or shunt surgery in the published literature for AC.

4. Conclusion

Interhemispheric arachnoid cysts (IHACs) are a rare type of congenital arachnoid cyst, both endoscopic fenestration and cystoperitoneal shunting are safe and effective in management of symptomatic IHAC. The surgical mortality and morbidity are rare in experienced hands. Surgical treatment should be offered early to all symptomatic patients.

5. Financial Support and Sponsorship

Nil.

6. Conflicts of Interest

There are no conflicts of interest.

References

- Pradilla G, Jallo G. Arachnoid cysts: Case series and review of the literature. *Neurosurg Focus*. 2007;22(2):E7. doi:10.3171/foc.2007.22.2.7.
- Cincu R, Agrawal A, Eiras J. Intracranial arachnoid cysts: Current concepts and treatment alternatives. *Clin Neurol Neurosurg*. 2007;109(10):837–80.
- Duz B, Kaya S, Daneyemez M, Gonul E. Surgical management strategies of intracranial arachnoid cysts: A single institution experience of 75 cases. *Turk Neurosurg*. 2012;22(5):591–9.
- Rengachary SS, Watanabe I. Ultrastructure and pathogenesis of intracranial arachnoid cysts. *J Neuropathol Exp Neurol*. 1981;40(1):61–83.
- Spennato P, Ruggiero C, Aliberti F, Buonocore MC, Trischitta V, Cinalli G. Interhemispheric and quadrigeminal cysts. *World Neurosurg*. 2013;79(2):1–7.
- Caldarelli M, Rocco D. Surgical options in the treatment of interhemispheric arachnoid cysts. *Surg Neurol*. 1996;46(3):212–33.
- Ulu MO, Kafadar AM, Dashti R, Isler C, Uludag S, Erdinçler P, et al. Treatment of symptomatic interhemispheric arachnoid cysts by cystoperitoneal shunting. *J Clin Neurosci*. 2010;17(6):700–5.
- Lena G, Calenberg FV, Genitori L, Choux M. Supratentorial interhemispheric cysts associated with callosal agenesis: Surgical treatment and outcome in 16 children. *Childs Nerv Syst*. 1995;11(10):568–73.
- Giannetti AV, Fraga SM, Silva MC, Gurgel-Giannetti J. Endoscopic treatment of interhemispheric arachnoid cysts. *Pediatr Neurosurg*. 2012;48(3):157–62.
- Shim KW, Lee YH, Park EK, Park YS, Choi JU, Kim DS. Treatment option for arachnoid cysts. *Childs Nerv Syst*. 2009;25(11):1459–66.
- Khan IS, Sonig A, Thakur JD, ANanda. Surgical management of intracranial arachnoid cysts: Clinical and radiological outcome. *Turk Neurosurg*. 2013;23(2):138–81.
- Raffel C, McComb JG. To shunt or to fenestrate: Which is the best surgical treatment for arachnoid cysts in pediatric patients? *Neurosurgery*. 1988;23:338–80.
- Cinalli G, Peretta P, Spennato P, Savarese L, Varone A, Vedova P. Neuroendoscopic management of interhemispheric cysts in children. *J Neurosurg*. 2006;105(3):194–202.
- Talamonti G, Aliberti D, Picano G, Debernardi M, Collice A. Intracranial cysts containing cerebrospinal fluid-like fluid: Results of endoscopic neurosurgery in a series of 64 consecutive cases. *Neurosurgery*. 2011;68(3):788–803.
- Mori K. Giant interhemispheric cysts associated with agenesis of the corpus callosum. *J Neurosurg*. 1992;76:224–54.
- Doffe L, Adamsbaum C, Rolland Y, Robain O, Ponsot G, Kalifa G. Corpus callosum agenesis and parasagittal interhemispheric cyst. *J Radiol*. 1996;77:427–57.
- Barkovich AJ. Apparent atypical callosal dysgenesis: Analysis of MR findings in six cases and their relationship to holoprosencephaly. *AJNR Am J Neuroradiol*. 1990;11(2):333–42.
- Griebel ML, Williams JP, Russell SS, Spence GT, Glasier CM. Clinical and developmental findings in children with giant interhemispheric cysts and dysgenesis of the corpus callosum. *Pediatr Neurol*. 1995;13(2):119–43.

Author biography

S. Venkatesan, Senior Consultant

S. Balaji, Senior Resident  <https://orcid.org/0000-0001-9098-1372>

Cite this article: Venkatesan S, Balaji S. Giant interhemispheric arachnoid cyst – A rare case report. *IP Indian J Anat Surg Head, Neck Brain* 2023;9(3):103-105.