

Content available at: <https://www.ipinnovative.com/open-access-journals>

IP Indian Journal of Anatomy and Surgery of Head, Neck and Brain

Journal homepage: <https://www.ijashnb.org/>**Review Article****Modalities of lip reconstruction in facial surgery- A literature review****Rohit Narendra Rathod^{1*}, Bikash Kumar Bal¹**¹Dept. of Head and Neck Oncology, Shankus MediCity - SMC, Baliyasan, Gujarat, India**ARTICLE INFO***Article history:*

Received 29-10-2023

Accepted 15-12-2023

Available online 21-02-2024

Keywords:

Lip reconstruction

Lip defects

Oral cancer

Reconstruction

ABSTRACT

The authors provide an overview of lip reconstruction of various defects. Lip reconstruction offers unique challenges to preserve not only lip function but also aesthetics.

Lip reconstruction must take into consideration the three anatomical layers that comprise the lip and defects that involve the mucosa, the muscle, the skin or more than one layer will help determine the modality of repair. The authors offer an algorithm based on defect location, tissue involvement, and severity of defect to simplify an often complex decision-making process.

This is an Open Access (OA) journal, and articles are distributed under the terms of the [Creative Commons Attribution-NonCommercial-ShareAlike 4.0 License](https://creativecommons.org/licenses/by-nc-sa/4.0/), which allows others to remix, tweak, and build upon the work non-commercially, as long as appropriate credit is given and the new creations are licensed under the identical terms.

For reprints contact: reprint@ipinnovative.com**1. Introduction**

The principles of management of lip cancer require resection with negative margins and reconstruction of the defect to restore form and function. The ability to restore esthetics and oral competency, whether the defect is acquired by ablation or trauma, is based upon the size, location, and integrity of the local anatomy. Historically, surgical options for reconstruction of the lip have been categorized according to the size of the defect.

2. Discussion**2.1. Defects less than one-third of the lip****2.1.1. Wedge excision with primary closure**

Perhaps the simplest and most commonly used type of excision of a small invasive lip lesion is the wedge excision.¹⁻⁷ These can be classified based on the shape of the actual excision and include the V, W, shield, or pentagonal excisions. Each of these types of excisions is closed primarily with at least a three-layered closure

comprising mucosa, muscle, and skin. The key to favourable functional restoration relies on the re-approximation of the orbicularis oris muscle to reconstruct the oral sphincter.

Lip lesion excisions are commonly combined with vermilionectomy, or “lip shave,” when the lip vermilion is involved with actinic cheilitis, leukoplakia, or carcinoma in situ. Following vermilionectomy, the labial mucosa can be advanced to close the vermilion defect primarily. Many surgeons advocate the undermining of the mucosa in a plane between the orbicularis oris muscle and submucosa (which includes the minor salivary glands) to gain mobility and prevent the inward rolling of the lip during scar contracture.⁷

The V-wedge excision is the simplest type of excision and can be used for the upper or lower lip. Classically, it is described that defects of up to one-quarter of the upper lip and one-third of the lower lip can be closed primarily.^{1,2,5} While this may be the case, reconstructing the upper lip is not as straightforward as it is for the lower lip. Because the upper lip is made up of three esthetic subunits (philtrum and two lateral segments), a wedge excision will cause asymmetry of the lip. The lower lip, on the other hand, is composed primarily of one esthetic subunit and

* Corresponding author.

E-mail address: drnrnoms@gmail.com (R. N. Rathod).

will tolerate a wedge resection without much distortion. A wedge resection that is acceptable for a lower lip lesion may cause significant asymmetry of the upper lip, and in these cases, a lip-switch procedure, such as an Abbe flap (described later), may produce a superior cosmetic result.²

The V-wedge procedure begins with marking out oncologically safe resection margins on either side of the lesion (Figure 1).^{5,8,9} The apex of the excision lies at the labiomental crease of the lower lip or nasolabial fold of the upper lip. The full thickness of the lip is incised to resect the lesion, and the defect is closed primarily in at least three layers, with care taken to re-approximate the orbicularis oris muscle. The vermilion border must be lined up precisely for acceptable cosmesis. Irregularity of the vermilion border by as little as 1 mm may be noticed by an observer at speaking distance

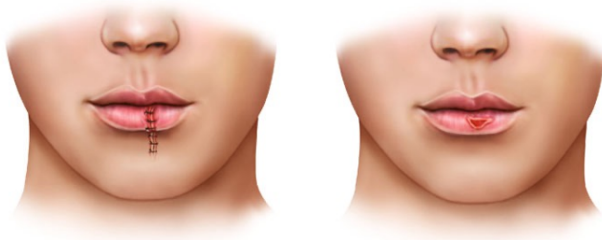

Figure 1:

As its name implies, the W-excision is a full-thickness resection in the shape of a “W.”^{8,9} The advantage of the W-excision over the V-excision is that it allows the vertical arms of the excision to be shorter to avoid crossing the labiomental crease, and thus can be used for wider lesions than the V-excision (Figure 2). As such, it is used primarily for lower lip lesions. Closure of the defect is in the same three-layered fashion as the V-excision; however, the wound is re-approximated in such a way as to convert the scar into an upside down “Y.”

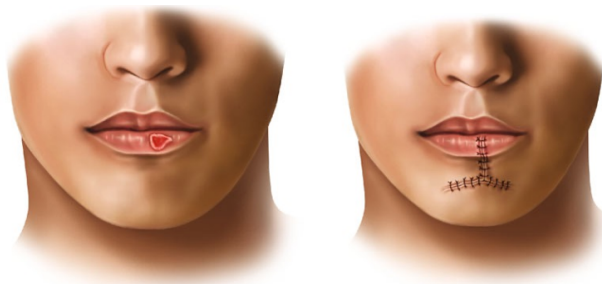


Figure 2:

The shield and pentagonal excisions are similar in shape with two vertical arms on either side of the lesion which then turn towards each other in a curvilinear or angular fashion, respectively.^{3,9} The apex lies at the labiomental crease of the lower lip or nasolabial crease of the upper lip.

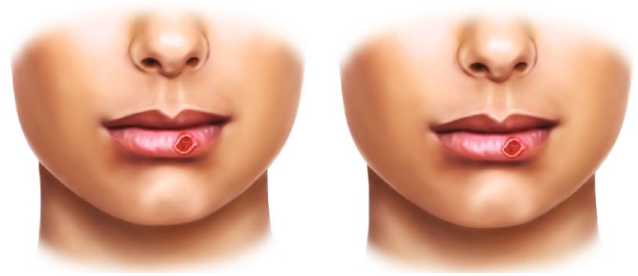


Figure 3:

3. Lateral (Rectangular) Advancement Flaps

Lateral (rectangular) advancement flaps are full-thickness flaps that are useful for reconstructing lower lip defects³. They are not ideal for the upper lip because they will distort the philtral columns and lip symmetry. To perform this technique, the lesion is excised full-thickness in a rectangular fashion. Horizontal full-thickness incisions are then made along the labiomental crease. Because of the elasticity of mucosa, the horizontal incisions do not need to be made as far laterally through the mucosa (full thickness) as they do for the skin and muscle (partial thickness). To aid in closure, partial-thickness Burow’s triangle excisions of skin and subcutaneous tissue are made at the ends of the horizontal incisions. The two flaps are advanced medially and closed primarily in three layers.

The T-excision is a rectangular advancement flap that is useful for the excision of a lesion of the central portion of the upper lip (philtrum).² The horizontal full-thickness incisions are made below the nasal base, and the lateral lip flaps are advanced medially. Further advancement can be obtained with crescentic perialar excisions of skin and subcutaneous tissue as described by Webster.^{2,5} This allows advancement of lip as well as cheek tissue.

4. Defects One-Third to Two-Thirds of the Lip

Moderately sized defects, measuring one-third to two-thirds of the lip, can be subdivided into those that involve one-third to one-half of the lip, and those that involve one-half to two-thirds of the lip.

4.1. One-third to two-third defects

4.1.1. Lip-switch flaps (Cross-Lip Flaps)

Lip-switch flaps use temporarily pedicled tissue from one lip to reconstruct a full-thickness defect of the opposite lip. The Abbe, Estlander, and Stein flaps are the three most commonly used versions of lip-switch flaps.³ These flaps are based on the labial artery in the vermilion of the donor lip.⁴ Venous drainage is provided by small veins that parallel the course of the artery.⁵ The Abbe and Stein flaps are two-stage flaps, in which the vascular pedicle must be divided once independent vascularity has been

established. While the pedicle is in place, the patient will have difficulty eating and must be careful not to disturb or traumatize this pedicle during the revascularization period. The pedicle is typically divided after 3 weeks from the first stage. This can be done in the office under local anesthesia. To test the viability of the flap before pedicle division, a piece of umbilical tape can be passed around the pedicle and twisted to occlude the blood supply. Immediate and profound blanching implies that adequate blood supply has not yet been developed and more time is needed before division. Once the pedicle is divided, the vermilion is inset on either lip.

Because lip-switch flaps involve the transfer of full-thickness lip tissue, there is restoration of the orbicularis oris muscle sphincter. While initially

paralyzed and paresthetic, studies have shown that the muscle and skin regain innervation and therefore have a good functional result.^{1,3,5,7}

All lip-switch flaps result in a smaller oral opening, but this is rarely a problem because they are rarely used for a defect of more than 30–50 % of the lip. Loss of 50 % of one lip only results in a 25 % decrease in the total oral circumference.³

The Abbe (Sabbattini) flap, first described by Sabbattini in 1836, and later by Abbe in 1898, involves the transfer of a triangular-shaped, full-thickness segment of one lip to the opposite lip.^{3–5,10} While the original description called for the transfer of lower lip tissue to reconstruct the upper lip, the Abbe flap can be used to reconstruct lower lip defects as well. Even so, they are most useful for reconstructing upper lip defects because tissue can be harvested from the lower lip without noticeably changing the symmetry of the donor lip.³ Using the upper lip as donor tissue creates asymmetry in the more esthetically noticeable upper lip and may even remove the philtral column and Cupid's bow.

The Abbe flap may be pedicled medially or laterally, except for when the defect involves the more lateral portion of the lip, in which case the pedicle is based medially.⁵ In all other circumstances, the location of the pedicle may be chosen to allow for easier flap transposition and inset. The height of the flap should equal the height of the defect and the axes should parallel the relaxed skin tension lines. The width of the base of the flap is usually made one-half of the width of the defect so that the sizes of the two lips remain proportionally similar after reconstruction. However, for upper lip defects that comprise an entire esthetic subunit, such as the philtrum or lateral segment, the donor flap width may equal the size of the defect to restore the complete esthetic subunit. Additionally, the shape of the flap may vary according to the shape of the defect it is reconstructing. Simple Abbe flaps are typically triangularly shaped but may be designed with a more complex geometry to reconstruct an entire esthetic subunit as described by Burget.⁶

Once the size and geometry of the Abbe flap are chosen and marked out, the donor flap is harvested by making full-thickness incisions, except in the area of the pedicle. Here, the incision stops at the vermilion border, preserving the labial artery. Care is taken to preserve enough pedicle tissue bulk to allow for venous drainage, but not too much tissue such that the pedicle is too bulky and complicates accurate re-approximation of the flap donor site. The labial artery courses in a plane between the labial mucosa and orbicularis oris muscle, at a level posterior to the vermilion border. Because of this, the skin incision used to create the flap may extend partial-thickness through the anterior portion of the lip vermilion, if necessary.

The Stein flap is essentially a double Abbe flap that uses two small symmetric flaps from the central upper lip to reconstruct the lower lip.^{3,5} It was modified by Kazanjian to preserve the philtrum by harvesting flaps from either side of the philtral columns. While it attempts to avoid upper lip asymmetry, the two flaps do create potentially obvious and unaesthetic scars. The Stein flap is more complicated than single lip-switch flaps and results in greater denervation of the reconstructed lip.

For these reasons, the Stein flap is generally less favored.

The Estlander flap is a type of lip-switch flap used to reconstruct pericommissural defects of the opposite lip. It is a one-stage procedure that involves the transfer of a full-thickness lip flap with a medially based pedicle containing the labial artery and can be used to reconstruct defects of one-half or more of the lip.^{5,7} Like the Abbe flap, the Estlander flap can be used for upper or lower lip defects. Full-thickness incisions are made with the apex located at the nasolabial or labiomental crease,

respectively. The medial incision extends to the vermilion border to preserve the medially based vermilion pedicle. The flap is then rotated and inset into the opposite lip defect, and the vermilion pedicle becomes the new lip commissure. Consequently, the Estlander flap always results in blunting or rounding of the commissure, which can be corrected later with a commissuroplasty.

Several different methods of commissuroplasty may be performed, but they typically involve making a full-thickness horizontal incision through the blunted commissure and then advancing buccal mucosal flaps superiorly, inferiorly, and laterally to restore the vermilion of the lateral-most lips and commissure.^{5,11} A small triangular excision of skin and subcutaneous tissue can be performed to help create a more fusiform shape to the commissure.

4.1.2. Johanson stair-step flap

The stair-step (staircase, stepladder) flap, described by Johanson and Isalsson, is a variation of the lateral advancement flap that can be used to reconstruct lower lip defects of up to two-thirds of the lip.^{2,12} It can be raised

as a unilateral flap, which is good for a lateral defect, or as bilateral flaps for a midline defect. The original description called for the full-thickness excision of the steps, but it is often possible to excise skin and subcutaneous tissue only, thereby preserving the orbicularis oris muscle and its blood supply and innervation. An additional advantage is that the incision is outside of the labiomental crease, preserving the esthetic subunit of the chin.

The Johanson flap begins with the lip lesion being resected in a full-thickness rectangular fashion.^{5,12} A full-thickness horizontal incision is then extended from the inferior defect margin in one or both directions for a unilateral or bilateral flap, respectively. Partial-thickness incisions are stair-stepped inferolaterally for a total of two to four steps. The steps are extended laterally 10 mm and inferiorly 8 mm. Partial-thickness rectangular excisions of skin and subcutaneous tissue are made below each step, and the skin flaps are undermined laterally. At the bottom of the staircase, a Burow's triangle is excised to permit smooth medial movement of the advancement flap.

Fernandes and Pirgousis recently described a modification of the Johanson flap that essentially combines the stepladder design with the curvilinear tissue excision of the Webster-Fries method for defects measuring one-third to two-thirds of the lip.¹³ The size of the defect is divided equally and shared by both semilunar excisions at the labiomental crease. Full-thickness lateral incisions through skin, muscle, and mucosa are made on either side of the defect to allow for medial advancement of the two flaps. The semilunar incisions are made through skin and subcutaneous tissue, which are excised to allow medial movement without puckering of the skin and place the scar at the labiomental crease. The mental neurovascular bundles are preserved, if encountered, to maintain neurosensory function. Because the orbicularis oris muscle is re-approximated and not denervated, good functional results are obtained.

4.2. Defects half to two-thirds of the lip

4.2.1. Karapandzic flap

In 1974, Karapandzic described a modification of the circumoral composite rotation advancement lip flap, which has largely replaced the Gillies and McGregor flaps (described later).^{5,14} The Karapandzic flap can be used for upper or lower lip defects, and unilateral or bilateral flaps can be raised depending on the defect size. Unilateral flaps are adequate for small defects up to 50 % of the lip, whereas bilateral flaps can be used to reconstruct defects up to 80 % of the lip.^{2,15} The flaps are designed by making partial-thickness incisions through skin and subcutaneous tissue paralleling the lip margin at a distance equal to the depth of the defect. Muscle and mucosa are then divided as needed for sufficient flap movement. Branches of the facial artery as well as motor and sensory nerves going to

the flap are carefully dissected and preserved. The flap(s) is advanced medially and closed primary in three layers. Function is restored because the flap is never denervated, only the peripheral rim of orbicularis oris muscle is incised, and the buccinator muscle is preserved. Because of its good functional and acceptable esthetic results, the Karapandzic flap is arguably the flap of choice for large lip defects. The Karapandzic flap will result in rounding of the commissure, which can later be addressed with a commissuroplasty, if necessary.

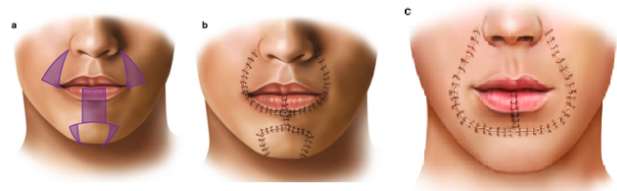

Figure 4: a: Karapandzic flap. Excision and flap design are marked. The incision is carried along the labiomental crease and then turns superiorly to follow the nasolabial creases; b: The flaps are raised by initially making partial-thickness incisions through skin and subcutaneous tissue, and then dividing muscle and mucosa as needed to gain mobility; c: Resulting reconstruction.

5. Webster-Modified Bernard Flap

The Webster-modified Bernard flap (Webster-Fries flap) is a useful procedure that can be

employed to reconstruct total or near-total lip defects of the upper or lower lip by utilizing bilateral cheek advancement flaps.^{5,15} Two horizontal full-thickness incisions are made, with one at the level of the commissure, and the second at the level of the resection margin. Partial-thickness crescent triangles are then excised from the upper and lower cheeks to allow medial advancement of the flaps. The resulting scars lie in the nasolabial and labiomental folds, and resemble a “jumping man” stick figure. The flap can also be used as a unilateral flap for defects one-third to one-half of the lip. Another variation of this flap can be performed without the excision of triangles from the lower cheeks, and instead a W-wedge excision of the lower lip can be made and closed primarily. The advantages of the Webster-modified Bernard flap are that it provides sensate skin, innervated muscle, and mucosal coverage, and the scars are placed in the esthetic subunit borders.

6. Webster's Combination Flap

In 1954, Webster described a variation of a flap first described by Blasius in 1840 to reconstruct lesions greater than three-quarters of the upper lip.⁶ Webster's combination flap uses bilateral cheek advancement flaps with perialar crescent excisions and an Abbe lip-switch flap from the lower lip. The lateral advancement flaps reconstruct

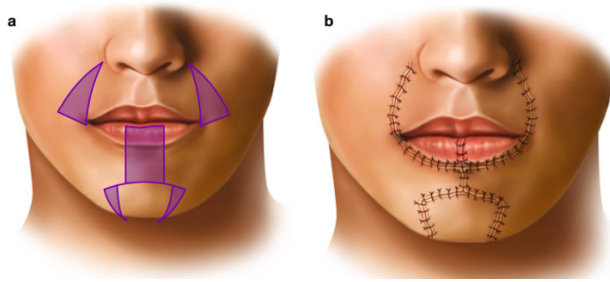


Figure 5: a: Webster-Bernard (Webster-Fries) flap. Excision and flap design are marked; **b:** Final reconstruction.

the lateral segments of the upper lip and the Abbe flap reconstructs the philtrum.

6.1. Gillies “Fan” flap

The Gillies “fan” flap is a full-thickness flap that moves lip and cheek tissue around the corner of the mouth to reconstruct a lateral defect of the upper or lower lip.^{3,5} Its movement around the commissure is similar to that of the old-fashioned collapsible handheld fans, and thus it gets its name. The flap is raised by making a full-thickness incision that begins laterally, turns vertically, and then turns back towards the opposite lip. The flap is then rotated around the commissure, displacing it as well as the modiolus onto the opposite lip. The flap is supplied by the labial artery and carries its own neural innervation; however, the vertical incision results in at least some denervation. Like the Estlander flap, the Gillies flap blunts the commissure by moving tissue around the corner of the mouth, but it mobilizes more cheek tissue into the defect. Total or near-total lip defects can be reconstructed with bilateral Gillies flaps. Because of the partial denervation that occurs with the Gillies flap, which can worsen oral competence, it is not the first choice for lip reconstruction.

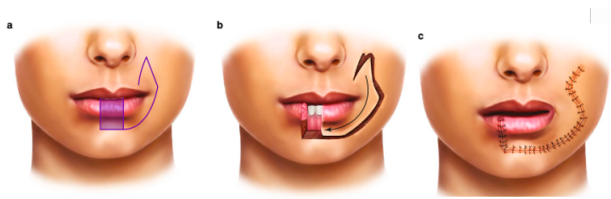


Figure 6: a: Gillies fan flap. A curvilinear incision is extended laterally and then superiorly to follow the nasolabial fold; **b:** A full-thickness flap is then raised and rotated medially to bring lip and cheek tissue to the defect; **c:** Because the Gillies flap rotates tissue around the corner of the mouth, it will result in blunting of the oral commissure

6.2. McGregor flap

The McGregor flap is similar to the Gillies flap but involves the transfer of tissue to a defect of the upper lip. It is a

composite flap created by full-thickness incisions. While it adds additional cutaneous tissue around the mouth, it fails to restore a natural vermilion. A mucosal advancement flap from the posterior surface of the flap may be available for advancement over the exposed border of the flap to restore the vermilion defect.⁵ A Z-plasty incision along the lateral margin of the flap may be used to assist in making the circumoral flap advancement.

7. Defects Greater Than Two-Thirds of the Lip

As discussed earlier, large defects of the lip can be reconstructed with bilateral Gillies, McGregor, or Karapandzic flaps, although the Karapandzic flap is usually the preferred choice.

7.1. Free flaps

Whenever possible, it is preferable to use local tissue to reconstruct lip defects because they provide the closest match in terms of skin colour, texture, thickness, and even functioning muscle.^{16,17} However, when the size of the defect reaches near-total or total lip length, microvascular free tissue transfer should be strongly considered.

8. Conclusion

In planning a lip reconstruction, all aspects of flap design must be considered as they impact the ultimate aesthetic and functional outcome. A dynamic reconstruction with remaining lip tissue can provide superior results in terms of lip appearance and function in smaller lip defects. Reconstruction of large-scale defects often requires free-tissue transfer that provides static support of the lip. Further refinements in free-flap design are needed to provide dynamic reconstructions that re-create the function of the lip and preserve oral competence.

9. Source of Funding

None.

10. Conflict of Interest

None.

References

1. Langstein HN, Robb GL. Lip and perioral reconstruction. *Clin Plast Surg.* 2005;32(3):431–45.
2. Neligan PC. Strategies in lip reconstruction. *Clin Plast Surg.* 2009;36(3):477–85.
3. Calhoun KH. Reconstruction of small- and medium-sized defects of the lower lip. *Am J Otolaryngol.* 1992;13(1):16–22.
4. Carlson ER, Guerra A. Lip cancer - ablative and reconstructive surgery. In: Current therapy in oral and maxillofacial surgery. St. Louis: Elsevier; 2012.

5. Renner G. Reconstruction of the lip. In: Baker S (ed) Local flaps in facial reconstruction. Philadelphia: Elsevier; 2007.
6. Dupin C, Metzinger S, Rizzuto R. Lip reconstruction after ablation for skin malignancies. *Clin Plast Surg*. 2004;31(1):69–85.
7. Sikes JW, Ghali GE. Lip cancer. In: Peterson's principles of oral and maxillofacial surgery. Hamilton: BC Decker Inc; 2012.
8. Hasson O. Squamous cell carcinoma of the lower lip. *J Oral Maxillofac Surg*. 2008;66(6):1259–62.
9. Huang CC, Arpey CJ. The lips: excision and repair. *Dermatol Clin*. 1998;16(1):127–43.
10. Ferris RL, Gillman GS. Cancer of the lip. In: Operative otolaryngology, head and neck surgery, 2nd edn. Philadelphia: Saunders Elsevier; 2008.
11. Koymen R, Gulses A, Karacayli U, Aydintug YS. Treatment of microstomia with commissuroplasties and semidynamic acrylic splints. *Oral Surg Oral Med Oral Pathol Oral Radiol Endod*. 2009;107(4):503–7.
12. Salgarelli AC, Persia M, Ciancio P, Pagani R. The staircase technique for treatment of cancer of the lower lip: a report of 36 cases. *J Oral Maxillofac Surg*. 2001;59(4):399–402.
13. Pargousis P, Fernandes R. Reconstruction of sub-total defects of the lower lip: a review of current techniques and a proposed modification. *J Oral Maxillofac Surg*. 2011;69(1):295–9.
14. Karapandzic M. Reconstruction of lip defects by local arterial flaps. *Br J Plast Surg*. 1974;27(1):93–7.
15. Closmann JJ, Pogrel MA, Schmidt BL. Reconstruction of perioral defects following resection for oral squamous cell carcinoma. *J Oral Maxillofac Surg*. 2006;64(3):367–74.
16. Levis C, Hynes N, Archibald S. Through and through defects of the lower face. *Clin Plast Surg*. 2005;32(3):327–37.
17. Odell MJ, Varvares MA. Microvascular reconstruction of major lip defects. *Facial Plast Surg Clin North Am*. 2009;17(2):203–9.

Author biography

Rohit Narendra Rathod, Fellow

Bikash Kumar Bal, Fellow

Cite this article: Rathod RN, Bal BK. Modalities of lip reconstruction in facial surgery- A literature review. *IP Indian J Anat Surg Head, Neck Brain* 2023;9(4):117-122.