

Content available at: <https://www.ipinnovative.com/open-access-journals>

IP Indian Journal of Anatomy and Surgery of Head, Neck and Brain

Journal homepage: <https://www.ijashnb.org/>

Case Report

Ridge split technique and implant placement- A case report

Sunil Kumar Singh¹, Ashish Kamboj^{2*}, Chandni Ghildiyal³, SS Chopra⁴, Paras Angrish⁵

¹Dept. of Oral & Maxillofacial Surgery, 8 Airforce Dental Centre, Kanpur, Uttar Pradesh, India

²Military Dental Centre, Delhi Cantt, New Delhi, India

³Rama Dental College Hospital & Research Centre, Kanpur, Uttar Pradesh, India

⁴Dept. of Orthodontics, Army Dental Centre (R&R), Delhi Cantt, New Delhi, India

⁵Govt. Dental Centre, Tangtse (UT of Ladakh), Jammu & Kashmir, India



ARTICLE INFO

Article history:

Received 18-04-2024

Accepted 04-05-2024

Available online 07-05-2024

Keywords:

Ridgesplit

Ridge augmentation

Implant therapy

ABSTRACT

Background: One of the key obstacles to successful implant placement is insufficient alveolar ridge width. To create a functional restoration that blends well with the surrounding natural dentition, augmenting inadequate alveolar ridges is a crucial component of dental implant therapy. Ridge-splitting techniques are used for the narrow edentulous ridge for implant placement with predictable outcomes in the maxilla than in the mandible.

This case report describes a young female patient who underwent horizontal ridge augmentation using the ridge split technique in the esthetic maxillary central incisor area. This technique was used along with demineralized freeze-dried bone allograft with membrane for the implant placement.

Conclusion: While this surgical method can be used for either jaw, it is most appropriate for the maxilla. Augmenting inadequate alveolar ridges is therefore a crucial part of dental implant therapy to meet the ideal goals of implant dentistry, with the ultimate goal being the provision of a functional restoration that blends in harmoniously with the surrounding natural teeth.

This is an Open Access (OA) journal, and articles are distributed under the terms of the [Creative Commons Attribution-NonCommercial-ShareAlike 4.0 License](https://creativecommons.org/licenses/by-nc-sa/4.0/), which allows others to remix, tweak, and build upon the work non-commercially, as long as appropriate credit is given and the new creations are licensed under the identical terms.

For reprints contact: reprint@ipinnovative.com

1. Introduction

One of the key obstacle to a successful implant placement is insufficient alveolar ridge width.

Therefore, optimal volume and quality of both hard and soft tissues must be present to meet the ideal goals of implant dentistry.¹ After tooth extraction or trauma, the labial cortical plates in the aesthetic anterior regions are often thinner than the lingual plate and are the first to be lost or resorbed. Following natural tooth loss, the labial alveolar bone frequently regenerates quickly. During the first year, there is a 25% decrease in volume, and during the next

three years, there is a 40–60% decrease in breadth. This causes the labial cortex of the bone to shift medially relative to its initial position.² To create a functional restoration that blends well with the surrounding natural dentition, augmenting inadequate alveolar ridges is therefore a crucial component of dental implant therapy.

Ridge deficits might be vertical, horizontal, or a combination of the two. Alveolar ridge splitting or extension, distraction osteogenesis, autogenous or allograft block graft, and guided bone regeneration can all be used alone or in combination to predictably increase the amount of ridge in locations of the alveolar ridge that are insufficient.³ In order to augment the horizontal ridge while preserving the periosteal connection, the ridge split or ridge

* Corresponding author.

E-mail address: drashishorthodontics@gmail.com (A. Kamboj).

expansion technique was first presented in the early 1970s. It involved meticulously enlarging the cortical plates.

Ridge splitting techniques are used for the narrow edentulous ridge for implant placement with predictable outcome in maxilla than in mandible.⁴ In this case report, we describe a case of horizontal ridge augmentation using ridge split and implant placement in esthetic maxillary central incisor area.

2. Case Report

A 16 years old female reported to the outpatient department with the chief complaint of missing upper left teeth for last 1 year due to tooth avulsion caused by trauma. On intraoral examination, ridge deficiency was noticed. The patient was well built with no medical history. Preoperative measures included a standard orthopantomogram, oral prophylaxis, and routine blood test. A thorough case history was also taken. Ridge split procedure was planned in order to achieve adequate ridge width to facilitate implant placement. The treatment plan was explained to the patient, and written consent was obtained.

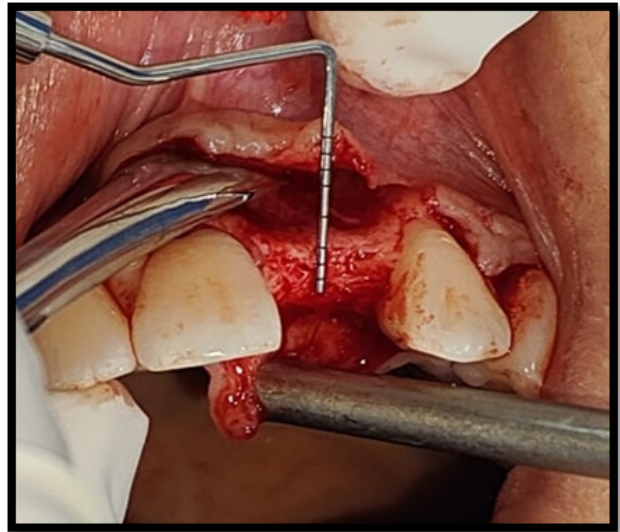


Figure 2: Bucco-lingual width deficiency measured

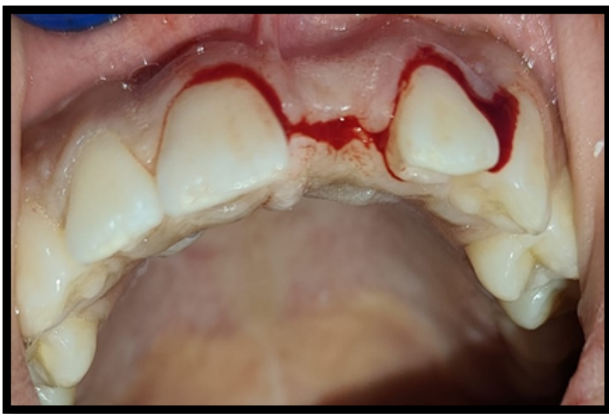

Figure 1: Mid-crestal incision given

2.1. Surgical procedure

2% lignocaine was administered on the site. A 15 no. blade was used for incision. An incision was made midcrestally. [Figure 1] The crest of the ridge was exposed by raising the full thickness flap. Bucco-lingual width was measured. [Figure 2] A handpiece was used for sequential osteotomies for expansion. Osteotomy site was prepared. Crestal osteotomy was done with piezo surgery tip. [Figure 3] The osteotome was used for ridge split. [Figure 4] Site was first prepared to a length that was about 3 mm deeper than the intended implant length of 11 mm. This was done by inserting a larger osteotome that was 0.5 mm shorter than the one before it, which allowed the bone's base to extend into a V shape. Implant

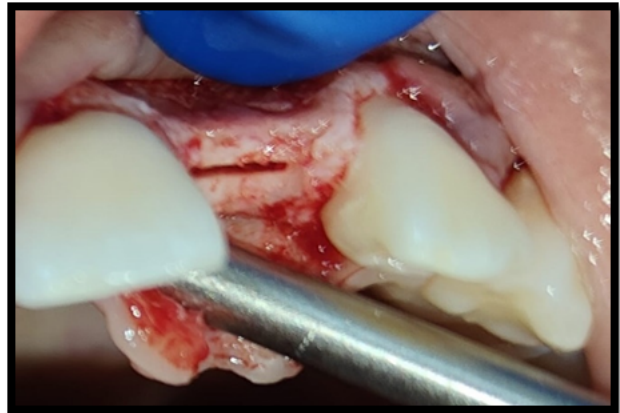


Figure 3: Crestal osteotomy done with piezo surgery tip

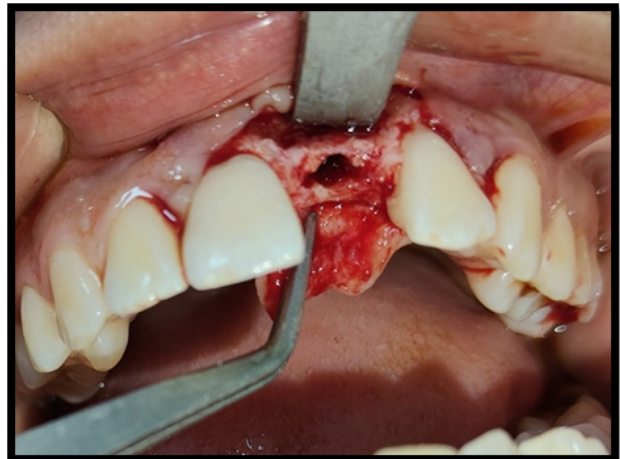


Figure 4: Ridge split done with osteotome

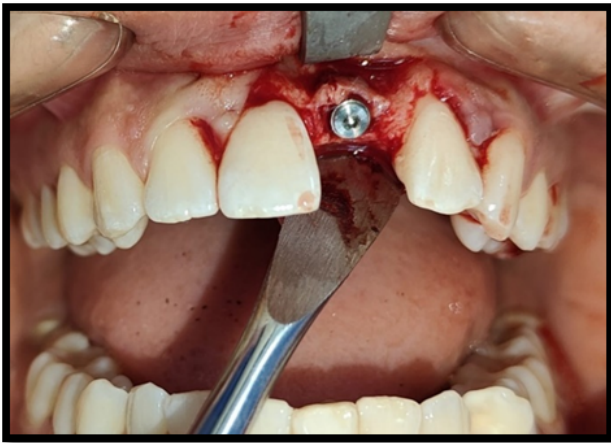


Figure 5: Implant placed

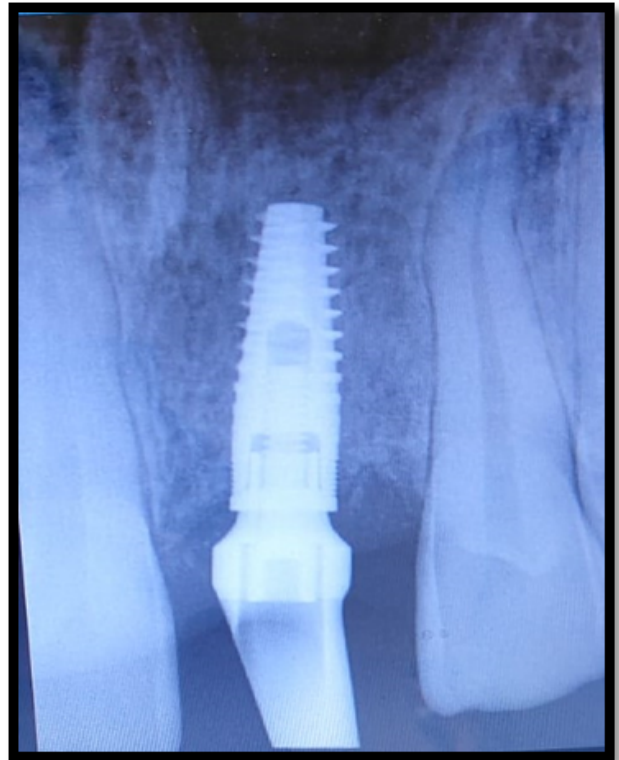

Figure 8: IOPA taken

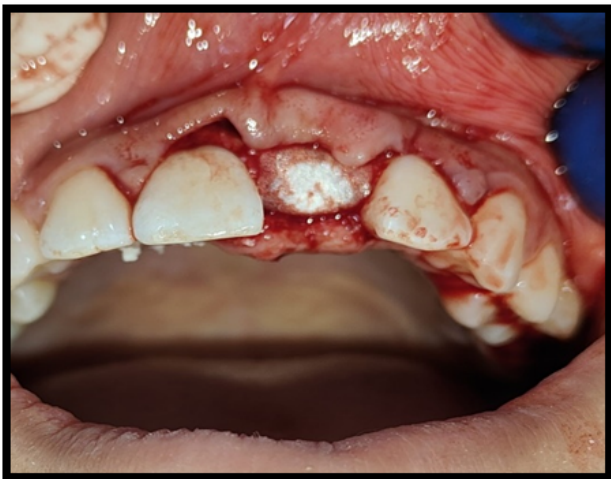

Figure 6: Demineralized freeze-dried bone graft in space of bone spread with a membrane placed

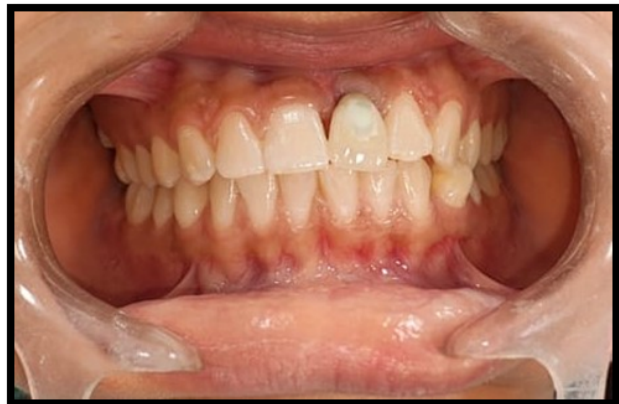

Figure 9: Full Ceramic crown given

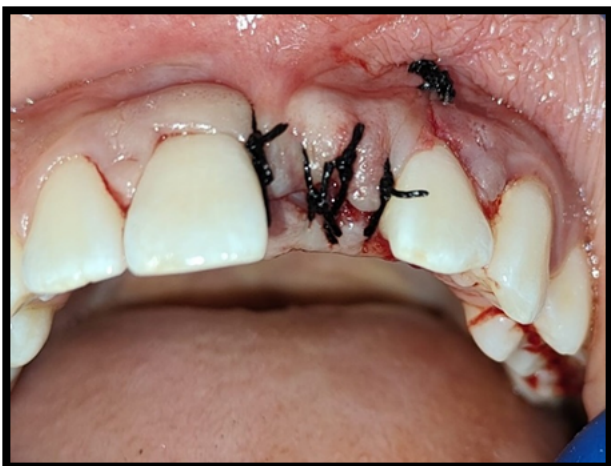

Figure 7: Sutures placed

was placed. [Figure 5] Demineralized freeze-dried bone allograft with membrane was placed after placing the cover screw [Figure 6] Suture was given. [Figure 7] Post operative IOPA was taken [Figure 8] and postoperative instructions were advised to the patient] Antibiotics and analgesics were prescribed with chlorhexidine mouth wash 0.2% for 5 days. After 7 days, sutures were taken out. The patient underwent prosthetic rehabilitation with complete ceramic crowns after receiving periodic reviews for six months. [Figure 9]

3. Discussion

Bucco-palatal bone is frequently only 4-6 mm broad at the crest with or without a "hourglass" facial deformity, so augmenting inadequate alveolar ridges is necessary in the implant treatment plan to lessen stress at the crestal bone region.^{3,5} Therefore, ridge restoration before to implant insertion is often necessary for a better knowledge of the biomechanical requirements for long-term prosthesis life.

A minimum of 6 mm of ridge width is required for a favourable result, meaning that the implant must have at least 1 to 1.5 mm of bone surrounding it.⁶ Dr. Hilt Tatum 1970s introduced a method of ridge splitting or bone spreading using specific instruments like D-shaped graduated osteotomes/wedges and tapered channel formers. He inserted >5000 maxillary anterior implants using ridge splitting before 1985 wherein, he expanded atrophic ridges >3 mm for simultaneous implant placement and augmentation keeping the periosteum intact.⁷ The ridge's viscoelastic nature increases and its elastic modulus decreases with the quality of the trabecular bone. Consequently, bone expansion is easier and more predictable the less dense the bone.^{8,9} Bone expansion gives the area a more typical facial contour. The palatal and facial plates are not affected by bone splitting in the same way because the palatal bone is bigger and more difficult to work with. As a result, the expansion process mostly affects the thinner facial plate. With a surgical mallet, controlled sequential gentle tapping (about 1 mm for each tap) is utilised to gradually expand the osteotomy once the bone is prepared 2–4 mm deeper than the eventual implant length.

The bone spreading osteotome is unscrewed with a mild axial tensile force after being rotated in the socket. The clinician determines whether to choose an implant with a 3.5 or 4 mm diameter based on the osteotome's 3 mm diameter and the amount of bone present in the facial area. A larger osteotome is inserted 0.5 mm shorter than the previous instrument after the initial length of the osteotome, which is 3 mm deeper than the intended implant length. This causes the base of the bone to extend in a V form rather than a U shape. The labial tissue should be felt while preparation of the site with osteotome and during implant insertion.^{7,8} A physio-dispenser hand piece with high torque and moderate speed is used to thread the final implant into place. In order to reduce the danger of crestal bone loss and promote bone remodelling, bone grafts can be positioned in the area between the implant and the bone as well as at the crestal region using membrane.¹⁰

4. Conclusion

There are various techniques for ridge augmentation of alveolar ridges that are inadequate for implant insertion; in situations where ridge width is greater than 3.5 mm, ridge splitting or spreading is recommended. The main criteria for success of ridge split cases is patient selection and bone

evaluation. While this surgical method can be used to either jaw, it is most appropriate for the maxilla. Augmenting inadequate alveolar ridges is therefore a crucial part of dental implant therapy in order to meet the ideal goals of implant dentistry, with the ultimate goal being the provision of a functional restoration that blends in harmoniously with the surrounding natural teeth, as demonstrated in the case report.

5. Source of Funding

None.

6. Conflict of Interest


None.

References

- Sethi A, Kaus T. Maxillary ridge expansion with simultaneous implant placement: 5-year results of an ongoing clinical study. *Int J Oral Maxillofac Implants*. 2000;15(4):491–9.
- Scipioni A, Bruschi GB, Calesini G. The edentulous ridge expansion technique: a five-year study. *Int J Periodontics Restorative Dent*. 1994;14(5):451–9.
- Lieberman JR, Friedlander GE. Bone Regeneration and Repair. 1st Edn. Totowa, NJ: Humana Press; 2005. p. 195–6.
- Summers RB. The osteotome technique: Part 4—Future site development. *Compend Contin Educ Dent*. 1995;16(11):1090–2.
- Misch CE. Density of bone: effect on treatment plans, surgical approach, healing, and progressive bone loading. *Int J Oral Implantol*. 1990;6(2):23–31.
- Tatum H. Maxillary and sinus implant reconstructions. *Dent Clin North Am*. 1986;30(2):207–29.
- Scipioni A, Bruschi GB, Giargia M, Berglundh T, Lindhe J. Healing at implants with and without primary bone contact. An experimental study in dogs. *Clin Oral Implants Res*. 1997;8(1):39–47.
- Summers RB. A new concept in maxillary implant surgery: the osteotome technique. *Compendium*. 1994;15(2):152–6.
- Misch CF. Contemporary Implant Dentistry. 2nd Edn. St. Louis, Missouri: Mosby; p. 3–11.
- Belser UC, Buser D, Hess D, Schmid B, Bernard JP, Lang NP, et al. Aesthetic implant restorations in partially edentulous patients - A critical appraisal. *Periodontol*. 1998;17:132–50. doi:10.1111/j.1600-0757.1998.tb00131.x.


Author biography

Sunil Kumar Singh, Oral & Maxillofacial Surgeon

Ashish Kamboj, Orthodontist  <https://orcid.org/0000-0002-1836-6786>

Chandni Ghildiyal, Post Graduate Student

SS Chopra, Professor and HOD

Paras Angrish, Pedodontist  <https://orcid.org/0000-0003-0721-0353>

Cite this article: Singh SK, Kamboj A, Ghildiyal C, Chopra SS, Angrish P. Ridge split technique and implant placement- A case report. *IP Indian J Anat Surg Head, Neck Brain* 2024;10(1):25-28.