

## Basilar artery aneurysm- A case report

Sathia Lakshmi V<sup>1,\*</sup>, Rajesh Ranjan<sup>2</sup>, Sujatha. N<sup>3</sup>, Swayam Jothi. S.<sup>4</sup>

<sup>1,4</sup>Professor, <sup>3</sup>Phd Student, Dept. of Anatomy, Shri Sathya Sai Medical College & Research Institute, Tamil Nadu, <sup>2</sup>Associate Professor, Government Medical College, Patna

**\*Corresponding Author:**

**Sathia Lakshmi V**

Professor, Dept. of Anatomy, Shri Sathya Sai Medical College & Research Institute, Tamil Nadu

Email: drsathyalakshmi@gmail.com

### Abstract

A case report of Basilar artery aneurysm identified in the outpatient department of SSSMC & RI. This case presentation is to bring to light that simple symptoms like head ache and neck pain cannot be taken light as they may lead to big catastrophes and also to share the knowledge of modern advancement in technology treating such cases.

A 60yrs old lady attended ortho -OP with the complaints of severe head ache followed by neck pain .Since the patient happened to be a doctor anticipated it to be cervical spondylitis. Later the neck pain turned out to be neck rigidity and she was referred for investigation to rule out cerebro-vascular accident. CT scan of brain revealed a Berry aneurysm of Basilar artery tip near its bifurcation with mild subarachnoid haemorrhage. Except for the pain, patient did not complain of anything else. MRI and angiographic studies were carried out. It confirmed the diagnosis.

Later patient was hospitalized for interventional therapy. She was on treatment for hypertension Coil embolisation was done and after 5days patient was discharged without any sequelae.

**Key words:** Basilar artery, Embolism, Coil Embolisation

### Introduction

An aneurysm is a localized, blood-filled balloon-like bulge in the wall of a blood vessel. As an aneurysm increases in size, the risk of rupture increases.<sup>(1)</sup> A ruptured aneurysm can lead to bleeding and subsequently, leading to death. Aneurysms are a result of a weakened blood vessel wall, and can be a result of a hereditary condition or an acquired disease. Aneurysms can also be a nidus for clot formation and embolization. Aneurysms may be classified as true and false aneurysm, A true aneurysm is one that involves all three layers of the wall of an artery (intima, media and adventitia).

A false aneurysm, or pseudo aneurysm, is a collection of blood leaking completely out of an artery or vein, but confined next to the vessel by the surrounding tissue. This blood-filled cavity will eventually either clot enough to seal the leak, or rupture out of the surrounding tissue.<sup>(2)</sup>

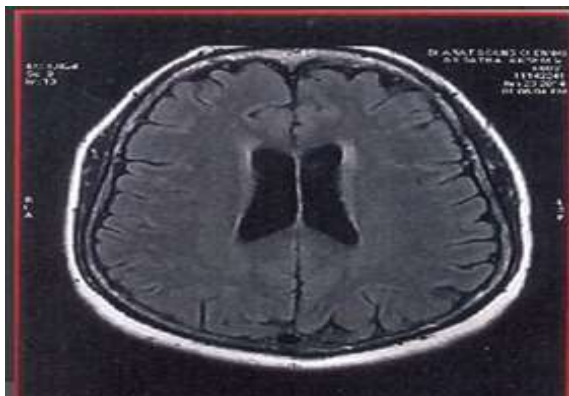
Aneurysms can also be classified by their macroscopic shape and size, and are described as either saccular or fusiform. The shape of an aneurysm is not specific for a specific disease.<sup>(2)</sup>

Aneurysms can also be classified by their location:

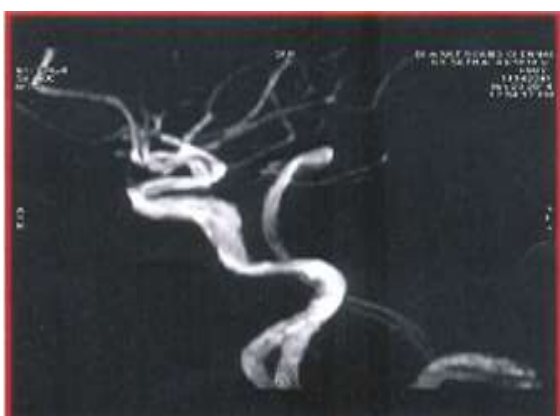- Arterial and venous, with arterial being more common.
- The heart, including coronary artery aneurysms, ventricular aneurysms, aneurysm of sinus of Valsalva, and aneurysms following cardiac surgery.
- The aorta, namely aortic aneurysms including thoracic aortic aneurysms and abdominal aortic aneurysms.

- The brain, including cerebral aneurysms, berry aneurysms, and Charcot–Bouchard aneurysms.
- The legs, including the popliteal arteries.
- The kidney, including renal artery aneurysm and intraparenchymal aneurysms<sup>(3)</sup>
- Capillaries, specifically capillary aneurysms.

Cerebral aneurysms, also known as intracranial or brain aneurysms occur most commonly in the anterior cerebral artery, which is part of the circle of Willis. This can cause severe strokes leading to death. The next most common sites of cerebral aneurysm occurrence are in the internal carotid artery 60 year old lady presented with complaints of sudden and severe headache and also neck pain. Patient referred to ortho out patient. On Examination no history of vomiting, fever, trauma, weakness or numbness over limbs. Known case Diabetes Mellitus on treatment since 10 years, Known case of hypertension on treatment since 15 years, No history of tuberculosis, back ach, coronary artery disease. On Examination neck rigidity was found, no other neurological signs noticed, CT Morphology suggestive of Acute subarachnoid hemorrhage & focal parenchymal haemorrhage right temporal lobe, MRI Brain with Angiogram, Punctuate T2/ Flair hyper intensities in bilateral frontal white matter not restricted in diffusion – small vessel ischaemic changes, Small T2/ Flair hypointensity in Right temporal cortex possibility of haemorrhage, Age related cerebral atrophic changes, MRA study of the brain shows Basilar tip Aneurysm.



**Fig 1: Transverse section of brain showing two lateral ventricles**



**Fig 2: Basilar artery showing embolism**

### Discussion

A brain aneurysm, also referred to as a cerebral aneurysm or intracranial aneurysm, is a weak bulging spot on the wall of a brain artery very much like a thin balloon or weak spot on an inner tube. Over time, the blood flow within the artery pounds against the thinned portion of the wall and aneurysms form silently from wear and tear on the arteries. As the artery wall becomes gradually thinner from the dilation, the blood flow causes the weakened wall to swell outward. This pressure may cause the aneurysm to rupture and allow blood to escape into the space around the brain. A ruptured brain aneurysm commonly requires advanced surgical treatment.

Aneurysms can be because because of acquired disease or hereditary factors. The repeated trauma of blood flow against the vessel wall presses against the point of weakness and causes the aneurysm to enlarge.<sup>(11)</sup> As described by the Law of Young-Laplace, the increasing area increases tension against the aneurysmal walls, leading to enlargement

### Treatment

Two common methods are used to repair an aneurysm:

- Clipping is done during open brain surgery (craniotomy).
- Endovascular repair is most often done. It usually involves a "coil" or coiling. This is a less invasive way to treat some aneurysms.

Not all aneurysms need to be treated. Those that are less than 3 mm are less likely to break open so no treatment. Even if there are no symptoms, treatment necessary to prevent a future, possibly fatal, rupture.

Coil embolization is an alternative to surgery. This treatment has been offered at Toronto Western Hospital since 1992. This is done in the Neuroangiography suite under fluoroscopy

The Neuro interventional radiologist will make a small incision in the groin through which a tiny catheter is guided through the femoral artery into the brain vessels. The catheter is carefully guided into the aneurysm. Soft platinum coils are deposited through the microcatheter into the aneurysm. When in position, the coil is released by an application of a very low voltage current causing the coil to detach from the pusher wire. The softness of the platinum allows the coil to conform to the often irregular shape of an aneurysm. Averages of 5-6 coils are required to completely pack an aneurysm. The goal of this treatment is to prevent blood flow into the aneurysm sac by filling the aneurysm with coils and thrombus. This should prevent aneurysm bleeding or re-bleeding. Embolization does not repair areas of the brain already injured.

### Conclusion

This paper was presented mainly to bring into light the recent advances in modern technique of treating cerebral aneurysms by coil embolisation. This procedure is available even in India. And also to emphasize not to neglect symptoms like head ache & neck pain.

### References

1. Cronenwett, JL; Murphy, TF; Zelenock, GB; Whitehouse WM, Jr; Lindenaauer, SM; Graham, LM; Quint, LE; Silver, TM; Stanley, JC (September 1985). "Actuarial analysis of variables associated with rupture of small abdominal aortic aneurysms". *Surgery* 98(3):472–83. PMID 3898453.
2. Kumar, Vinay, ed. (2007). *Robbins basic pathology*(8th ed.). Philadelphia: Saunders/Elsevier. ISBN 978-1-4160-2973-1.
3. A Cough Deteriorating Gross Hematuria: A Clinical Sign of a Forthcoming Life-Threatening Rupture of an Intraparenchymal Aneurysm of Renal Artery (Wunderlichs Syndrome)". *Case Reports in Vascular Medicine* 2013: 1–3.doi:10.1155/2013/452317.