

## “Comparative study on Start oral intake after tonsillectomy by pretonsillectomy peritonsillar infiltration various agents”

Shamendra Kumar Meena<sup>1\*</sup>, Raj Kumar Jain<sup>2</sup>, Vijay Kumar Meena<sup>3</sup>, Deepti Ramchandra Meena<sup>4</sup>

<sup>1</sup>Medical Officer, <sup>2</sup>Professor and Head, <sup>3</sup>Associate Professor, <sup>4</sup>Ras Officer, Government Medical College, Kota, Rajasthan

**\*Corresponding Author:**

E-mail: shamendra.meena82@gmail.com

---

### Abstract

The time of oral intake depends on pain which occurs after tonsillectomy. Oral intake starts early if analgesics injected in peritonsillar space preoperatively. This time depends upon efficacy of analgesic drugs if analgesic effect good, oral intake starts earlier and if it is less then duration is more. Preincisional infiltrations of various agents are effective method to reduce post-tonsillectomy pain. This method also effective for earlier start of oral feeding and discharge from the hospital. We recommend the routine use of pre incisional peritonsillar infiltration of various agents in all tonsillectomy cases, irrespective of the age of the patient to reduce the post-tonsillectomy pain and other morbidities.

**Keywords:** Feeding, Oral intake, Peritonsillar infiltration, Tonsillectomy.

---

### Introduction

Pain is a highly unpleasant sensory and emotional experience and postoperative pain control in children is a big challenge for their inability to express and react. In the past two decades, there has been a considerable progress in the understanding of children's perception of pain and responses to pain and various pharmacological agents and analgesic delivery to avoid under treatment of pain in children.

A parallel noteworthy advancement has occurred in the knowledge of anatomy, physiology and pharmacology of regional anesthetic techniques. Some of these techniques are now an integral part of perioperative and procedure- related pain management in all ages, in part because of a greater concern about postoperative pain management in patients and in part because of technical advances in equipment to perform the blocks.

Tonsillectomy is a very common day care procedure that is associated with significant postoperative pain. This pain has traditionally been treated with opioid analgesics and non-steroidal anti-inflammatory drugs: however, these agents are associated with increased risks to respiratory depression and postoperative bleeding.

### Aims & Objectives

1. To Provide Post Tonsillectomy Analgesia to patients.
2. To evaluate the post-operative analgesic efficacy of pre incisional peritonsillar (PT) infiltration using various agents.
3. To evaluate the effect of various agents infiltration on start of oral intake and discharge from the hospital after tonsillectomy.
4. To investigate the possibility of any complication in relation to drugs infiltration into the peritonsillar Fossa.

**Anatomy and Physiology Embryology:** Pharyngeal Grooves and Pouches and Their Derivatives. The lateral walls and floor of the cranial part of the early foregut become much altered by the development of the pharyngeal pouches in this region. These pouches first appear as grooves which extend ventrally across, or towards, the middle line. In their later development, however, they become greatly modified to give origin to a number of diverse structures. These include the tympanic (middle ear) cavity, the parathyroid glands, tonsils and the thymus.

**The Second Pharyngeal Endodermal Pouch:** This lies between the second and the third pharyngeal arches and is obliterated ventrally by the development of the tongue. The lateral portion persists as the second pharyngeal pouch. The dorsal portion of this pouch possibly contributes to the corresponding tubotympanic recess. The ventral portion of the pouch soon loses its contact with the ectoderm and is almost completely obliterated by the proliferation of its endodermal lining, only a small portion possibly persisting as a small recess, the tonsillar Fossa. The endodermal proliferation is later invaded by mesodermal tissue and the two together constitute the primordium of the tonsil.

The endoderm of the second pouch proliferates and grows into the underlying mesenchyme. The central parts of these buds break down, forming crypts (pit-like depressions). The pouch endoderm forms the surface epithelium and lining of the tonsillar crypts. At about 20 weeks the mesenchyme around the crypts differentiates into lymphoid tissue, which soon organizes into the lymphatic nodules of the palatine tonsil.

During the third and fifth months, the tonsil is infiltrated by lymphatic tissue. Lymphocytes collect in relation to the tonsillar stroma beneath the epithelium. It is not certain whether these lymphocytes differentiate in

situ or are derived from blood (possibly, they come to the tonsil from the liver as lymphoblasts).

Similar aggregations are found in the first pouch (tubal tonsil), on the dorsum of the tongue (lingual tonsil) and in the dorsal pharyngeal wall (adenoids). The occurrence of the last two shows that lymphatic aggregations are not specifically related to the pharyngeal pouches.

Palatine tonsils are two in number. Each tonsil is an ovoid collection of lymphoid tissue situated in the lateral wall of oropharynx between the anterior and posterior pillars. A tonsil presents two surfaces- a medial and a lateral, and two poles- an upper and a lower.

**Bed of Tonsil:** It is formed by the superior constrictor and styloglossus muscles. The glossopharyngeal nerve and styloid process. Both these structures can be surgically approached through the tonsil bed after tonsillectomy. Outside the superior constrictor, tonsil is related to the facial artery, submandibular salivary gland, and posterior belly of digastric muscle, medial pterygoid muscle and the angle of mandible.

#### **Blood Supply:**

The tonsil is supplied by five arteries

1. Tonsillar branch of facial artery. This is the main artery.
2. Ascending pharyngeal artery from external carotid.
3. Ascending palatine, a branch of facial artery.
4. Dorsal lingual branches of lingual artery.
5. Descending palatine branch of maxillary artery.

**Venous Drainage:** Veins from the tonsils drain into paratonsillar vein which joins the common facial vein and pharyngeal venous plexus.

**Lymphatic Drainage:** Lymphatics from the tonsil pierce the superior constrictor and drains into upper deep cervical nodes particularly the jugulodigastric (tonsillar) node situated below the angle of mandible.

**Nerve Supply:** Lesser palatine branches of sphenopalatine ganglion (CNV) and glossopharyngeal nerve provide sensory nerve supply.

The palatine tonsils are lymphoepithelial organs located at the junction of the oral cavity and the oropharynx. They are strategically positioned to serve as secondary lymphoid organs, initiating immune responses against antigens entering the body through the mouth or nose. The greatest immunological activity of the tonsils is found between the ages of 3 and 10 years. As a result, the tonsils are most prominent during this period of childhood and subsequently demonstrate age-dependent involution. The epithelium of the tonsils is cryptic and reticulated and contains a system of specialized channels lined by "M" cells.

These cells take up antigens into vesicles and transport them to the extra follicular region or the lymphoid follicles. In the extra follicular region, interdigitating dendritic cells and macrophages process the antigens and present them to helper T lymphocytes. These lymphocytes stimulate proliferation of follicular B lymphocytes and their development into either antibody-expressing B memory cells capable of migration to the nasopharynx and other sites or plasma cells that produce antibodies and release them into the lumen of the crypt.

While all 5 immunoglobulin (Ig) isotypes are produced in the palatine tonsils, IgA is arguably the most important product of the tonsillar immune system. In its dimeric form, IgA may attach to the transmembrane secretory component to form secretory IgA, a critical component of the mucosal immune system of the upper airway. Although the secretory component is produced only in the extratonsillar epithelium, the tonsils do produce immunocytes bearing the J (joining) chain carbohydrate. This component is necessary for binding of IgA monomers to each other and to the secretory component and is an important product of B-cell activity in the follicles of the tonsil.

#### **Preoperative Assessment**

Preoperative assessment in patients undergoing adenotonsillectomy is crucial and may reveal potential problems that may complicate either surgery or the patient's postoperative course. It is crucial to elicit the existence of any coagulation abnormalities. A family history of coagulation disorders or easy bruising may be a warning sign of an underlying bleeding disorder warranting further hematologic evaluation. Routine evaluation of coagulation studies before surgery in patients undergoing adenotonsillectomy is controversial. Manning and others determined that evidence of coagulation disorders in patients with no clinical history of or examination consistent with a hematologic disorder was extremely low, thereby not justifying routine preoperative coagulation studies.

Patients with obvious severe airway obstruction secondary to adenotonsillar hypertrophy may require polysomnography, chest radiography, electrocardiography, and possibly cardiology consultation. Patients with cor pulmonale and hypercapnia may require postoperative intensive care monitoring with mechanical ventilation to avoid post-obstructive pulmonary edema. Patients with other medical conditions may require further testing or preoperative consultation. Patients with a history of significant bronchospasm may require pulmonary medicine evaluation and management in the perioperative period.

## Material & Methods

After approval of the study protocol by the local Ethical Committee and obtaining fully informed written consents, 60 patients assigned for tonsillectomy enrolled in the study of age group 5 to 35 yr. The study conducted at Department of Otorhinolaryngology, MBS Hospital Kota Rajasthan from Dec. 2010 to Oct. 2012. Patients with history of bleeding diathesis allergy to study drugs, or tonsillar abscesses excluded from the study.

Patients randomly divided into 6 equal study groups (n=10); Group I (Negative control group) included patients assigned to receive PT saline infiltration as placebo, Group II (Positive control group) included patients assigned to receive xylocaine (1%) PT infiltration. Group III included patients assigned to receive tramadol (2mg/kg) PT infiltration, Group IV included patients assigned to receive ketamine (0.5mg/Kg)<sup>(46)</sup> PT infiltration, Group V received combination of Bupivacaine (5mg/ml) with Tramadol (2mg/kg), Group VI received Bupivacaine (5mg/ml) with Ketamine (0.5mg/Kg). All medications prepared as 2ml in volume and injected as 1ml per tonsil 3 min. prior to incision (pre-incisional).

All study patients premedicated with midazolam intravenously before the procedure and received nalbupine i.v. immediately after induction of general anesthesia.

## Operative Techniques

Tonsillectomy operation performed by dissection method. Before making incision, infiltration of tonsillar bed through ant. Pillar with various analgesic agents like xylocaine, Ketamine. Tramadol & Placebo (Normal Saline), bupivacaine with tramadol/ketamine as their combination (regimen).

## Review of Literature

Tonsillectomies are done since 3000 years ago in india & also done now a days, now a days surgeons are concentrated on the postoperative analgesia after tonsillectomy because after tonsillectomy patients suffer from pain, decrease in oral feeding also in psychological & financial burden.

Smith et al.(2009)<sup>(1)</sup> reported that after tonsillectomy in children, postoperative pain management is essential yet often challenging task, In addition to discomfort, lack of pain management can leads to delays in oral intake of patients, resulting in external stays & increased costs.

Arikan (2008) et al.<sup>(2)</sup> compared the efficacy & safety of preincisional high dose ropivacaine with bupivacaine in relieving post tonsillectomy pain & found preincisional infiltration of the tonsils with high dose ropivacaine markedly decreased the intensity of pain after tonsillectomy in adults when compared with bupivacaine or placebo.

Uger (2008) et al<sup>(3)</sup> investigated the efficacy of intramuscular injection & peritonsillar infiltration of tramadol to prevent pain in children undergoing tonsillectomy & found peritonsillar infiltration with tramadol to prevent pain in children undergoing tonsillectomy & found peritonsillar infiltration with tramadol provided good intraoperative analgesic, less post-operative pain on awaking & lower analgesics requirements after surgery with no significant difference between both routes of administration for any of these parameters.

Kapral (1999) et al<sup>(4)</sup> & Robaux (2004) et al<sup>(63)</sup> reported that tramadol when added to local anesthetics, modifies peripheral anesthesia.

McCartney (2007) et al<sup>(5)</sup> concluded that preincision infiltration of anesthetic mixture combined with general anesthesia reduces significantly post-tonsillectomy pain in children & provides a more rapid return to normal activity compared to general anesthesia alone or in combination with a placebo infiltration.

Ehab Saaid (2009) et al<sup>(6)</sup> concluded that preincisional peritonsillar infiltration for post-operative pain relief in children following adeno-tonsillectomy: A placebo-controlled comparative study.

Dr. A.K. Gupta, Sunanda Gupta, Dharam s. meena, Umadatt. sharma (2002)<sup>(7)</sup>: Post-tonsillectomy Pain: Different Modes of Pain Relief Indian Journal of Otolaryngology and Head and Neck Surgery. Vol.54.No.2, April-June 2002.

Dr.Sona Chaturvedi, Dr.Domkondwar U.G;A<sup>(8)</sup> Comparative Study of Topical Analgesia with 4% Lignocaine and 0.5% Bupivacaine Following Tonsillectomy: Indian J. Anaesth.2005;49(2):113-115.

Dr.Akbar Pizadeh, Mo-Ali.Mohammadi, Sooreh Allaf-Akbari, Masood Entezarias<sup>(9)</sup>-The Effect Of Ketamine On Post-tonsillectomy Pain in Children: A Clinical Trial; Iranian Journal of Otolaryngology No.1, Vol.24, Serial No.66, winter 2012.

Moller (2010) et al<sup>(10)</sup> showed that postoperative pain in the preoperative peritonsillar injection with bupivacaine was less compared with the control (placebo) group injected with no. In a large scale study on 1026 patients, pain levels in the ketamine group were shown to be lower than in the control group and patient satisfaction to be more.

## Observation and Results

Patients randomly divided into 6 equal study groups (n=10); Group 1 (Negative control group) included patients assigned to receive PT saline infiltration as placebo; Group 2 (Positive control group) included patients assigned to receive xylocaine (1%) PT infiltration. Group 3 included patients assigned to receive tramadol (2mg/kg) PT infiltration, Group 4 included patients assigned to receive ketamine (0.5mg/Kg) PT infiltration, Group 5 received

combination of Bupivacaine (5mg/ml) with Tramadol (2mg/kg), Group 6 received Bupivacaine (5mg/ml) with Ketamine (0.5mg/Kg)

Gp1-normal saline

Gp2-xylocaine (1%)

Gp3-tramadol (2mg/kg)

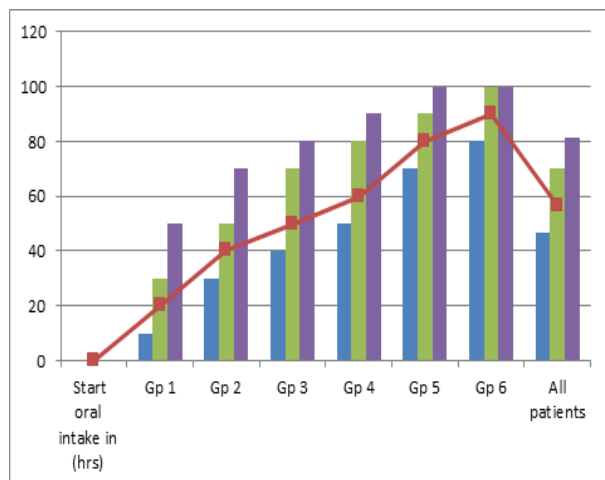
Gp4-ketamine (0.5mg/kg)

Gp5-bupivacaine (5mg/ml) with tramadol

Gp6-bupivacaine with ketamine

#### Distribution of patient's according to start oral intake (hrs.upto) post-operatively

Start oral intake in (hrs)	4 <sup>th</sup>	6 <sup>th</sup>	9 <sup>th</sup>	12 <sup>th</sup>
Gp 1	10	20	30	50
Gp 2	30	40	50	70
Gp 3	40	50	70	80
Gp 4	50	60	80	90
Gp 5	70	80	90	100
Gp 6	80	90	100	100
All patients	46.6	56.6	70	81.6



#### Discussion

We have divided patients in six groups according to drugs which were injected to patients preoperatively in tonsillar fossa.

Patients were asked to take orally at 4<sup>th</sup> hour only 10% patients were able to swallow cold liquid and ice-cream. Group1 (normal saline), 30% in group 2 (xylocaine), 40% in group3 (tramadol), 50% in group4 (ketamine), 70% in group5 (bupivacaine and tramadol) and 80% in group6 (bupivacaine and ketamine).

The time of oral intake depends on pain which occurs after tonsillectomy. Oral intake starts early if analgesics injected in peritonsillar space preoperatively. This time depends upon efficacy of analgesic drugs if

analgesic effect good, oral intake starts earlier and if it is less then duration is more.

Group1 is controlled where normal saline is injected. It has no analgesic effect and oral intake is relatively delayed, pain full and has maximum hospital stay. When analgesics are injected patients starts oral feeding early, less pain full and hospital stay is reduced.

After 6 hours only 20% patients in group1 were able to starts oral feeding, it was 40% in gp2, 50% in gp3, 60% in gp4, 80% in gp5 and 90% in gp6 respectively.

After 9<sup>th</sup> hours 30% patients in gp1, 50% in gp2, 70% in gp3, 80%in gp4, 90% in gp5 and 100% in gp6 were able to swallow the cold liquid and semisolids. After 12<sup>th</sup> hours of operation 50% patients in gp1, 70% in gp2 80% in gp3, 90% in gp4, 100% in gp5 and gp6 were able to feed satisfactorily.

Average time of oral intake in 6<sup>th</sup> hours is 56.6% and in 12<sup>th</sup> hours 81.6% of patients starts oral intake. The difference between all groups was statistically significant (P<0.05).

Our study references are similar to the study of "the role of bupivacaine in post-tonsillectomy pain-A randomized controlled study" by Dr. Mohsen Pazoki Mangalore in 2010 and from the Journal of International medical research 2005;33:188-195.

#### Conclusion and Summary

Preincisional infiltrations of various agents are effective method to reduce post-tonsillectomy pain. This method also effective for earlier start of oral feeding and discharge from the hospital

We recommend the routine use of pre incisional peritonsillar infiltration of various agents in all tonsillectomy cases, irrespective of the age of the patient to reduce the post-tonsillectomy pain and other morbidities.

#### Summary

This is prospective, randomized, single blind controlled clinical trial to assess the effect of preincisional peritonsillar infiltration of various agents on pain after tonsillectomy, which was performed on Dec.2010 till Oct.2012 in the department of ENT, Govt. Medical College, Kota.

A volunteer sample of 60 patients, aged 5 to 35 yrs with history of recurrent or chronic tonsillitis were included in this study and planned for tonsillectomy with or without adenoidectomy

Patients were divided into 6 equal study groups (n=10); Group I (Negative control group) included patients assigned to receive PT saline infiltration as placebo; Group II (Positive control group) included patients assigned to receive xylocaine PT infiltration. Group III include patients assigned to receive tramadol (2mg/kg) PT infiltration, Group IV included patients assigned to receive ketamine (0.5mg/Kg) PT

infiltration, Group V received combination of Bupivacaine (5mg/ml) with Tramadol (2mg/kg), and Group VI received Bupivacaine (5mg/ml) with Ketamine (0.5mg/Kg).

All medications prepared as 2ml in volume and injected as 1ml per tonsil 3 min prior to incision (pre-incisional).

Postoperative pain was assessed using OPS and ALDRETE score for severity of pain at different time after the surgery. The time of oral intake start and total admission days after the surgery also were noted. Comparison of various agents for pain, oral intake and postoperative admission days were noted. No complication of preincisional peritonsillar infiltration of various agents was seen in this study.

### Reference

- Smith J, Newcomb P, and Sundberg E, Shaffer P (2009): Relationship of opioid analgesic protocols to assessed pain and length of stay in the pediatric post anesthesia unit following tonsillectomy. *J Perianesth Nurs*;24(2):86-91.
- Arikan OK, Sahin S, Kazkayasi M, Muluk NB, Akpınar S, Kilic R (2008): High-dose ropivacaine versus bupivacaine for post tonsillectomy pain relief in adults. *J Otolaryngology Head Neck Surg.*;37(6):836-43.
- Ugur MB, Yilmaz M, Altunkaya H, Cinar F, Ozer Y, Beder L (2008): Effects of intramuscular and peritonsillar injection of tramadol before tonsillectomy: a double blind, randomized, placebo-controlled clinical trial. *Int. J Pediatric Otorhinolaryngol*;72(2):241-8.
- Kapral S, Gollmann G, Waltl B, Likar R, Sladen RN, and Weinstabl C, Lehofer F (1999): Tramadol added to mepivacaine prolongs the duration of an axillary brachial plexus blockade. *Anesth Analg*;88:853-6.
- McCartney C J(2007), Duggan E, Apatu E. Should we add Clonidine to local anesthetic for peripheral nerve block? A qualitative systematic review of the literature. Dept of Anesthesia, sunny brook health sciences centre and uni. of torrent.
- Zonguldak Karaelmas University, Faculty of Medicine, Department of Otolaryngology-Head and Neck Surgery, Zonguldak, Turkey. Gazi University, Faculty of Medicine, Department of Otolaryngology-Head and Neck Surgery, Ankara, Turkey. Bakirkoy Acibadem Hospital, Istanbul, Turkey. Zonguldak Karaelmas University, Faculty of Medicine, Department of Anesthesiology Zonguldak, Turkey. Wakayama Medical University, Department of Otolaryngology-Head & Neck Surgery, Wakayama, Japan Received 24 September 2007; received in revised form 1 November 2007; accepted 2 November 2007.
- Dr. A.K. Gupta, Dharam s. meena: Post-tonsillectomy Pain: Different Modes of Pain Relief *Indian Journal of Otolaryngology and Head and Neck Surgery*. April-June 2002.
- Dr. Sona Chaturvedi, Dr. Domkondwar U.G; A Comparative Study of Topical Analgesia with 4% Lignocaine and 0.5% Bupivacaine Following Tonsillectomy: *Indian J. Anaesth*. 2005.
- Dr. Akbar Pizadeh, Mo-Ali. Mohammadi, the Effect of Ketamine on Post-tonsillectomy Pain in Children: A Clinical Trial; *Iranian Journal of Otolaryngology* 2012.
- Carstensen M, Moller AM. Adding ketamine to morphine for intravenous patient-controlled analgesia for acute postoperative pain. *Br J Anaesth* 2010;104(4):401-6.