

## Surgical options for Aesthetic management of facial Melanocytic Nevi

Sudhir Kumar<sup>1</sup>, Neeraj Srivastava<sup>2</sup>, Brijendra Singh<sup>3</sup>

<sup>1</sup>Professor, Dept. of Plastic Surgery, <sup>2</sup>Associate Professor, Dept. of Dermatology, Venereology & Leprosy, MLB Medical College, Jhansi, Uttar Pradesh, <sup>3</sup>Professor, Dept. of Anatomy, AIIMS, Jodhpur, Rajasthan

**\*Corresponding Author:**

Email: drbrijendrasingh@gmail.com

### Abstract

Melanocytic nevi frequently involve the face. Congenital Melanocytic nevi are a known risk factor for melanoma. So there is a strong medical indication for excision of these lesions. But most of the patients request the excision for cosmetic reasons. We share our experience of excision and reconstruction in 33 such consecutive lesions. Selection of reconstructive procedure after excision was done depending over the size, site and orientation of lesion. Patient's financial condition and his/her acceptance for staged procedure were also considered in choosing the procedure.

### Introduction

Melanocytic nevi are benign neoplasm or hamartoma of melanocytes. Both sexes are equally affected. These lesions show some responsiveness to sex hormone. Congenital melanocytic nevi are present at birth and are considered to be malformations or hamartomas. Acquired melanocytic nevi are not present at birth. The incidence of melanocytic nevi increases throughout the first 3 decades of life. The peak incidence of melanocytic nevi is observed in the fourth to fifth decades of life.

Congenital melanocytic nevi are one of several known risk factors for the eventual development of melanoma. For giant congenital melanocytic nevi, the risk of developing melanoma has been reported to be as high as 5-7% by age 60 years. So there is need for regular monitoring of such lesion. Excision is even better option. But patient with nevus on face request excision for cosmetic reasons. These patients are very much concerned about the post excision scar mark. So in addition to excising these nevus closures with minimal scarring is important. We used various surgical options for reconstruction after excising melanocytic nevus from face. We are sharing our experience of excising 33 consecutive lesions.

### Material and Methods

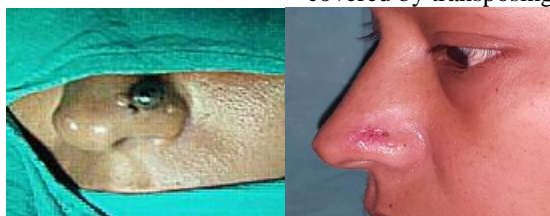33 melanocytic nevi over face (in 19 patients) were managed surgically between December 2014 and July 2016. Largest lesion was 7cms x 4.6 cm over chin and smallest on was 0.7mm x 0.5mm over upper lip.

Small lesions were excised and defects were closed primarily with 6-0 nylon suture. Larger defects were managed by serial excision, excision and full thickness skin grafting and excision and flap cover.

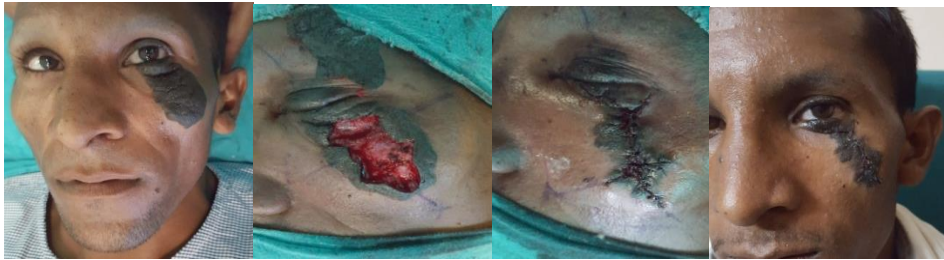
Serial Excision was done in larger lesions which cannot be excised and closed in single stage. Excision was done in two to four stages depending over the size and site of the lesion. At first elliptical excision was done from the centre of the lesion. Before closure multiple small V shaped excisions were done from the edges of the ellipse. These V excisions further reduced the length of final scar. Interval of 3 to 6 months was kept in between two surgeries for excisions. During this period patients were advised regular massage with moisturiser to relax the surrounding skin.

Five lesions in our five patients were managed by excision and full thickness skin grafting. After excising the nevus meticulous haemostasis was done. Template of defect was taken with the piece of lint. Full thickness skin graft exactly matching the template in shape and size was harvested. Skin donor site was medial aspect of arm in both of our patients. Graft was sutured edge to edge with 5-0 nylon suture. Dressing was done with paraffin gauze. Check dressings were done on 6<sup>th</sup> day.

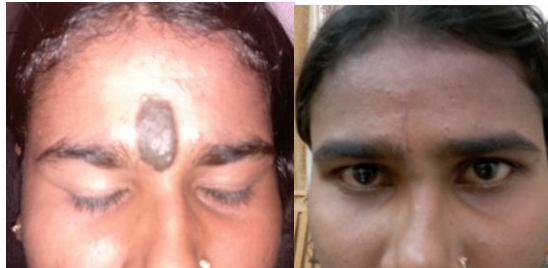We managed three lesions in three patients by excision and closure of defect with Limberg flap. Two of these lesions were on temporal region and one on lower eyelid around medial canthus. Before excising the nevus most suitable flap was planned and marked with surgical marking pen. Nevus was excised and flap was raised with very gentle tissue handling. Defect was covered by transposing the flap.



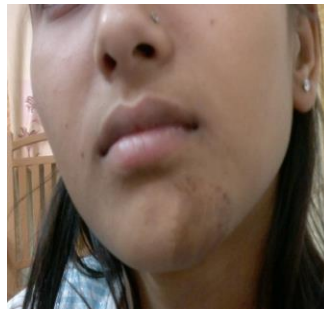**Fig. 1: Aesthetic excision of large nevus from nose and primary closure**



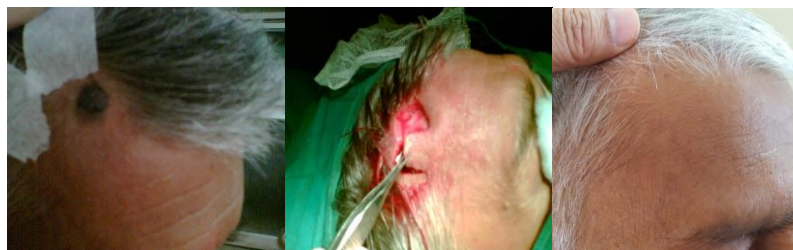**Fig. 2: Serial Excision: excision of lesion done along the both axis. Marked decrease in both dimensions after first stage**



**Fig. 3: Linear scar smaller than the length of lesion after two stages of Serial Excision**



**Fig. 4: Three years post-operative result after excision and Full thickness Skin grafting for large Melanocytic nevus over chin**



**Fig. 5: Melanocytic Nevus forehead. Excision and reconstruction done with Limberg flap. Hardly visible scar**

#### Observations

Procedure	Number of Lesions managed	Size of Lesion	Complications
Excision & direct closure	18	Smallest 0.7x 0.5 mm Largest 1.5x0.8 cm	Scar hypertrophy in 2 lesions.
Serial Excision	7	Smallest 2.5x2.0 cm Largest 6.5x 3.0 cm	Scar hypertrophy in 4 cases.
Excision and Skin Grafting	5	Smallest 3.0x 2.0 cm Largest 7.0x 6.0 cm	Marginal graft loss in one patient.
Excision and Flap	3	Smallest 1.5x 1.7 cm	None.

		Largest	2.0x 2.5 cm	
--	--	---------	-------------	--

## Discussion

Melanocytic nevi are benign neoplasm or hamartomas composed of nevus cells. Nevus cells are variant of melanocytes and they differ them by absence of dendrites. Congenital nevus result from anomaly in embryogenesis and so considered to be malformations or hamartomas. In contrast, acquired melanocytic nevi are considered to be benign neoplasm.

Melanocytic nevi are more common in white races. In fair individuals, most melanocytic nevi occur on the trunk. In dark-skinned individuals, acral melanocytic nevi are more common. This difference in prevalence can be due to the fact that identifying moles in dark-skinned patients is relatively difficult, especially if the lesions are macular. Some authorities have suggested that melanocytic nevi are in part stimulated by exposure to sunlight. If so, then individuals with dark skin might have fewer nevi because of the protective properties of melanin. There is no clear sex predilection for the melanocytic nevi. However, melanocytes have some degree of sex hormone responsiveness. Melanocytic nevi frequently change their appearance during pregnancy. Acquired melanocytic nevi are not present at birth, and the incidence of melanocytic nevi increases throughout the first 3 decades of life. The peak incidence of melanocytic nevi is in the fourth to fifth decades of life, and the incidence with each successive decade decreases, with a low incidence in elderly persons.

Congenital melanocytic nevi are classified into small, medium and giant according to their actual or predicted adult size in maximum dimension. Small congenital nevi are < 1.5 cm diameter, medium congenital nevi are 1.5–19.9 cm diameter, large or giant congenital melanocytic nevi are ≥ 20 cm. Hairy congenital nevi grow thick long hairs.

The pathological classification of melanocytic nevi relates to where nevus cells are found in the skin. A junctional nevus has groups or nests of nevus cells at the junction of the epidermis and the dermis. A dermal or intradermal nevus has nevus cell nests in the dermis. A compound nevus has nests of nevus cells at the epidermal-dermal junction as well as within the dermis. A combined nevus has two distinct types of mole within the same lesion usually blue nevus and compound nevus.

Congenital melanocytic nevi are one of several known risk factors for the eventual development of melanoma. For giant congenital melanocytic nevi, the risk of developing melanoma has been reported to be as high as 5-7% by age 60 years.

Patients ask for excision of facial melanocytic nevus only for cosmetic reasons. They are very much worried about post excision scars. Surgical scars are very much unpredictable even in the hands of experienced surgeons. So every possible effort should be done to limit the dimensions of scars and at the same time it should be placed in favourable direction. Procedures like serial excision, skin grafting, local flaps and tissue expansion should be used whenever required to improve the cosmetic results.

Small nevus can be excised easily in single stage. Careful suturing with fine nylon sutures gives satisfactory

scars. Tension free and meticulous approximation skin edges is key for minimal scarring.

We performed serial excision in large lesions which will create large defects after excision in single stage. Concept of multiple excisions for wide lesions was given by Morestin a century ago. In this modern era everybody is in hurry so there is little space for multi-stage surgical procedures. Moreover techniques like tissue expansion are available nowadays. Most of our patients are poor and they readily opted for serial excision on hearing the cost of tissue expanders. We got satisfactory result with this technique. In our cases initial one or two excisions were done under general anaesthesia. Subsequent excisions were done as day care procedure under local anaesthesia.

Full thickness skin grafting is simple and reliable method to cover the defects after excision of facial lesions. Grafts harvested from retroauricular area and from medial aspect of upper arm very well match with facial skin. Initially graft is slightly hyper-pigmented but it beautifully matches with facial skin after 5-6 months. Donor deformity is not an issue as the scar is very well concealed.

Limberg flap is a transposition flap in which donor site is primarily closed. This flap depends on the looseness of surrounding skin. Limberg flap is designed to cover a rhomboid defect. So while planning a Limberg flap defect is either converted to rhomboid or it is imagined as a rhomboid. For one rhomboid defect four Limberg flaps are possible. Most suitable one based on skin laxity, location of final scar and blood supply of the flap is used. Limberg flaps are very useful option for the soft tissue defects of the face. We successfully used this flap in our patients. It is single stage procedure and flap is very reliable. As local tissue is used there is complete match of colour and texture. But it requires careful planning so that scar is placed in favourable site and direction.

## References

1. Feins NR, Rubin R, Borger JA. Ambulatory serial excision of giant nevi. *J Pediatr Surg* 1982;17:851.
2. Kalpesh J, Gajiwala. Biaxial serial excision: A techniqueto deal with benign skin lesions and scars. *Indian journal of Plastic Surgery Sep-Dec 2012 Vol 45 Issue 3;522-525.*
3. Natarajan K, Arunachalam P, Sundar D, Srinivas CR. Congenital melanocytic nevi: catch them early!. *J Cutan Aesthet Surg*. 2013 Jan. 6(1):38-40.
4. Carrera C, Puig-Butillè JA, Aguilera P, Ogbah Z, Palou J, Lecha M, et al. Impact of Sunscreens on Preventing UVR-Induced Effects in Nevi: In Vivo Study Comparing Protection Using a Physical Barrier vs. Sunscreen. *JAMA Dermatol*. 2013 May 8. 1-11.
5. Converse JM. La réduction graduelle des difformités tégumentaires: H. Morestin, M.D., Paris (Bull. et mém. Soc. chir. Paris, 41:1233,1915. *Plast Reconst Surg* 1968;42:163-72.
6. Limberg AA. Design of local flaps. In Gibson T, ed. *Modern trends in plastic surgery*; 2<sup>nd</sup> Edition. London: Butterworth, 1966.