

## Low velocity penetrating frontal bone injury with a stone: an interesting case report

AK Tripathi<sup>1</sup>, Abhishek Singh<sup>2</sup>, Sameer R. Verma<sup>3</sup>, Antriksh Srivastava<sup>4</sup>, Purnima Chaudhary<sup>5</sup>

<sup>1</sup>Assistant Professor, <sup>2,4</sup>Resident, <sup>5</sup>Intern, Dept. of General Surgery, <sup>3</sup>Professor, Dept. of Radiology, Subharti Medical College & University, Meerut, Utter Pradesh

**\*Corresponding Author:**

Email: jyotibajpai33@gmail.com

### Abstract

Penetrating Cranial wounds are rare. They most commonly occur through Orbital or temporal region. Penetrating wounds in frontal region are rare and mostly associated with high velocity. There are various etiological factors associated with such type of injuries. Computed tomography scan of head is useful in such injuries. In this case report, we are reporting an interesting case of low velocity penetrating frontal bone injury with a stone.

**Keywords:** Foreign body, Scalp injury, Head injury

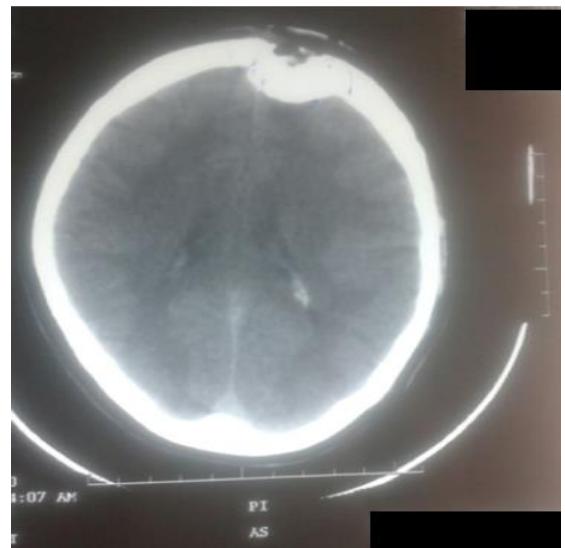
### Introduction

Low velocity direct penetration of the foreign body into the frontal bone is rare because of its thickness. To best of our knowledge we don't come across upon review of literature on such case. Trans-cranial penetrating injuries by a stone, a wooden piece, or a mental chopstick are usually through the orbit, nose, ear, squamous part of the temporal bone, or the thin walled skull.<sup>(1,2,3,4,5,6,7)</sup> Hence, we are reporting an interesting case of penetrating cranial injury with stone.

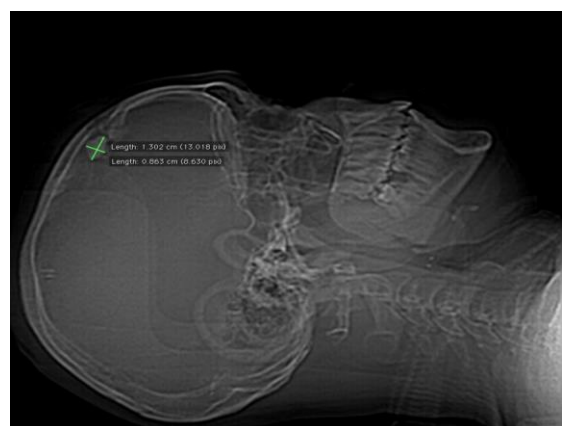
### Case Report

A 32-year old male was admitted with a history of pus discharge at left frontal region because of the presence of wound. He had a history of head injury due to fall from a motor bike 10 days back. At that time of injury there was no history of loss of consciousness, headache, vomiting, seizure, ear nose or throat bleed. Glasgow coma scale score was E4V5M6. He had a lacerated wound over left frontal region. He was managed conservatively in a private hospital and suturing of the wound was done. After three days he developed pus discharge from wound. At the time of admission in Subharti Medical College he had only history of pus discharge from left frontal wound.

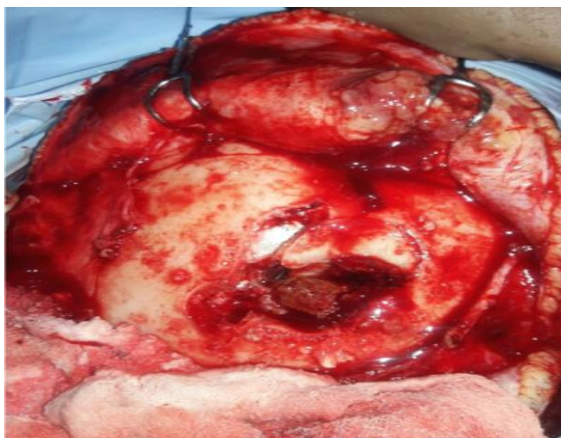On examination, he was well oriented to time, place, and person. The Glasgow coma scale was E4V5M6 and the vitals were stable. Signs of meningitis were absent on Local Examination there was a discharging sinus over the left frontal region. Computed tomography (CT) of the head showed depressed bony fracture in left frontal region and CT revealed hyperdense foreign body in frontal region. (Fig. 1, 2, 3) Left frontal craniectomy was done under general anesthesia and removed the depressed bony fragments and foreign body which was identified as stone. (Fig. 4) Dura mater was intact. Debridement of wound was done. Intravenous antibiotics were given for 12 days. Post-operative course was uneventful.



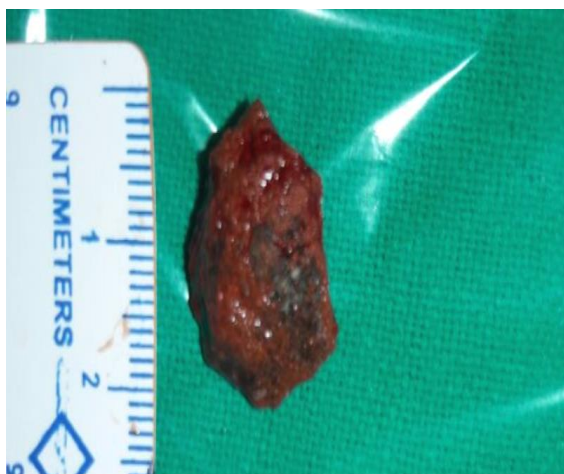**Fig. 1: Computed Tomography slouching. Depressed (Lt) Frontal bone**



**Fig. 2: Lateral scout view on computed tomography shows a radio-opaque structure measuring approximately 13 x 8.6mm under the depressed fracture of frontal bone**



**Fig. 3a: Intra Operative: Depressed Bony fractured with retriend stone**



**Fig. 3b: Stone (1.8×1.5×1.5 cm)**

## Discussion

Penetrating head injuries (PHI) are either high - or low - velocity type. Worldwide, most PHIs are high velocity type and caused by missile injuries, notably gunshot and shrapnel wounds. Most non missile PHIs are caused by knives or cutting instruments stones, sharpened wooden sticks, screwdrivers, nails, spikers, iron roads, arrows, pencils, ice picks, chopsticks, umbrella ends, thumbtacks, fishing harpoons, paint brushes, scissors, crotchet hooks, sewing needles, and garden forks.<sup>(1,2,3,4,5,6)</sup> In civilian accidents, most penetrating cranial wounds are of low-velocity type. In cranial vault, orbit, nose, ear squamous part of the temporal bone are relatively thinner parts so that projectile objects with less force can easily penetrate inside the skull through these corridors.<sup>(3)</sup> In our case, a piece of stone penetrated the left frontal bone that is rare. Lower velocity objects produce a track of primary tissue damage, resulting in localized injury without

diffuse or global affects. In the present case, depressed bony segments were present around the stone.

Computed tomography scan of head is useful in PHI. It determines the extent of intraparenchymal injury, identify bony defects and foreign body.

Penetrating head wounds can cause cerebral contusions, cerebrospinal (CSF) fluid fistulas, intracerebral hematoma, subdural and epidural hematoma, subarachnoid hemorrhage, pneumocephalus, skull fracture, cerebral edema, etc. Delayed complication of PHI are brain abscess, encephalitis, meningitis, and scalp sepsis. In our case pus discharging wound over left frontal region was present. Because these injuries are by definition compound fractures. So that tetanus toxoid and prophylactic broad spectrum antibiotics should be given early in patient management. Expeditious removal of the penetrating foreign body and bone fragments along with local debridement of the scalp, skull, dura, and involved parenchyma are the goals of surgical treatment.

In our case, we removed the depressed fragmented bones and stone after doing small left frontal craniectomy, wound was cleaned with hydrogen peroxide and normal saline. After proper debridement of soft tissue and dura mater we closed the wound in two layer. In future we will treat the bony defect with titanium mesh.

## Conclusion

Prompt surgical intervention is necessary to prevents undue morbidity and mortality in penetrating head injury cases. Early identification of foreign body is necessary to prevent delayed complications.

## References

1. GD Satyarthee, Sachin A Borkar, Anuj Kumar Tripathi, BS Sharma. Transorbital Penetrating cerebral injury with a ceramic stone: Report of an interesting case. 2009;57(3):331-333.
2. Penetrating Injury of orbit and skull with wooden stick from a tree: A rare case report. Sanjiv M. Huzurbazar, Yogesh Teni, Arun Patil the Indian Journal of Neurotrauma. 2014;11(2):166.
3. Gopalakrishnan MS, Devi IB, Fatal penetrating orbitocerebral injury by bicycle brake handle. Indian Journal of Neurotrauma (IJNT) 2007;4:123-4.
4. Seex K, Koppel D, Fitzpatrick M, Pyott A. Trans-orbital penetrating head injury with a door key. J. Craniomaxillofac Surg 1997;25:353-5.
5. Kelly DF, Nikas DL, Becker DP. Diagnosis and treatment of moderate and severe head injuries in adults. In Youmans JR, ed. Neurological Surgery. 4th ed. Philadelphia: WB Saunders; 1996. P. 1618-718.
6. Bhaganagare A, Nadkarni T, Goel A. Penetrating craniocerebral injury with nails: Case report. Indiana Journal of Neurotrauma (IJNT) 2007;4:63-4.