

## Extracranial neck schwannoma in a child: A rare case

Sunil Garg<sup>1,\*</sup>, Poonam Singla<sup>2</sup>

<sup>1</sup>Assistant Professor, Baba Saheb Ambedkar Medical College & Hospital, New Delhi, <sup>2</sup>Consultant, Dept. of Otorhinolaryngology- Head & Neck Surgery, Metro Hospital, Gurgaon, Haryana

**\*Corresponding Author:**

Email: dr.sunilgarg09@gmail.com

### Abstract

Schwannoma at extracranial site are mostly found in cervical sympathetic chain. These pose a great diagnostic difficulty especially in children because these are rare clinical entity in childhood. We are hereby presenting such a case of extracranial schwannoma in a four year old child.

**Keywords:** Child, Cervical sympathetic chain, Schwannoma, Extracranial, Rare

### Introduction

The head and neck region presents with various types of swellings. Neurogenic tumours arising from these regions are rare in the pediatric population. These tumours are commonly found arising from the parapharyngeal spaces.<sup>(1)</sup> Nearly 45% of all schwannomas occur in the head and neck area, where they may originate from any of the peripheral, cranial (last four cranial nerves) or autonomic nerves, the vagus nerve being the most common site.<sup>(2)</sup> Patients with these tumors generally present between 20 and 50 year of age, but no age is exempt.<sup>(3)</sup>

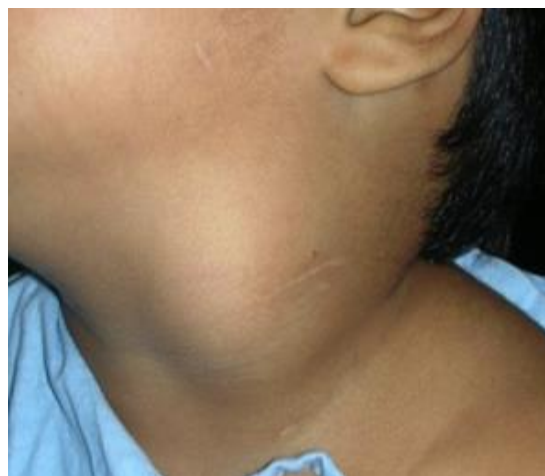Schwannomas arising from the cervical sympathetic chain are rare, with less than 60 cases reported in the English literature. Cervical sympathetic chain schwannoma (CSCS) usually present as asymptomatic neck mass; however, sometimes features of Horner's syndrome may be found preoperatively. These tumors present most commonly in the fourth and fifth decades but occurrence of CSCS is very rare in childhood.<sup>(3)</sup>

We are hereby presenting a case of paediatric schwannoma of cervical sympathetic chain origin in a four year old child.

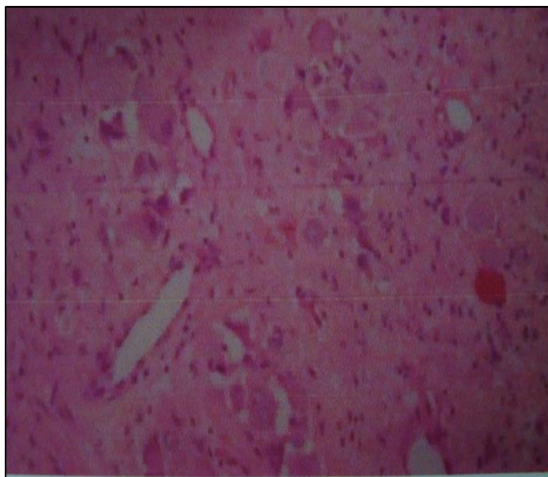
### Case Report

A 4-year-old girl presented to us on Dec 2007 with a mass on left side of her neck for about 2years which was gradually increasing in size associated with ptosis on left side since last 10 days. On examination, mass was 4x4 cm in size, well defined, soft, non-tender, mobile from side to side, non-pulsatile, lying deep to upper 1/3 of sternomastoid muscle (Fig. 1). Except ptosis, there was no other neurological deficit. Her neck movements were normal and there was no wasting or asymmetry of neck musculature. FNAC report, done twice, was inconclusive. Color Doppler of the mass showed a heteroechoic mass without any necrosis or calcification with increased vascularity along the periphery and within the tumor. Contrast enhanced computed tomography (CECT) scan showed a well-

defined mass of 3.5 x 3.5 x 5.3 cm size on the left side of neck in paravertebral region. The carotid vessels were seen abutting the mass on its medial aspect with internal jugular vein on the lateral side but could not reveal a definitive diagnosis. The patient was planned for excision under general anaesthesia. Before taking up the patient for surgery, he was explained about the possibility of developing Horner's syndrome postoperatively. During surgery the mass was found abutting the common carotid artery and vagus nerve medially and internal jugular vein laterally. Hypoglossal nerve was identified superior to the mass. The tumor was found to be tapering in cervical sympathetic chain. It was 4x5 cm in size and removed in toto with its capsule intact. The specimen was sent for histopathology which showed fascicles of spindle cells having wavy nuclei in a fibrillary background and many scattered uni to multinuclear ganglion cells suggestive of schwannoma (Fig. 2). The patient developed all features of Horner's syndrome, miosis, ptosis, and anhidrosis, in the postoperative period. The patient was discharged on 5<sup>th</sup> post-op day. On 3 year follow up patient had no recurrence.



**Fig. 1: Girl with Left Side Neck Mass (Cervical sympathetic chain schwannoma)**



**Fig. 2: Histopathological Slide (Cervical sympathetic chain schwannoma)**

### Discussion

Non-vestibular extracranial head and neck schwannomas are more common than vestibular schwannoma. But these have got less attention than their relatively more morbid intracranial acoustic counterpart. The neurogenic presenting symptoms and signs are expected to be more prominent in cephalic neurogenic tumours. But only 19% cases present with neurogenic symptoms or signs.<sup>(4)</sup> Therefore extracranial head and neck schwannoma is a challenging condition to the head and neck surgeons.

The diagnostic interpretation, by fine needle aspiration cytology, of these benign spindle cell tumors is very difficult.<sup>(5)</sup> Ultrasonography also does not help much in diagnosis but it may tell us about its relation to other vascular neck structures but it does not confirm the diagnosis of schwannoma.

To prevent lifelong morbidity, the diagnosis of nerve of origin very important. This is very difficult to define preoperatively. Radiographically, on CT scan or MRI, while a schwannoma will usually appear as a well-circumscribed, contrast-enhancing mass that is contiguous with an identifiable neural structure (particularly on MRI), but no pathognomic imaging features are apparent. In a study by Hin-Lin Liu et al the specificity of FNAC and imaging studies in making the diagnosis of schwannoma was 20 and 38%, respectively.<sup>(6)</sup> The nerve of origin could be identified in 4% cases only. Therefore, the diagnosis relies on clinical suspicion; and confirmation is often obtained by means of surgical pathology.

CSCS usually presents as an asymptomatic, slow growing neck mass. The presence of Horner's syndrome before excision is unusual and has only been reported in 6 cases of CSCS. Our case also presented with ptosis but other symptoms of Horner's syndrome

were not present. Although pressure symptoms may also be present but, this is rare because the structures in the neck are located in loose fascial compartments. This tumor is generally found in patients between 20 and 50 years of age.

We found CSCS in a 4 year child which to our knowledge is the first case at this age. Patient developed complete Horner's syndrome after excision of the tumor and no recurrence after 3 years of follow up. Hin Lin Liu et al also reported no recurrence in 6 cases of schwannoma on 40 months follow up.<sup>(6)</sup>

To conclude, we recommend that schwannoma should also be included as a differential diagnosis in childhood neck masses.

### Author's Contributions

Dr. Sunil Garg contributed towards clinical management of the patient; conceptualization and revision of the manuscript. Dr. Sunil Garg and Dr. Poonam Singla contributed towards the literature search and drafting the manuscript. . Dr. Sunil Garg also helped in clinical management and revision of the manuscript.

### Declaration of the conflicting interests

The authors declared no potential conflicts of interest with respect to and/or publication of the article.

### Funding

Authors received no financial support for the research, authorship and/or publication of the article.

### Ethical Approval

Consent was taken from parents of the children for surgery and publication of the case report.

### References

1. Lin C, Wang C, Liu S, Wang C, Chen W. Cervical sympathetic chain schwannoma. *J Formos Med Assoc.* 2007;106(11):956-960.
2. Colreavy MP, Lacy PD, Hughes J et al. Head and neck schwannomas: a 10 years review. *J Laryngol Otol* 2000;114:119-24.
3. Cashman E, Skinner LJ, Timon C. Thyroid swelling: an unusual presentation of a cervical sympathetic chain schwannoma. *Medscape J Med* 2008;10:201.
4. Malone JP, Lee WJ, Levin RJ. Clinical characteristics and treatment outcome for non-vestibular schwannomas of the head and neck. *Am J Otolaryngol-Head and Neck Med and Surg* (2005) 26:108-112.
5. Yu GH, Sack MJ, Baloch Z, Gupta PK. Difficulties in the fine needle aspiration (FNA) diagnosis of schwannoma. *Cytopathology* (1999) 10:186-194.
6. Liu HL, Yu SY, Li GK, Wei WI. Extracranial head and neck schwannomas: a study of the nerve of origin. *Eur Arch Otorhinolaryngol* (2011) 268:1343-1347.