

## Clinical study of correlation between preoperative findings of HRCT with intra-operative findings of cholesteatoma in cases of CSOM

Niveditha J. Sagar<sup>1</sup>, Chidananda R. Devasamudra<sup>2,\*</sup>

<sup>1</sup>Assistant Professor, DM-WIMS, Wayanad, Kerala, <sup>2</sup>Associate Professor, Dept. of ENT, Shridevi Institute of Medical Sciences & Research Hospital, Tumkur, Karnataka

**\*Corresponding Author:**

Email: devasamudra@gmail.com

### Abstract

Among patients attending to ENT OPD, chronic suppurative otitis media (CSOM) is one of the common conditions. Mastoid, middle ear surgeries are difficult at times because, the CSOM can be associated with complications; the temporal bone accommodates vital structures (internal carotid artery, facial nerve, jugular bulb etc.) and its anatomical variations. In this study, we planned to investigate the use of preoperative HRCT scan to assess the pathology, extent of the disease, middle ear structures, and presence of cholesteatoma and also to compare with intra operative findings.

**Materials and Methods:** The HRCT findings of 40 patients with CSOM with cholesteatoma were compared with operative findings. CT scan was performed with Seimens Somatom emotion 6 scanner. With the help of HRCT status of the middle ear structures (ossicles, scutum, facial nerve canal and tegmen tympani), semicircular canals and sigmoid plate were assessed and compared with operative findings. Correlation between radiological and intra-operative findings was calculated.

**Results:** A good radio surgical correlation is seen in CSOM with cholesteatoma for status of most middle and inner ear structures except for the integrity of the facial canal. A poor radiosurgical correlation was observed for differentiating cholesteatoma from chronic mucosal thickening as the underlying pathology in cases with CSOM. HRCT was found to be sensitive in detecting erosions of incus(85%), stapes(82.3%), scutum(91.67%), sigmoid plate(100%) and mastoid cortex(100%) whereas less sensitive in erosions of malleus (68.75%), tegmen(32.6%), semicircular canal(71.4%) and facial canal(53.3%). 100% specificity was obtained for erosions of malleus, incus, scutum, sinus plate and mastoid cortex whereas it is relatively less specific for erosions of facial canal(84%) and tegmen(81%).

**Interpretation and Conclusion:** HRCT of temporal bone has a definitive role in pre-operative assessment of CSOM with cholesteatoma as it helps in assessing the extent of the disease and integrity of most of the middle ear structures.

**Keywords:** CSOM, HRCT, Cholesteatoma, Radiosurgical correlation, Temporal bone

### Introduction

Chronic suppurative otitis media (CSOM) is a common condition seen in patients attending otolaryngological department. It is a condition in which there is chronic infection of middle ear cleft, which can cause severe destruction of the middle ear and mastoid, leading on to various sequelae.<sup>(1)</sup>

Cholesteatoma can be associated with lot of complications, since temporal bone is surrounded by many vital structures [Brain, Internal carotid artery, Jugular bulb, Facial nerve etc.] and its gross anatomical variation of landmarks makes the surgery difficult at times.

Since considerable number of patients with cholesteatoma attend the ENT department of our hospital, it was necessary to study the cholesteatoma cases, and compare the HRCT findings and intraoperative findings so that it helps us to formulate proper surgical intervention and to avoid intraoperative complications by understanding the exact anatomical variations of landmarks in the temporal bone.

Cholesteatoma is of significant importance to the ENT surgeon as it gives us many challenges. The otologist must make an accurate diagnosis, the otologist must provide a disease free ear that will remain safe throughout the life and can be easily followed up, and

then we should council the patient and the family members as to the nature of the disease, the need for long term follow-up, and the possibility of need of further radiographic studies, reconstructive surgery and aural rehabilitation.<sup>(2)</sup>

The diagnosis of aural cholesteatoma is made with both otoscopic, as well as endoscopic examination. Imaging procedures, such as high-resolution computed tomography (HRCT) and magnetic resonance imaging (MRI), may suggest the presence of cholesteatoma within the temporal bone, and may be used to complement the clinical examination.<sup>(4)</sup> Ossicular chain erosion and blunting of the scutum were commonly seen in cholesteatoma,<sup>(5)</sup> although CT cannot distinguish soft tissue from effusion or granulation tissue in the patients.<sup>(6)</sup> In attic cholesteatoma, erosion of the scutum (the first sign of aural cholesteatoma) in the coronal view can be assessed clearly. Bony erosion occurs more commonly in the long process of the incus, the body of the incus, and the head of the malleus. Expansion of aditus ad antrum increases the probability of attic cholesteatoma. The most common site of labyrinthine fistula is the lateral canal dome; and the most involved segment of the facial nerve is the tympanic segment.<sup>(3)</sup> On MRI, cholesteatoma appears with low signal intensity on T1-weighted, and high signal intensity on

T2-weighted, images.<sup>(3)</sup> HRCT is the imaging modality of choice for evaluation of middle ear structures and their pathologies such as cholesteatoma.<sup>(7)</sup> An HRCT scan is useful for planning the surgical approach, determining the extension and site of cholesteatoma and its sac, assessing the ossicles, evaluating the facial nerve, tegmen and sinus plate, and determining Dural, sigmoid sinus, and jugular bulb positions.<sup>(8,9)</sup>

CT scan findings of acquired cholesteatoma of the temporal bone consist of a homogenous soft tissue mass with local bone erosion and also middle ear opacification due to granulation tissue, pus, and effusion. Findings suggesting cholesteatoma include attic lateral wall (scutum) erosion, aditus ad antrum widening, dislocation of ossicular chain, erosion of ossicles, labyrinthine fistula, facial nerve canal (fallopian canal) erosion, middle ear and mastoid (tegmen) dehiscence, mastoid destruction (automastoidectomy), sigmoid plate dehiscence, and external auditory canal roof erosion.<sup>(5)</sup>

### Materials and Methods

Data for the study was collected from patients attending/referred to teaching hospitals attached to DM-Wayanad institute of medical sciences, (located near Meppadi, Kerala) with clinically suspected chronic suppurative otitis media with cholesteatoma.

**Method of collection of data:** A prospective correlational study was conducted over a period of 2years (January 2014 to December 2016) on 40 patients with clinically suspected chronic suppurative otitis media with cholesteatoma. They presented with symptoms of hearing loss, otorrhea, otalgia, facial palsy or vertigo. Patients were evaluated with High Resolution Computed Tomography. CT images were acquired in axial plane with sections made in a plane rotated 30° superior high-resolution matrix was used (512 × 512), with thin sections (0.63 mm) and a field of view of 15 to the anthropologic base line (the line intersecting the inferior orbital rim and the EAC). Scanning commenced from the lower margin of the external auditory meatus and extended upward to the arcuate eminence of the superior semicircular canal as seen on lateral tomogram. Coronal and sagittal reconstructions were made and images were analysed. Surgical findings were recorded by the ENT surgeon. Positive and negative findings, specificity, sensitivity, and accuracy of HRCT were determined by statistical analysis. Data were analysed using software package SPSS-16. Statistical method of kappa was used to assess radiosurgical correlation for various study variables.

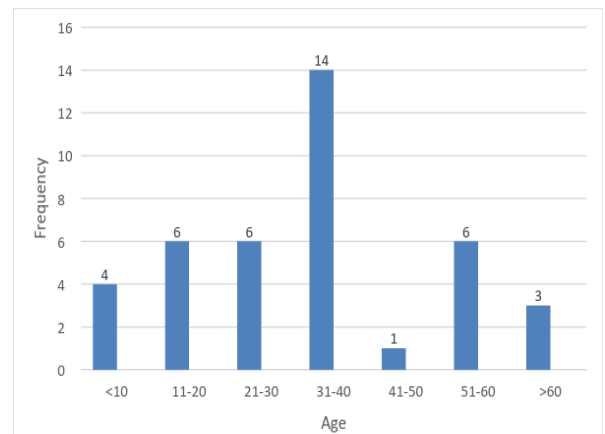
All chronic suppurative otitis media patients with cholesteatoma diagnosed clinically and all age groups and either sex group were included in the group. Trauma and neoplastic growth involving middle ear were excluded. Patients who have previously undergone middle ear operation and Patients with acute otitis media were excluded from the study.

### Results

**Study Design:** A prospective correlational study to find the efficiency of HRCT in the evaluation of chronic suppurative otitis media.

**Table 1: Age distribution of patients studied**

Age group	Frequency	Percentage
<10	4	10
11-20	6	15
21-30	6	15
31-40	14	35
41-50	1	2.5
51-60	6	15
>60	3	7.5
Total	40	100
Mean-33 years		
Standard deviation-17.6		



**Fig. 1: Graph showing Age distribution of the Study Population (N=40)**

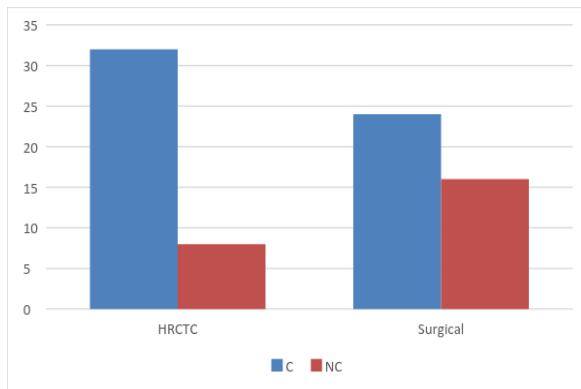
In our study, the maximum percentage of patients were in the age range of 31 to 40 years (35%) with mean age of presentation being 33.3 years and standard deviation of 17.6.

**Table 2: Comparison between HRCT and operative findings regarding underlying pathology for CSOM**

HRCT findings	Cholesteatoma	No cholesteatoma	KAPP A( $\kappa$ )
cholesteatoma	22	10	0.318
No cholesteatoma	2	6	

HRCT diagnosis of cholesteatoma was made using (1) soft tissue mass and (2) presence of bony erosions as criteria.

In our study, a poor radio surgical correlation was noted for differentiation of cholesteatoma and chronic mucosal disease.



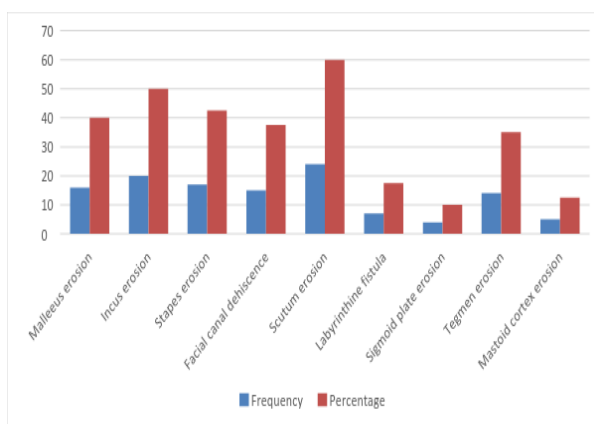
**Fig. 2: Graph showing comparison between CT and operative findings regarding underlying pathology for CSOM**

At surgery, cholesteatoma was present in 24 out of 40 patients (60%). Cholesteatoma was reported on 32 of the 40 CT scans (80%).

From the above data, the sensitivity of the CT scan to detect cholesteatoma is 91.6%, specificity is 37.5%, positive predictive value is 68.75%, negative predictive value is 75% and accuracy is 70%.

**Table 3: Frequency distribution of status of various middle and inner ear structures in CSOM**

Parts studied	Frequency	Percentage
Malleus erosion	16	40
Incus erosion	20	50
Stapes erosion	17	42.5
Facial canal dehiscence	15	37.5
Scutum erosion	24	60
Labyrinthine fistula	7	17.5
Sigmoid plate erosion	4	10
Tegmen erosion	14	35
Mastoid cortex erosion	5	12.5



**Fig. 3: Graph showing frequency distribution of various findings in CSOM**

In our study, among bony erosions, Scutum (60%) and incus erosions (50%) were the most commonly

encountered findings in CSOM patients, with sigmoid plate (10%) and mastoid cortex erosion (12.5%) being the least common.

Radio surgical correlation is excellent for erosions of incus, stapes, scutum, sigmoid plate and mastoid cortex; moderate to good for erosions of malleus, semicircular canals, and tegmen tympani; and poor for facial canal dehiscence and diagnosis of cholesteatoma.

## Discussion

The high resolution computed tomography (HRCT) scan is the standard imaging technique for the temporal bone. Scanning is usually done in axial, coronal and sagittal planes with reconstructions. Some authors reported high 31 Degree of accuracy in the pathological diagnosis, ossicular chain and inner ear conditions. And others concluded that CT has poor ability to diagnose cholesteatoma.

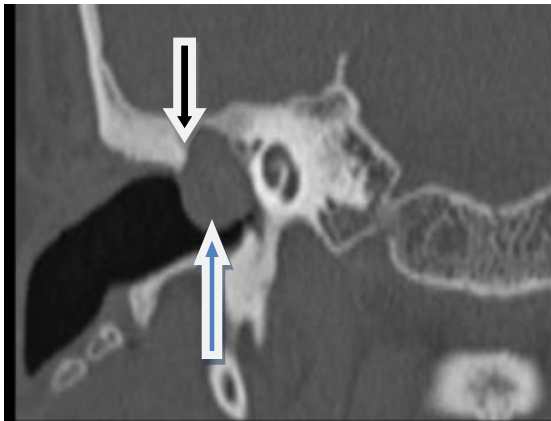In our study, out of 40 cases, the maximum percentage of patients was in the age group of 31 to 40 years (35%). There was a male preponderance (65%) when compared to females (35%) with male to female ratio of 1.9:1. Otorrhea, hearing loss and otalgia were the main complaints patients presented with. All cases included in the study showed involvement of mastoid whereas opacification of aditus was seen in 90% of cases and tympanic cavity in 95% of cases.

In our study, a poor radiosurgical correlation was noted for differentiating cholesteatoma and chronic mucosal disease in the middle ear cavity using soft tissue mass and bony erosions as the radiologic criteria. At surgery, cholesteatoma was present in 24 out of 40 patients (60%) whereas it was reported in 32 of the 40 CT scans (80%) thereby giving a sensitivity of 91.6%, specificity of 37.5%, positive predictive value of 68.75%, negative predictive value of 75% and accuracy of 70% for HRCT in detecting cholesteatoma preoperatively. Low specificity (i.e. more false positive cases) of HRCT in detecting cholesteatoma may be due to the inability of HRCT to differentiate fluid and soft tissue mass based on the attenuation values and also due to the presence of ossicular erosions (mainly incus) in some of the cases of chronic mucosal disease.

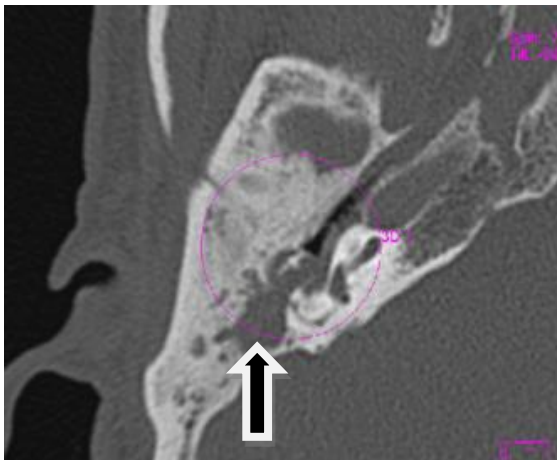
Similar findings were also noted in the study conducted by **Firas Q et al**<sup>(10)</sup> who found a sensitivity of 80% and specificity of 48% for HRCT in differentiating cholesteatoma from chronic mucosal disease. **Jackler et al**<sup>(11)</sup> found cholesteatoma to be present in 30% of cases where soft tissue mass along with bone erosion was present. In contrast, **Leighton et al**<sup>(12)</sup> reported that CT scan of temporal bone had an excellent predictive value for diagnosing cholesteatoma and in another study by **Gaurano and Joharjy**<sup>(13)</sup> reported that the correlation of pre-operative CT with surgical and histopathological findings was 97%. **N W C Chee & T Y Tan**<sup>(14)</sup> also showed that Cholesteatoma can be accurately diagnosed by the HRCT scan in the vast majority of cases. They considered tissue mass, typical location (epitympanum

and mastoid antrum) and bone erosion as the radiographic criteria for diagnosis of Cholesteatoma and showed that using at least 2 of the 3 features, cholesteatoma could be diagnosed in 94.4% of cases.

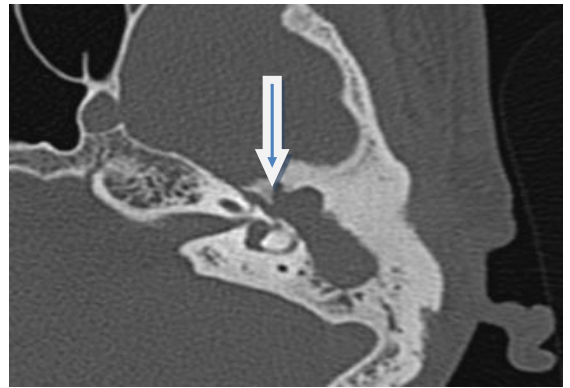
Among various parts of temporal bone assessed for bony erosions, Scutum (60%) (Fig. 3) was the most common structure to be involved followed by incus (50%) (Fig. 4). The other structures involved were stapes (42.5%), malleus (40%), facial canal (Fig. 5) (37.5%), tegmen (Fig. 6) (35%) and semicircular canals (17.5%). Mastoid cortex (12.5%) and sigmoid sinus plate (10%) were the least commonly involved sites.



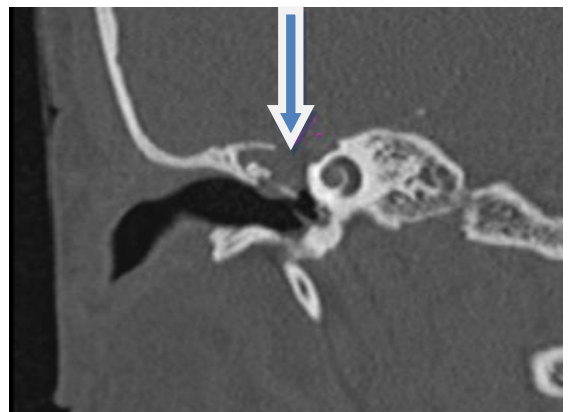**Fig. 3: Coronal image showing scutum erosion (black arrow) and nondependent soft tissue mass (blue arrow)**



**Fig. 4: Ossicular erosion: Axial image showing erosion of head of malleus and body of incus (black arrow)**



**Fig. 5: Facial canal erosion: Axial and coronal images depicting erosion of Tympanic part (blue arrow)**



**Fig. 6: Tegmen erosion: Coronal images showing tegmen erosion (Blue arrows)**

In our study, for the assessment of status of various middle and inner ear structures, radiosurgical correlation was excellent for erosions of Incus, Stapes, mastoid cortex, sigmoid plate and Scutum; Moderately good for erosions of malleus, semicircular canals and tegmen tympani; Poor for facial canal dehiscence.

Our study has shown that HRCT imaging has > 90% accuracy in depicting the status of the incus, stapes, Scutum, semicircular canals, sigmoid plate and mastoid cortex with low accuracy of 72.5% for the integrity of facial canal.

Our study shows high sensitivity for HRCT in detecting erosions of Incus (85%), Stapes (82.3%), Scutum (91.67%), sigmoid plate (100%) and mastoid cortex (100%) whereas sensitivity is low in depicting erosions of malleus (68.75%), Tegmen (32.6%) semicircular canal (71.4%) and facial canal (53.3%). Similar results were also noted in **Gerami et al**<sup>(15)</sup> study with high sensitivity for ossicular erosions and low sensitivity for tegmen, semicircular canal and facial canal erosions. HRCT showed 100% specificity for erosions of malleus, incus, scutum, sinus plate and mastoid cortex; whereas it is relatively less specific for erosions of facial canal (84%) and tegmen (81%).

## Conclusion

HRCT of temporal bone plays a promising role in pre-operative assessment of Cholesteatoma as it depicts the extent of the disease and integrity of most of the Middle ear structures. The scan alerts the surgeon to potential surgical dangers and complications of disease. A poor radiosurgical correlation was observed for differentiating cholesteatoma from chronic mucosal thickening as the underlying pathology in cases with CSOM. However, a good to excellent radiosurgical correlation is seen in CSOM for status of most middle and inner ear structures except for the integrity of the facial canal. This study has shown that HRCT imaging has > 90% accuracy in depicting the status of the incus, stapes, Scutum, semicircular canals, sigmoid plate and mastoid cortex with low accuracy of 72.5% for the integrity of facial canal. Despite limitations, the HRCT scan is a valuable and useful investigative tool prior to CSOM surgery.

## References

- Garber LZ and Dort JC. Cholesteatoma: Diagnosis and Staging by CT scan. *J Otolaryngol* 1994;22.
- O'Reithy BJ, Chevratton EB, Wylie I, Thakkar C, Butler P, Sathanathan N, Morrison G and Kenyon GS. The value of CT scanning in chronic suppurative otitis media. *The J Laryngol Otol* 2000;105:9903(2):121-124.
- Meyer TA, Strunker JR, Chester L, Lambert PR. Cholesteatoma. In: Bailey BJ, Johnson JT, editors. *Head and neck surgery otolaryngology*. 4th edition. Vol. 2. Philadelphia: Lippincott Williams and Wilkins; 2006. pp. 2081–91.
- Zeifer B. Radiology of the temporal bone. In: Thomas R, Staecker H, editors. *Otolaryngology, basic science and clinical review*. 1st edition. Thieme medical publishers; 2006. pp. 431–42.
- Mohammadi Gh, Naderpour M, Mousaviagdas M. Ossicular Erosion in Patients Requiring Surgery for Cholesteatoma. *Iranian Journal of Otorhinolaryngology*. 2012;24(68):125–8.
- Hassmann-Poznańska E, Gościk E, Oleński J, Skotnicka B. [Computerised tomography in pre-operative imaging of middle ear cholesteatoma] *Otolaryngol Pol*. 2003;57(2):243–9.
- Gaurano JL, Joharjy IA. Middle ear cholesteatoma: characteristic CT findings in 64 patients. *Ann Saudi Med*. 2004;24(6):442–7.
- O'Donoghue GM, Bates GJ, Anslow P, Rothera MP. The predictive value of high resolution computerized tomography in chronic suppurative ear disease. *Clin Otolaryngol Allied Sci*. 1987;12(2):89–96.
- Yu Z, Wang Z, Yang B, Han D, Zhang L. The value of preoperative CT scan of tympanic facial nerve canal in tympanomastoid surgery. *Acta Otolaryngol*. 2011 [Epub ahead of print].
- Alzoubi FQ, Odat HA, Al-balas HA, Saeed SR. The role of preoperative CT scan in patients with chronic otitis media. *Eur Arch Otorhinolaryngol* 2009;266:807–9.
- Jackler RK, Dillon WP, Schindler RA. Computed tomography in suppurative ear disease: A correlation of surgical and radiographic findings. *Laryngoscope* 1984;94:746-52.
- Leighton SE, Robson AK, Anslow P, Milford CA. The role of CT imaging in the management of chronic suppurative otitis media. *Clin Otolaryngol Allied Sci* 1993;18:23-9.
- Gaurano JL, Joharjy IA. Middle ear cholesteatoma: characteristic CT findings in 64 patients. *Ann Saudi Med* 2004;24:442-7.
- Chee NWC, Tan TY. The Value of Pre-operative High Resolution CT Scans in Cholesteatoma Surgery. *Singapore Med J* 2001;42(4):155-9.
- Gerami H, Naghavi E, Moghadam MW, Forghanparast K, Akbar MH. Comparison of preoperative computerised tomography scan imaging of temporal bone with the intra-operative findings in patients undergoing mastoidectomy. *Saudi Med J* 2009;30(1):104-8.