

## A rare case of anterior fontenelle antrochoanal polyp

Sunil Garg<sup>1,\*</sup>, Gyanesh Sethi<sup>2</sup>, Deepika Sethi<sup>3</sup>, Achal Gulati<sup>4</sup>

<sup>1</sup>Assistant Professor, <sup>2</sup>Senior Resident, <sup>3</sup>Specialist, <sup>4</sup>Director Professor & HOD, Dept. of Otorhinolaryngology, Baba Saheb Ambedkar Medical College & Hospital, Rohini, New Delhi

**\*Corresponding Author:**  
Email: dr.sunilgarg09@gmail.com

### Abstract

Antrochoanal polyps arise from the musosa of maxillary sinus and then extend into the nasal cavity and the choana. These are more common in children. It most commonly originates from the posterolateral wall of the maxillary antrum and passes into the middle meatus through the natural maxillary ostium or occasionally through an accessory maxillary ostium. Although there are many documented cases of polyps exiting the maxillary sinus through the accessory ostium, only three cases have been reported as exiting specifically through the anterior fontanelle. We are hereby presenting such a case antrochoanal polyp exiting through the anterior fontanelle which is very rare presentation of these polyps.

**Keywords:** Antrochoanal polyp, anterior fontenelle

### Introduction

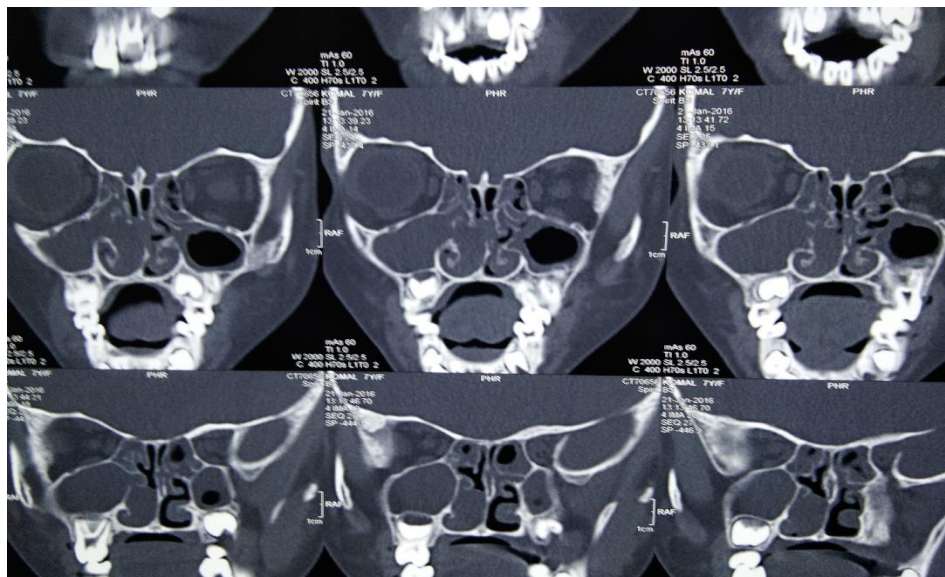
Antrochoanal polyps are benign lesions arising from the musosa of maxillary sinus extending into the nasal cavity and reaching the choana.<sup>(1)</sup> It forms 4-6% of all nasal polyps<sup>(2)</sup> and is much more common in children. It most commonly originates from the posterolateral wall of the maxillary antrum and passes into the middle meatus through the natural maxillary ostium or occasionally through an accessory maxillary ostium.<sup>(3)</sup> According to Stammberger, choanal polyps arise from inner maxillary ostium, posterior fontanelle and/or the maxilla ethmoidal angle of the maxillary sinus.<sup>(4)</sup> Nasal endoscopy and Non contrast CT scan (axial and coronal cuts) are the investigations of choice and the treatment is essentially surgical. Although there are many documented cases of polyps exiting the maxillary sinus through the accessory ostium, only three cases from the case series by Ramadan et al<sup>(5)</sup>

report polyps exiting specifically through the anterior fontanelle.

We are hereby presenting such a case antrochoanal polyp exiting through the anterior fontanelle which is very rare presentation of these polyps.

### Case Report

A 7-year-old girl presented to the ENT OPD of a tertiary care center with complaints of Right nasal obstruction and discharge for 9 months. On Anterior Rhinoscopy a greyish blue polypoidal mass was seen in the nasal cavity. NCCT PNS was done and soft tissue opacification was seen in the Right Maxillary sinus coming out through the right anterior fontanelle and right maxillary antrum (Fig. 1). Findings were confirmed by nasal endoscopy with the help of Hopkin Rod 0° 4mm rigid endoscope.



**Fig. 1:** CT Scan showing widening of anterior fontanelle in case of Antrochoanal polyp

The patient underwent Functional Endoscopic Sinus surgery under General Anesthesia After routine hematological investigations and Pre Anesthetic checkup. After debulking the polyp with a microdebrider, a wide middle meatal antrostomy was fashioned and polypoidal mucosa was removed from the maxillary antrum. Post operative period was uneventful and no recurrence has been seen after 20 months of follow up.

### Discussion

Antrochoanal polyps are benign lesions which are mostly unilateral however a few bilateral cases have been reported. AC polyps are believed to have two parts. The cystic part fills up the maxillary antrum and the solid part.<sup>(6)</sup> Obstruction of acinar mucus glands causes retention cyst formation due to allergy or infective etiology. Medial part of antral cyst blocks the accessory maxillary ostium completely and the natural maxillary ostium partially. Trapped air and increased pressure causes the cyst to herniate through the natural maxillary ostium.<sup>(7)</sup> However a controversy exists regarding the exit of polyp from maxillary antrum. Stamberger had observed that polyps usually rise from the inner maxillary ostium, posterior fontanelle or maxillo-ethmoidal angle.<sup>(4)</sup> The polyp in our case was observed to coming out of the anterior fontanelle along with the natural maxillary ostium and on search of available English literature only three such cases have been reported.<sup>(5)</sup>

Treatment of antrochoanal polyp is essentially surgical. Simple polypectomy causes frequent recurrence and Caldwell-Lucas causes infraorbital anesthesia, cheek swelling and has a long recovery time.<sup>(6)</sup> Hence endoscopic sinus surgery is the current treatment of choice. A combined endoscopic and transcanine approach may be used in patients where incomplete clearance of diseased mucosa from the antrum is expected. Our patient underwent endoscopic sinus surgery and the natural maxillary ostium was widened anteriorly to create a wide middle meatal antrostomy. Pre-operatively it was easier to clear the diseased mucosa from the maxillary antrum and transcaninesinoscopy was not required. Thus we would like to suggest that polyps exiting the maxillary antrum through the anterior fontanelle provide an opportunity of better surgical clearance and lower chances of recurrence.

### Declaration of the conflicting interests

The authors declared no potential conflicts of interest with respect to and/or publication of the article.

### Funding

Authors received no financial support for the research, authorship and/or publication of the article.

### Ethical Approval

Consent was taken from parents of the children for surgery and publication of the case report.

### References

1. Choudhury N, Hariri A, Saleh H (2015) Endoscopic management of antrochoanal polyps: a single UK centre's experience. *Eur Arch Oto-Rhino-Laryngology* 272:2305–2311. doi: 10.1007/s00405-014-3163-7.
2. Heck WE, Hallberg OE, Williams HL (1950) Antrochoanal polyp. *AMA Arch Otolaryngol* 52:538–48.
3. Pruna X, Ibañez JM, Serres X, et al (2000) Antrochoanal polyps in children: CT findings and differential diagnosis. *Eur Radiol* 10:849–851. doi: 10.1007/s003300051017.
4. Stamberger H (1986) Nasal and Paranasal Sinus Endoscopy A Diagnostic and Surgical Approach to Recurrent Sinusitis. *Endoscopy* 18:213–218. doi: 10.1055/s-2007-1018382.
5. Hashem Sayed R, Rashad UM (2003) Atypical presentations of antrochoanal polyps. *Int Congr Ser* 1240:569–577. doi: 10.1016/S0531-5131(03)00779-9.
6. Özdek A, Samim E, Bayiz Ü, et al (2002) Antrochoanal polyps in children. *Int J Pediatr Otorhinolaryngol* 65:213–218. doi: 10.1016/S0165-5876(02)00153-2.
7. Balıkcı HH, Özkul MH, Uvacin O, et al (2013) Antrochoanal polyposis: Analysis of 34 cases. *Eur Arch Oto-Rhino-Laryngology* 270:1651–1654. doi: 10.1007/s00405-012-2274-2.