

A morphometric study of jugular foramen in adult dried human skull of South Karnataka population

Shashanka M J¹, Swaroop N^{2,*}, Vishal Kumar³, Jagadish⁴

^{1,2}Assistant Professor, ³Professor and HOD, Dept. of Anatomy, ⁴Statistician, Dept. of Community Medicine, Kodagu Institute of Medical Sciences, Madikeri, Karnataka, India

***Corresponding Author:**

Email: swaroopa.n12@gmail.com

Abstract

Introduction: The jugular foramen (JF) is larger irregular curved foramen situated in the skull base which transmits major neurovascular structures especially internal jugular vein. Variations in JF are more common in the same or different crania, races and sexes. The knowledge of detailed anatomy is therefore necessary to conduct microsurgeries in and around these foramina.

Material and Methods: The present study was conducted on 40 adult dried human skulls having 80 jugular foramen procured from Department of Anatomy at Kodagu Institute of Medical Sciences, Madikeri. We have observed and metric measurements of the anteroposterior and mediolateral diameter of jugular foramen, width and depth of the jugular fossa were taken by using digital vernier callipers and the data were tabulated, analysed and compared.

Results: The dimensions of JF and Jugular fossa were larger on right side. Out of 40 skulls, bilateral complete septations were found in 6 (15%) skulls and bilateral partial septations were found in 4 (10%) skulls. Two septations on left side were observed in only one skull. The mean±SD of width and depth of jugular fossa were 7.61±1.95 mm and 8.63±2.58 mm on left and 9.18±1.65 mm and 10.39±3.33 mm on right side respectively. A dome indicating the prominent superior jugular bulb were found in 69 (86.25%) jugular fossa, of which 29 (72.5%) were bilateral.

Conclusion: The variations could be due to constitutional, racial or genetic factors. Thus the present study is important for the surgeons in dealing with space occupying lesions in and around the foramen.

Keywords: Skull, Jugular foramen.

Introduction

Jugular foramen (JF) is bilateral large irregular opening in the base of the skull, with long axis directed forwards and medially. The anterior boundary is formed by jugular fossa of petrous temporal and posterior boundary being jugular notch of the occipital bone. The foramen is divided into 3 parts i.e., anterior, intermediate and posterior, with anterior part giving passage to inferior petrosal sinus, intermediate part mainly conveying glosso-pharyngeal, vagus and accessory nerves and posterior part transmitting internal jugular vein.¹

During radical neck dissection, internal jugular vein being a dominant vein of the region, is often ligated which can lead to the risk of venous infarction. JF is affected in the following syndromes which can occur due to the Glomus tumors, Meningiomas, Schwannomas, Metastatic tumors located at the cerebellopontine angle, Trauma, Infections and other bone diseases involving middle ear and JF. Jugular foramen syndrome or Vernet's syndrome is characterised by the paralysis of the 9th, 10th and 11th cranial nerves. Villaret's syndrome involves the above nerves, along with paralysis of the 12th cranial nerve, occurs due to retropharyngeal lesion invading the posterior cranial fossa. Jackson syndrome involves paralysis of vagus, accessory and hypoglossal nerves due to premature closure of sutures of skull. Schmidt syndrome involves vagus and accessory nerve paralysis. Tapia syndrome involves vagus and

hypoglossal palsy occurs as a complication of general anaesthesia.²

Treatment of choice for most of the above mentioned conditions is surgical resection. Nowadays with the advancement of microsurgical techniques, the removal of advanced Jugular foramen lesions is possible. With the detailed anatomical knowledge of this region, the neurosurgeons are becoming bolder enough to operate in and around this region. So the present study is done to provide morphometric details of JF which further helps neurosurgeons for their successful surgeries.³

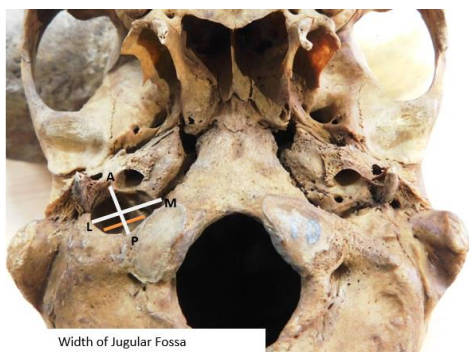
Material and Methods

The present study was conducted on 40 adult dried human skulls having 80 JF procured from Department of Anatomy, at Kodagu Institute of Medical Sciences, Madikeri. The deformed, damaged skulls, skulls of paediatric age were excluded from the study. The following parameters were observed and measured using digital vernier callipers with 0.1 mm precision. (Fig. 1).

- Anteroposterior (AP) diameter of JF: Maximum Anteroposterior diameter of JF.
- Mediolateral (ML) diameter of JF: Distance between medial most and lateral most points of JF.
- Presence or absence of septations – if present noted the number.
- Width of jugular fossa: Maximum width of jugular fossa.

- e. Presence or absence of dome in jugular fossa was noted
- f. Depth of the jugular fossa: dome if present then the distance is measured between summit of the dome and the inferior border of jugular fossa.

The results were tabulated and compared on both the sides; the results were analysed using Unpaired T test with SPSS version 20. Our results were compared with previous studies.



AP: Anterioposterior Diameter of JF
ML: Medirolateral Diameter of JF

Fig. 1: Showing the measurements of JF

Results

Out of 40 skulls having 80 JF studied, the following observations were noticed.

Anterioposterior diameter of JF: On left side JF range and mean±SD was 4.8 mm to 10.4 mm and 7.45±1.34 mm respectively. On the right side JF range and mean±SD was 6.2 mm to 11.4 mm and 9.2±1.34 mm respectively. AP diameter showing less than 5mm were found in 1 (1.25 %) of JF, 5 to 10mm were found in 66 (82.5%) of JF and more than 10 mm were found in 13 (16.25%) of JF.

Medirolateral diameter of JF: On left side JF range and mean±SD was 8 mm to 17.2 mm and 13.2±2.28 mm respectively. On the right side JF range and mean±SD was 9.4 mm to 20 mm and 14.42±2.71 mm respectively. AP diameter showing less than 12mm were found in 21 (26.25 %) of JF, 12 to 17mm were

found in 48 (60%) of JF and more than 17 mm were found in 11 (13.75%) of JF.

Septations of JF: Out of 40 skulls, bilateral septations (complete/ partial) in JF were found in 13 (32.5%) skulls, bilateral complete septations were found in 6 (15%) skulls and bilateral partial septations were found in 4 (10%) skulls. Out of 80 JF, septations were observed in 30 (37.5%) out of which 15 were found having partial septas and 15 were found having complete septations. Only one skull showed two septations in JF on left side. The right side JF showed 16 (40%) septations, of which 10 (25%) were partial, 6 (15%) were having complete septations. The left side JF showed 14 (35%) septations of which 5 (12.5%) were partial, 9 (22.5%) were having complete septations.

Width of jugular fossa: The range and mean±SD of width of jugular fossa on left side, was 0 mm to 10.6 mm and 7.61±1.95 mm respectively. The range and mean±SD of width of jugular fossa on right side, was 5.4 mm to 13 mm and 9.18±1.65 mm respectively. Width of jugular fossa showing less than 5mm were found in 6 (7.5 %) of JF, 5 to 10mm were found in 56 (70%) of JF and more than 10 mm were found in 18 (22.5%) of JF.

Dome of Jugular fossa: Out of 80 JF a dome indicating the prominent superior jugular bulb were found in 69 (86.25%) jugular fossa, of which 29 (72.5%) were bilateral. The right side showed 38 (52.17%) and on the left side showed 31 (47.83%) domes.

Depth of the jugular fossa: The range and mean±SD of depth of jugular fossa on left side, was 0 mm to 15.1 mm and 8.63±2.58 mm respectively. The range and mean±SD of depth of jugular fossa on right side, was 1.9 mm to 15.3 mm and 10.39±3.33 mm respectively. Depth of jugular fossa showing less than 5mm were found in 8 (10 %) of JF, 5 to 15mm were found in 69 (86.25%) of JF and more than 15 mm were found in 3 (3.75%) of JF.

All the above mentioned measurements were larger on right side than left side, which showed a statistically significant p value < 0.01 (Table 1)

Table 1: Dimensions of Jugular foramen and Jugular Fossa

Parameters	Right side		Left side		p value
	Range	Mean ± SD	Range	Mean ± SD	
AP. Dia - JF (mm)	6.2 - 11.4	9.2 ± 1.34	4.8 - 10.4	7.45 ± 1.34	0.0001
ML. Dia - JF (mm)	9.4 - 20	14.42 ± 2.71	8 - 17.2	13.2 ± 2.28	0.0316
Width- Jugular fossa(mm)	5.4 - 13	9.18 ± 1.65	0 - 10.6	7.61 ± 1.95	0.0002
Depth- Jugular fossa(mm)	1.9 - 15.3	10.39 ± 3.33	0 - 15.1	8.63 ± 2.58	0.0056

Discussion

The structures that traverses the JF are the sigmoid sinus, jugular bulb, inferior petrosal sinus, meningeal branches of the ascending pharyngeal and occipital arteries, the 9th – 11th cranial nerves with their ganglia,

the tympanic branch of the glossopharyngeal nerve, the auricular branch of the vagus and the cochlear aqueduct. The difficulties in exposing this canal are created by its deep location and the surrounding vital structures, such as the carotid artery anteriorly, the

hypoglossal nerve medially, the facial nerve laterally and the vertebral artery inferiorly. All these important structures require careful dissection during access to this canal.²

The size and shape of the jugular foramen is related to the size of the internal jugular vein and the presence or absence of a prominent superior bulb. The right foramen is usually larger than the left. There is a very wide variation in the anatomy of the intra cranial venous sinuses which accounts for variation in size and shape of jugular foramen. The difference in size of the two internal jugular veins is already visible in the human embryo at the 23mm stage and probably results

from differences in the pattern of development of the right and left brachiocephalic veins.⁴

The present study is similar with the study conducted by Anjali Singla et al⁵ in having higher AP and ML diameters of JF on right side than left and was statistically significant ($p < 0.01$). The studies conducted by Roma Patel³, Ekinci and Unur,⁶ Shruthi BN⁴ and Hussain Saheb⁷ reported lesser and study done by Idowu² showed higher AP and ML diameters of JF than the present study. There was no statistical significance on right and left side of JF in studies conducted by Pereira GAM⁸ and Idowu² and had reported high ML diameter of JF on left side than right which is reversed in the present study. (Table 2)

Table 2: Comparison of Dimensions of Anteroposterior (AP) diameter and Mediolateral Diameter with Previous studies

Sl No.	Authors	Year of Study	AP dia		ML dia	
			Right	left	Right	left
1	Ekinci and Unur ⁶	1997	8.4 mm	7.6 mm	16 mm	15.5 mm
2	Idowu ²	2004	10.22 mm	9.57 mm	13.90 mm	14.11 mm
3	Hussain Saheb et al ⁷	2010	7.83 mm	6.83 mm	23.62 mm	22.86 mm
4	Pereira, GAM ⁸	2010	9.21 mm	8.65 mm	15.82 mm	15.86 mm
5	Anjali singla et al ⁵	2012	9.32 mm	7.34 mm	15.67 mm	14.85 mm
6	Roma Patel and C.D.Mehta ³	2014	7.9 mm	6.2 mm	12.17 mm	11 mm
7	Shruthi B.N et al ⁴	2015	7.51 mm	7.16 mm	24.48 mm	21.24 mm
8	Present study	2018	9.2 mm	7.45 mm	14.42 mm	13.2 mm

The present study differs a lot from the study conducted by other authors in terms of percentage of partial and complete septations of JF on right and left side (Table 3). Bilateral complete septations were found in 6 (15%) skulls and bilateral partial septations were found in 4 (10%) skulls. Partial septations were more on right JF than left JF in our study which were similar to the studies done by Roma Patel³ and Shifan Khandey.⁹ Complete septation were more on left JF than right JF which had not been reported in studies conducted by other authors. Regarding the morphogenesis of foramina anomalies at the base of the skull, three major fenestrations were observed in

early human foetal skull – foramen lacerum anterior-hiatus between greater and lesser wing of sphenoid; foramen lacerum medius-opening between basisphenoid and periodic capsule; foramen lacerum posterior-hiatus between basiocciput and auditory bullae. These large fenestrations become subdivided by the ingrowth of bony spicules, leading to the formation of multiple foramina. Foramen lacerum posterior persists as JF. Variations in the septations of JF are attributed to variability in bone formation around primitive foramen lacerum posterior, indicating the ongoing evolutionary process.⁵

Table 3: Comparison of septations with previous studies

Sl No.	Authors	Complete septations		Partial septation	
		Right	left	Right	left
1	Hatiboglu and Anil ¹¹	5.6%	4.3%	2.6%	19.6%
2	Sturrock R.R ¹⁰	3.2%	3.2%	1.3%	10.9%
3	Patel and Singel ¹²	23.1%	17.6%	19.5%	59.3%
4	Hussain Saheb et al ⁷	20.8%	16.8%	45.6%	58.4%
5	Shifan Khanday et al ⁹	13%	4%	24%	7%
6	Roma Patel and C.D.Mehta ³	16%	14%	29%	25%
7	Present study	15%	22.5%	25%	12.5%

The percentage of dome on left side were more on right than left JF in the present study, which were similar with the studies conducted by other authors compared and we also found maximum number of bilateral dome (72.5%) which had not been reported so far in the previous studies. (Table 4).

Table 4: Comparison of Dome of Jugular foramen with previous studies

Sl	Authors	Presence of dome bilateral	Presence of dome on right side	Presence of dome on left side	Absence of dome
1	Sturrock R.R ¹⁰	53.9%	30.1%	6.4%	9.6%
2	Hatiboglu and Anil ¹¹	49%	36.1%	4.6%	10.3%
3	Patel and Singel ¹²	21%	38.5%	14.3%	25.2%
4	Anjali singla et al ⁵	66%	6%	16%	12%
5	Present study	72.5%	11.25%	2.5%	13.75%

The average width and depth of jugular fossa in the present study was found to be 9.18 mm and 10.39 mm on right and 7.61 mm and 8.63 mm on left respectively. Anjali singla et al⁵ reported in their study that the average width and depth of jugular fossa as 8.99 mm and 11.11 mm on right and 7.54 mm and 11.04 mm on left jugular fossa respectively. The width of jugular fossa in the present study was almost similar to the study compared, but the depth of jugular fossa showed significant difference in having high right sided measurements in the present study. The variation in the dimensions of jugular fossa may be related to high jugular bulb causing conductive hearing loss because of its contact with tympanic membrane causing interference with ossicular chain and finally resulting in the obstruction of round window niche. The high jugular bulb may also cause complications during cochlear implantation due to its encroachment to middle ear space and due to its intimate relation with the internal acoustic meatus needs utmost cautious approach while performing surgeries for vestibular schwannomas.⁵

Conclusion

The present study observed the variation in the size of JF. The foramen are larger on the right than the left in south Karnataka population. These variations in the size, shapes and compartments of jugular foramen might be a part of the ongoing evolutionary process, also involving racial and genetic factors. Detailed anatomical knowledge of morphology, compartments and morphometry is necessary for neurosurgeons and ENT surgeons to have a bolder approach in dealing with space occupying lesions in and around the jugular foramen.

Funding: No funding sources.

Conflict of interest: None declared.

Acknowledgements

Our sincere thanks to the Dean, Head and Faculty of Department of Anatomy, Kodagu Institute of Medical Sciences, Madikeri, for their valuable suggestion, help, support and permission to conduct the

study on adult human dried skull of the institution. Also we are thankful for the first MBBS students of 2017-18 batch for rendering the skulls needed for study purpose.

References

1. AK Dutta .Essentials of Human Anatomy Part II 5th edition, Current Books International 2009;57.
2. Idowu OE. The jugular foramen—A morphometric study. *Folia Morphol* 2004;63:419–22.
3. Roma Patel, C.D. Mehta. Morphometric study of Jugular Foramen at base of the skull in South Gujarat region. *IOSR J Dent Med Sci* 2014;9:58-61.
4. Shruithi B.N , Pavan P. Havaladar , Shaik Hussain Saheb , Henjarappa K S . Morphometric Study of Jugular Foramen. *Int J Integrative Med Sci* 2015;2(10):164-66.
5. Anjali Singla, Daisy Sahni, Anjali Aggarwal, Tulika Gupta, Harjeet Kaur. Morphometric Study of the Jugular Foramen in Northwest Indian Population. *J Postgraduate Med Educ Res* 2012;46(4):165-71.
7. Ekinci N., Unur E. Macroscopic and morphometric investigation of the jugular foramen of the human skull. *J Anat* 1997;72:525–29.
8. Hussain Saheb S , Mavishetter G F, Thomas S T, Prasanna L C, Muralidhar P. A Morphometric study of the jugular foramen in human adult skulls of south India. *J Biomed Sci and Res* 2010;2(4):240-43.
9. Pereira GAM, Lopes PTC, Santos AMPV, Krebs WD. Morphometric aspects of the jugular foramen in dry skulls of adult individuals in Southern Brazil. *J Morphol Sci* 2010;27:3-5.
10. Shifan Khanday, Ramesh Kumar Subramanian, Melani Rajendran, Ashfaq Ul Hassan, Sajad Hamid Khan. Morphological and morphometric study of jugular Foramen in south Indian population. *Int J Anat Res* 2013;1(3):122-27.
11. Sturrock RR, Variations in the structure of the jugular foramen of the human skull. *J Anat* 1998;160:227-30.
12. Hatilboglu MT, Anil A. Structural variations in the jugular foramen of the skulls. *J Anat* 1992;180:191-96.
13. Patel MM, Singel TC. Variations in the structure of jugular foramen of the human skull in Saurashtra Region. *J Anat Soc India* 2007;56 (2):34-37.

How to cite the article: J Shashanka, N. Swaroop, Vishal Kumar V., Jagadish. A morphometric study of jugular foramen in adult dried human skull of South Karnataka population. *Indian J Anat Surg Head Neck Brain* 2018;4(3):82-85.