

Study of gender determination in living adult male and female subjects by evaluating the size of sternum about north Indian population

S V Sharma^{1,*}, Virendra Atam², Navneet Kumar³, Nilesh Sharma⁴, Isha Atam⁵, H. B. Sharma⁶

¹Resident, ^{2,3}Professor and Head, ⁴Laboratory Assistant, ⁵Medical Officer, ^{1,3}Dept. of Anatomy, ^{2,4,5}Dept. of Medicine, King George's Medical University, Lucknow, Uttar Pradesh, India

***Corresponding Author: S V Sharma**

Email: sv_sharmakgmu@rediffmail.com

Abstract

Introduction: The gender determination from the skeletal remains is of very much interest in the field of medical science. Ashley GT - 1956b formulated the 149 rule according to which a male sternum exceeded 149mm in length whereas the female sternum was less than 149mm. on the basis of previous researcher I have been planned to verify the external data and establish them in reference to population in and around Lucknow. With the help of this study we were distinguishes the male and female sternum bone in north zone of India as well as Uttar Pradesh.

Materials and Methods: The above mentioned measurements have been further use to calculate various sternal dimensions and indices according to the technique described by Ashley. Each linear measurement has been taken thrice on the anatomical position of the sternum using Mitutoyo-digital vernier calipers to the nearest millimeter with precision of 0.01 mm.

Discussion: This study was fully supported the previous researchers, who has done the work in morphometry of sternum bone in cadaver and skeletal of human, because they told that the sterna has distinguish in different zone of India, as well as it is shorter than European country.

Conclusion: The comparison of mean length of manubrium, mesosternum and sternum ranged from 40.39-71.31 mm, 83.49-129.97 mm and 150.21-170.39 mm respectively in adult male (16-60yrs) where as in adult female ranged from 23.79-60.35 mm, 68.33-122.42 mm and 116.36-148.92 mm respectively.

Keywords: Sternum bone, Gender determination, Length of manubrium, Length of mesosternum.

Introduction

Sex determination of unidentified skeletal remains very in forensic or archeological situations, is one of the prime tasks of experts like forensic anthropologists and bioarcheologists involved in such examinations.¹ In case of mass-disasters such as armed conflicts, terrorist massacres, aeroplane crashes, war related crimes etc., when badly decomposed, mutilated or damaged human remains consisting of only a few bones or their fragments are recovered from the site, it becomes crucial to establish the biological identity, especially the sex of a missing individual² Though, a number of bones such as pelvis, skull femur etc.,^{3,4} have contributed significantly to this endeavor, these sex-specific or sex indicative bones are not always found at such scenes. In such situations, forensic anthropologists and bioarcheologists have to depend on less sexually dimorphic elements of human skeleton such as sternum.^{5,6}

Ashley GT -1956b formulated the 149 rule according to which a male sternum exceeded 149mm in length whereas the female sternum was less than 149mm. This rule was applicable to 77.6% males and 80.4% females for European sterna.¹¹

The gender determination from the skeletal remains is of very much interest in the field of medical science and law. The bones are more resistant to the putrefaction process that makes it important to study, which in turn helps identify the gender determination criteria. Next to pelvis, human skull is regarded as the most accurate indicator of the sex⁷ but when these bones are missing; recent findings have

suggested that sternum and manubrium can act as valuable specimens.^{8,4}

In India, various researchers have presented their work on the sternum regarding sex determination.⁹ This study has been planned to verify the existrnal data and establish them in reference to population in and around Lucknow. Since the study was conducted in the people of Lucknow, and subjects were selected only from in and around the Lucknow as the race and built may affect the dimensions of the sternum. With the help of this study we were distinguishes the male and female sternum bone in north zone of India as well as Uttar Pradesh.

Materials and Methods

This study has been conducted on the total 100 subjects, 50 female (16-60yrs) and 50 male (16-60yrs) of healthy people (Living adult subjects) from general population of north India as well as in and around the department of anatomy at King George's Medical University U P Lucknow. After obtaining ethical clearance and informed consent form, the living subjects have been recruited from the healthy staff members of OPD, department of medicine, pediatrics and Obs & gynecology at King George's Medical University U P Lucknow. All the living subjects have been well informed about the nature of study. To prevent discrimination, living subjects have recruited for our study fulfilling inclusion criteria (male and female, age 16 to 60 years, BMI less than 25 and no history of chronic disease, at least 1 years tenure, no use of medication other than analgesics during the month preceding data collection). The living subjects have been explained the procedure of study.

For the morphometry of the sternum, following measurements have been taken in to consideration

Length of Manubrium: It has been measured from the centre of suprasternal notch to the centre of the manubrio-sternal junction in mid sagittal plane.

Length of Mesosternum: It has been measured from the centre of manubrio-sternal junction to the centre of sterno-xiphoid junction in the mid sagittal plane.

Total Length of Sternum: It has been measured from the centre of jugular notch to xiphoid process in the mid sagittal plane.

The above mentioned measurements have been further use to calculate various sternal dimensions and indices according to the technique described by Ashley. Each linear measurement has been taken thrice on the anatomical position of the sternum using Mitutoyo-digital vernier calipers to the nearest millimeter with precision of 0.01 mm, according to definitions presented in and their average was recorded.¹⁰

Result

Basic Characteristics: The present study deals with sex determination through measurement of human sternum in Lucknow city of Uttar Pradesh (U.P.). The primary outcome measures of the study were length of manubrium, length of mesosternum and length of sternum measured in millimeter (mm). Besides that actual age (yrs), height (cm), weight

(kg), chest circumference (cm), waist circumference and hip circumference (cm) were also noted.

I. Male 16-60yrs: The basic characteristics of 16-60yrs males are summarized in Table 1. The mean length of manubrium, mesosternum and sternum ranged from 40.39-71.31 mm, 83.49-129.97 mm and 150.21-170.39 mm respectively with mean 58.97 ± 6.68 mm, 103.74 ± 8.42 mm and 162.70 ± 5.70 mm respectively and median 59.16 mm, 104.29 mm and 163.52 mm respectively.

II. Female 16-60yrs: The basic characteristics of 16-60yrs females are summarized in Table 2. The mean length of manubrium, mesosternum and sternum ranged from 23.79-60.35 mm, 68.33-122.42 mm and 116.36-148.92 mm respectively with mean 48.38 ± 5.71 mm, 89.55 ± 10.81 mm and 137.93 ± 8.70 mm respectively and median 48.77 mm, 90.11 mm and 139.47 mm respectively.

Comparison between Female vs. Male- 16-60yrs: The comparison of mean length of manubrium, mesosternum and sternum between 16 to 60yrs female and male is summarized in Table 3 and also depicted in Fig. 4 to 6 respectively. Comparing the mean length of manubrium, mesosternum and sternum between two groups, Student's t test showed significantly different and higher length of manubrium (18.0%) (48.38 ± 5.71 vs. 58.97 ± 6.68 , $t=8.52$, $p<0.001$), mesosternum (13.7%) (89.55 ± 10.81 vs. 103.74 ± 8.42 , $t=8.98$, $p<0.001$) and sternum (15.2%) (137.93 ± 8.70 vs. 162.70 ± 5.70 , $t=16.84$, $p<0.001$) in males as compared to females.

Table 1: Basic characteristics of 16-60yrs males

Variable	N	Min	Max	Mean	SD	SE	Median
Age (yrs)	50	17.00	60.00	39.58	12.40	1.75	39.00
Height (cm)	50	157.28	189.34	167.47	6.62	0.94	165.43
Weight (cm)	50	40.58	95.72	63.94	10.11	1.43	63.48
BMI (kg/m ²)	50	15.60	28.80	22.77	3.06	0.43	22.57
Chest circumference (cm)	50	76.49	114.46	90.77	8.57	1.21	90.15
Waist circumference (cm)	50	68.29	120.28	87.08	11.23	1.59	86.98
Hip circumference (cm)	50	80.37	113.01	92.88	7.31	1.03	93.21
Length of manubrium (mm)	50	40.39	71.31	58.97	6.68	0.95	59.16
Length of mesosternum (mm)	50	83.49	129.97	103.74	8.42	1.19	104.29
Length of sternum (mm)	50	150.21	170.39	162.70	5.70	0.81	163.52

Table 2: Basic characteristics of 16-60yrs females

Variable	N	Min	Max	Mean	SD	SE	Median
Age (yrs)	50	17.00	55.00	35.70	8.32	1.18	36.50
Height (cm)	50	142.39	165.49	154.24	5.72	0.81	154.56
Weight (cm)	50	35.46	85.19	61.46	10.63	1.50	62.54
BMI (kg/m ²)	50	14.96	32.20	25.81	4.11	0.58	26.14
Chest circumference (cm)	50	75.29	116.16	96.21	9.03	1.28	96.83
Waist circumference (cm)	50	58.18	118.28	96.16	12.59	1.78	98.36
Hip circumference (cm)	50	80.19	117.87	100.89	8.41	1.19	100.41
Length of manubrium (mm)	50	23.79	60.35	48.38	5.71	0.81	48.77
Length of mesosternum (mm)	50	68.33	122.42	89.55	10.81	1.53	90.11
Length of sternum (mm)	50	116.36	148.92	137.93	8.70	1.23	139.47

Table 3: Comparison of length of manubrium, mesosternum and sternum (Mean ± SD, n=50) between 16 to 60yrs female and male

Variable	Female	Male	t value	p value
Length of manubrium (mm)	48.38 ± 5.71	58.97 ± 6.68	8.52	<0.001
Length of mesosternum (mm)	89.55 ± 10.81	103.74 ± 8.42	7.32	<0.001
Length of sternum (mm)	137.93 ± 8.70	162.70 ± 5.70	16.84	<0.001

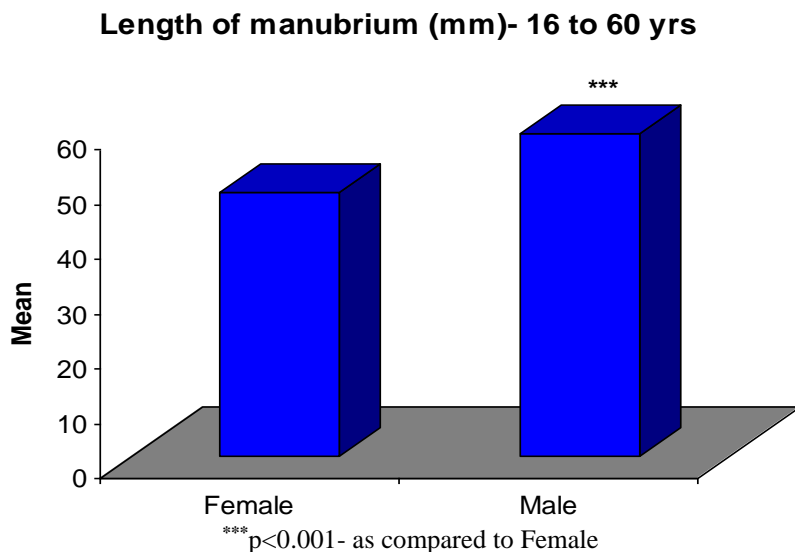


Fig. 4: Comparison of length of manubrium between 16 to 60yrs females and males

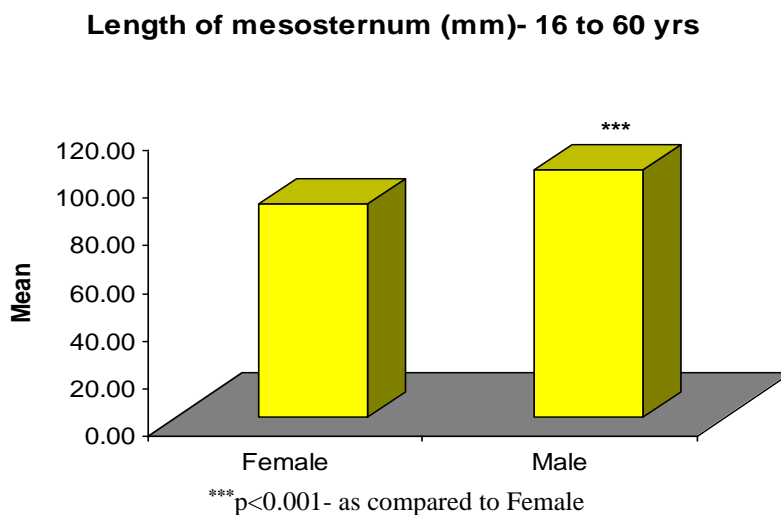
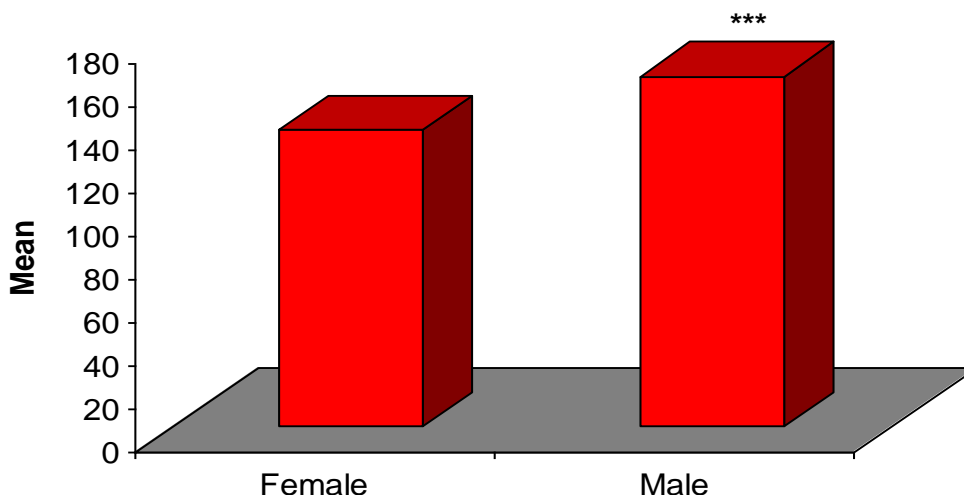


Fig. 5: Comparison of length of mesosternum between 16 to 60yrs females and males

Length of sternum (mm)- 16 to 16 yrs



***p<0.001- as compared to Female

Fig. 6: Comparison of length of sternum between 16 to 60yrs females and males.

Discussion

The aim of the present study was to evaluate the Sex determination through measurement of human sternum in Lucknow city of Uttar Pradesh, India. Results from our study revealed that body weight, BMI, and abdominal circumference were in normal range. The findings suggest that osteometric evaluation of the sternum can be an effective method for identification of sex in the Lucknow population as well as Uttar Pradesh.

Comparison between Female vs. Male- 16-60yrs: The comparison of mean length of manubrium, mesosternum and sternum between 16 to 60yrs female and male is Comparing the mean length of manubrium, mesosternum and sternum between two groups, Student's t test showed significantly different and higher length of manubrium (18.0%) (48.38 ± 5.71 vs. 58.97 ± 6.68 , $t=8.52$, $p<0.001$), mesosternum (13.7%) (89.55 ± 10.81 vs. 103.74 ± 8.42 , $t=8.98$, $p<0.001$) and sternum (15.2%) (137.93 ± 8.70 vs. 162.70 ± 5.70 , $t=16.84$, $p<0.001$) in males as compared to females.

According to observation and result in my present study it was fully supported the previous researchers, who has done the work in morphometry of sternum bone in cadaver and skeletal of human, because they told that the sterna has distinguishing in different zone of India, as well as it is shorter than European country.

On the basis of above observation and result we can discuss that¹ [Ashley GT -1956b] got 52.2 mm for males and 47.9 mm for females.¹¹ obtained 51.73 mm for males and 48.42 mm for females, which agreed with our findings of 58.97 mm for males and 48.38 mm for females. From the parameters used in this study, the length of the manubrium distinguishes 18.0% males is longer than females. This observation indicates that the difference between the average length of the male and female manubrium is 8.52

mm, which is statistically significant ($P<0.001$) with the length of the male manubrium being longer than that of the female. In the human sternum, which is a highly sexually dimorphic bone, only the mesosternum length of the sternum was seen to be highly useful in distinguishing a male from a female sternum.

According to 149 rules,¹² the male length of mesosternum was 101.3 mm and 79.9 mm for females respectively. His findings were supported by¹³ and¹⁴

Conclusion

The basic characteristics of 16-60yrs in males and female like age, height, weight, chest circumference, waist circumference and hip circumference and BMI was in normal range respectively. The comparison of mean length of manubrium, mesosternum and sternum ranged from 40.39-71.31 mm, 83.49-129.97 mm and 150.21-170.39 mm respectively in adult male (16-60yrs) where as in adult female ranged from 23.79-60.35 mm, 68.33-122.42 mm and 116.36-148.92 mm respectively.

This study concluded that the male sternum is longer than female sternum. This conclusion will provide the help to distinguish factors for medico-legal studies where examination of human skeleton is obviously of greatest importance for identification purposes.

Thus the present results in my study was provide full support, study done by Ashley GT-1956b formulated the 149 rule, according to which a male sternum exceeded 149mm in length whereas the female sternum was less than 149mm.

Statistical Analysis

Data were summarized as Mean \pm SD (standard deviation), range (min to max) and median. Groups were compared by independent Student's t test. Pearson

correlation was done to assess association between variables. A two-tailed ($\alpha=2$) $p<0.05$ was considered statistically significant. Analyses were performed on SPSS software (windows version 21.0). The statistical analysis has been done by Dr. M.P. Negi, from Central Drug Research Institute (CDRI) Lucknow.

Acknowledgement

The authors are grateful to all subjects who participated in this study. I would like to thank Dr. M.P. Negi, Statistician in Central Drugs Research Institute (CDRI), Lucknow for his Statistical analysis and cooperation, and I would like to give specially Thanks Dr. Navneet Kumar, Professor & Head, department of Anatomy, King George's Medical University, U.P., Lucknow for developing this hypothesis, cooperation, and conducting this research work.

Conflict of Interest: None.

References

1. Ashley GT. A comparison of human and anthropoid mesosterna. *Am J Phys Anthropol* 1956;14(3):449-461.
2. Mc Cormick WF, Stewart JH, Langford LA. Sex determination from chest plate roentgenograms. *Am J Phys Anthropol* 1985;68:173-195.
3. Selthofer R, Nicolic V, Mrcela T, Radic R, Leksan I, Rudez I, Selthofer K. Morphometric analysis of the sternum. *Coll Antropol* 2006;30:43-47.
4. Osunwoke EA, Gwunireama IU, Orish CN, Ordu KS, Ebowe I. A study of sexual dimorphism of the human sternum in the southern Nigerian population. *J Appl Biosci* 2010;26:1636-1639.
5. Ramadan M, Turkmen N, Dolgan NA, Gokharman D, Menezes M, Kacar M, Kosar U. Sex determination from measurements of the sternum and fourth rib using multislice computed tomography of the chest. *Forensic Sci Int* 2010;197:120.e1-5.
6. Macaluso PJ. The efficacy of sternal measurements for sex determination in South African blacks. *Forensic Sci Int* 2010;202:111e.111e.7.
7. Macaluso PJ, Lucena J. Estimation of sex from sternal dimensions derived from chest plate radiographs in contemporary Spaniards. *Int J Legal Med* 2014;128(2):389-395.
8. Dwight T. The sternum as an index of sex and age. *J Anat* 1881;15:327-330.
9. Singh J, Pathak RK, Singh D. Morphometric sex determination from various sternal widths of Northwest Indian sternums collected from autopsy bones: *Egypt J Forensic Sci* 2002;2(1):18-28.
10. Bass WM. Human Osteology: A Laboratory and Field Manual of the Human Skeleton (3rd Ed.). *Missouri Archaeological Society Special Publications, Columbia, Missouri*. 1987: p. 112
11. Jit I. Bakshi, Time of fusion of the human mesosternum with manubrium and xiphoid process. *Indian J Med Res* 1986;82:322-327.
12. Ashley GT, The human sternum - the influence of sex and age on its measurement. *J Forensic Med* 1956b;3:27-43.
13. Camps FE. Editor Gradwohl's legal medicine. 3rd ed. Bristol. *John Wright & sons Ltd*; 1976. p. 110.
14. Bass WM. Human Osteology: A Laboratory and Field Manual of the Human Skeleton (3rd Ed.). *Missouri Archaeological Society Special Publications, Columbia, Missouri*. 1987: p. 112.

How to cite this article: Sharma SV, Atam V, Kumar N, Sharma N, Atam I, Sharma HB. Study of gender determination in living adult male and female subjects by evaluating the size of sternum about north Indian population. *Indian J Anat Surg Head Neck Brain* 2018;4(4):118-122.